ANATOMICAL OBSERVATIONS ON THE LOWER BRAIN STEM OF THE RIGHT WHALE

YASUSHI SEKI*

ABSTRACT

The lower brain stem of the right whale (*Eubalaena glacialis* Bonnaterre) was observed anatomically. Macroscopical findings were noted briefly, followed by the microscopical investigations and comments.

Nerve roots and their central nuclei of the cranial nerves were observed seemingly nothing particular in their positions and sizes, except sensory trigeminal nuclei. The most conspicuous finding was the extreme largeness of the sensory trigeminal structures in this whale, in this connection the sensory apparatuses on the head portion were discussed.

The inferior olivary nuclei, the nuclei of the posterior funiculi and the medical lemniscus were found in usual positions and sizes.

Pyramidal tract was specific in that making a wedge shaped unpaired tract at the lower medulla, and then changed in spindle shape in the depth of the anterior median fissure at the lowest medulla.

INTRODUCTION, MATERIAL AND METHODS

As far as we are able to know, very few studies have been done covering anatomical field of the central nervous system of the right whale, much more so regarding the microscopical observations. This fact must be related, at least in part, to the severe prohibition of whaling on to this whale.

In 1956, two right whales were captured in the coastal waters to Japan, with the special permission of the Japanese Government for the scientific investigations. These two whales were examined their external as well as internal characters by the staff of the Whales Research Institute, Tokyo, and the results were reported by Nishiwaki (1957) and Omura (1958). In one of these whales, Ayukawa specimen, which was young female and 38 feet 4 inches in body length, the brain and the spinal cord were removed two days after the capture by the staff of the Medical School, University of Tokyo, and fixed in formalin. Results of the anatomical observations on the spinal cord were reported previously by the present author (1958). Unfortunately, because chiefly of the prolonged post-mortem time, the deep parts of the cerebral hemispheres and cerebellum seemed not very well fixed by the for-

---

*Department of Anatomy, Kanazawa Medical University, Ishikawa 920-02, Japan

malin, accordingly only the brain stem lower than the midbrain was separated from other parts of the brain and proceeded to make the microscopical preparates at the Brain Research Institute, University of Tokyo. The material was cut in to three blocks (anterior, middle and posterior)* and refixed in the Müller's solution at 37°C for three weeks and mounted in celloidin through the usual manner. Serial sections of 45 μm (anterior block) and 40 μm (middle and posterior blocks) in thickness, along the transverse plane, were made. Each fifth sections (with the last order of each figure being 0 and 5 or 1 and 6 etc.) were treated by the Weigert-Pal carmine or Kultschitzky's method for myelin staining. In this study, much efforts were made to obtain more precise findings on the internal structure of the brain stem, and many of remaining sections, which had been stored in the brain Research Institute, University of Tokyo, were stained by the Klüver-Barrera's method or the P-T method according to needs.

RESULTS AND COMMENTS

FEATURES OF THE BRAIN AS A WHOLE

Size of the brain (Figs 1 and 2) measured was ca. 200 mm in antero-posterior direction, ca. 196 mm in width and ca. 125 mm in height and the brain weight was 2640 g. The brain as a whole and the cerebral hemisphere appeared fore-shortened and widened transversely, though the height was not so prominent compared with the length. Pilleri (1964) reported the brain weighed 2750 g in a case of southern right whale of 43 feet in body length. He also measured as 205 mm in total length, 180 mm in width and 140 mm in height of the brain. According to Omura *et al.* (1969), brain weight ranges from 2.4 to 3.1 kg or from 0.0038 to 0.0050 of the body weight after investigation in 4 cases of black right whale caught in the Bering Sea during 1962 to 1963 season. Referring previous observations, the low brain weight seems conspicuous in this whale among the various species of big whales (Kojima, 1951; Breathnach, 1960; Morgane *et al.*, 1972 usw.).

The cerebral hemisphere was large and moderately convoluted, with the convolutions on the lateral surface arranged in upside-down U form along an almost vertical lateral sulcus of Sylvius. The large temporal lobe was prominent on the ventral aspect of the brain and contrasted to the occipital lobe which was not delimited distinctly. The olfactory bulb and tract were observed entirely absent in each side, but the lobule désert of Broca was recognized clearly as a transverse rising at the posterior aspect of the orbital gyri. In the Pilleri's report (1964), on the other hand, the olfactory trigone and stump of the trimmed olfactory tract are clearly visible on both sides in his Abb. 4 and 5. In general, the olfactory bulb and tract are extremely regressed in the ceta-

---

* *A, M and P, preceding the serial section number of Figures, mean these blocks respectively. Serial section numbers were put on from caudal end to rostral one in each blocks. (Refer to Explanation of Figures).*

Fig.1

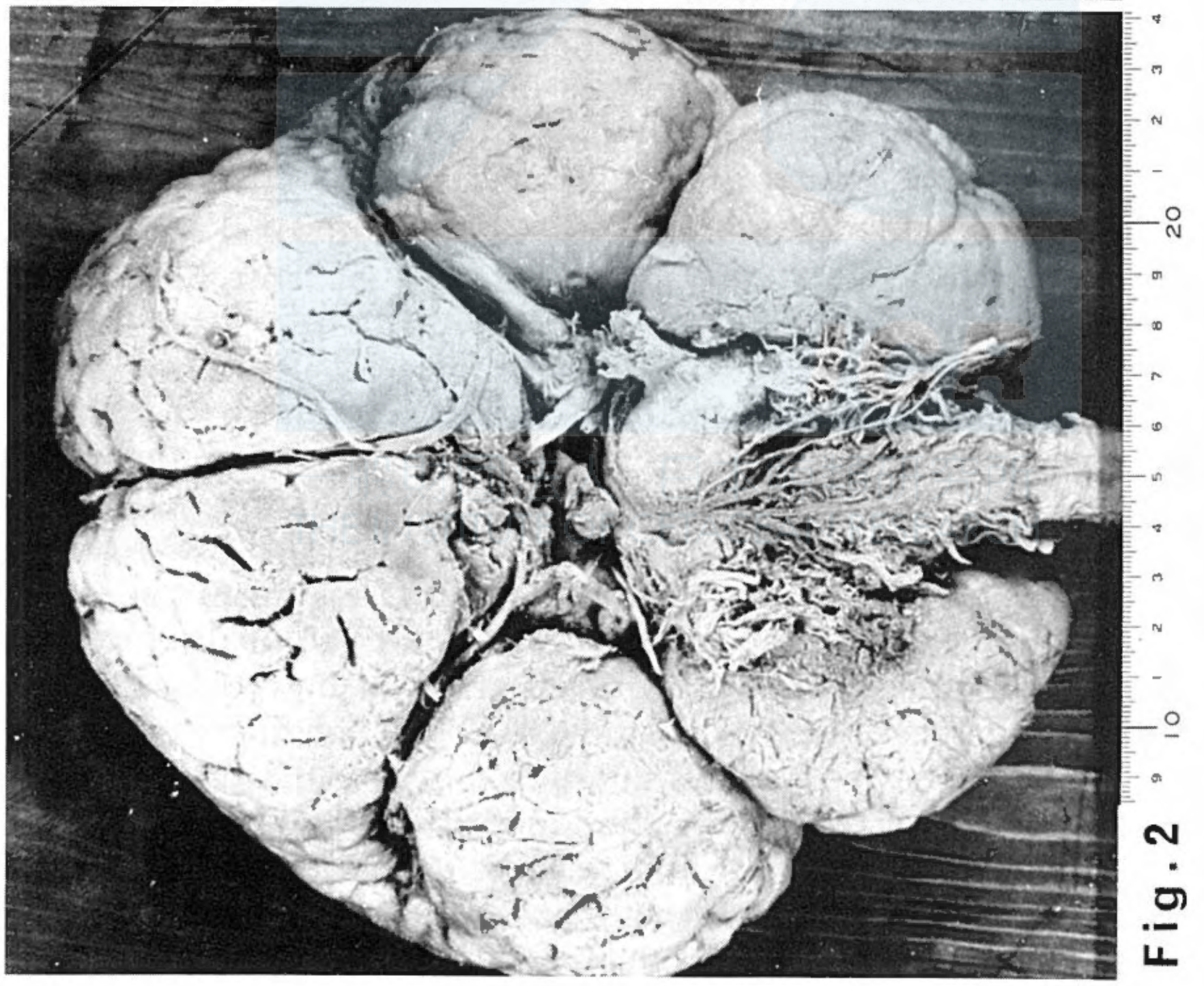

Fig.2

Figs 1 and 2. The dorsal (Fig. 1) and ventral (Fig. 2) views of the brain. Refer to text for details (Features of the brain as a whole).

cean brain, and especially in some Odontoceti, entirely absent of them had been reported (Langworthy, 1932; Ries and Langworthy, 1937; Kojima, 1951 etc.). In some Mysticeti, presence of the olfactory bulb or tract was reported including fetal specimen (Guldberg, 1885; Riese, 1928, 1936; Langworthy, 1935; Friant, 1957, etc.).

The cerebral peduncle and the large pons were short and wide. The inferior colliculus was protruded strikingly to the dorsal direction and exceeded than the superior colliculus in size. The flat and not so distinct eminence on the ventral surface of the medulla oblongata was made by the medullary pyramid and inside the eminence, on the cross sections, large olivary nucleus i.e. the medial nucleus of the inferior olive could be seen. Extremely large fifth nerve root on both sides proceeded towards the frontal direction from the lateral border of the pontine eminence. The eighth nerve was fairly big, though destroyed a little. According to the descriptions of previous investigators, generally the fifth nerve is the largest of all the cranial nerves in the whalebone whales, while the eighth nerve is the largest one in the toothed whales (Langworthy, 1932; Wilson, 1933; Breathnach, 1960 etc.).

The cerebellum was very large and consisted of narrow vermis and large hemispheres. Pilleri (1964) measured the weight of the cerebellum of the southern right whale and it was 600 g and corresponded to 22% of the total brain weight.

THE THIRD, FOURTH AND SIXTH CRANIAL NERVES

The motor nerve roots of the oculomotor, trochlear and abducens nerves are observed in ordinary position and size in appearance. The caudal end of the oculomotor nucleus is recognized as a single cell mass being surrounded its ventral side by the medial longitudinal fascicle (Figs 18 and 19) and some of the root fibers seemingly originating from these cells are visible at just ventral to the nucleus (Fig. 18). Unfortunately the major part of the oculomotor nucleus escaped from the material in both sides. Wilson (1933) noted that the nucleus of the third cranial nerve in the *Balaenoptera sulfurea* (*B. musculus*) consisted of two clusters of cells; the lateral nucleus lying in the medial longitudinal fascicle and the medial nucleus occupying the space between the raphe and the fascicle. Langworthy (1932) described the third nerve nucleus in the *Tursiops truncatus* as compact and composed of single cell mass.

The trochlear nucleus is found at a little caudal level, some distance apart from the oculomotor nucleus, as a single cell group being enclosed in the medial longitudinal fascicle (Figs 17 L and 20). The root fibers originating from the nucleus are traceable towards the dorsolateral and caudal direction, along the periphery of the central gray substance of the midbrain, and reaching to the crossing of the nerve root at the caudalmost level of the midbrain.

The abducens nerve roots are observed at the uppermost medullary level and passing through the lateral part of the medial lemniscus which is locating at the medial aspect to the superior olive (Figs 12L and 22). The abducens nucleus is recognized as fairly dispersed cell collection locating at the ventral aspect to the internal genu and just below the emerging bundle of the facial nerve root (Fig. 22). Wilson (1933) distinguished no definite abducens nucleus in the *Balaenoptera*; the only suggestion of it was a few scattered large motor type polygonal cells lying just ventral to the descending facial nerve root.

THE XIITH CRANIAL NERVE

Reduced development of the hypoglossal nucleus in the cetacea has generally been accepted, and this fact is commonly explained in relation with the lesser development of muscularization and motility of the tongue, especially so in the Mysticeti (Langworthy, 1932; Breathnach, 1960 etc.).

In the medulla oblongata of the right whale, on the other hand, there observed no suggestion of such regression of the hypoglossal nerve root and its origin nucleus; moderately large collection of big polygonal cells and many fiber bundles of the nerve root are recognized at usual position (Figs 5 - 8 and 27). Four cell groups can be divided in the main hypoglossal nucleus; dorsomedial, ventromedial, ventrolateral and dorsolateral, though each cell groups are observed continuing each other in some levels (Figs 7 and 27). The dorsomedial group is seen in strong development at the levels approximately lower two thirds of the entire length of the main nucleus and reduces its size gradually at the upper levels. The ventromedial group shows clear tendency to fuse with the dorsomedial one at the lower levels, and to separates from that and then fuses with the ventrolateral group at the upper levels. The dorsolateral group is observed in good development at the levels upper two thirds of the main nucleus.

Roller's nucleus consisting of smaller cells is distinguished on each side at the ventral aspect to the ventromedial cell group of the main nucleus (Fig. 27), except the uppermost and lowermost levels of it. The intercalatus nucleus consisting of very small cells is found at the lateral aspect of the dorsolateral group at the levels upper half of the main nucleus (Figs 8 and 9), increasing its size as the dorsolateral cell group diminishes towards the upper levels, and finally the nucleus changes with no abrupt transition into a prepositus nucleus at the uppermost medullar level. The interfascicular and the eminentiae teretis nuclei are unable to identify in the right whale.

THE VTH NERVE

The trigeminal nerve root is observed extremely large, the minor portion of it being located rostro-medial to the major portion. The nuclei of the trigeminal nerve are very well developed, except the mesencephalic nucleus which is seen as just ordinary size and position (Figs 16 L, 17 and 20).

The poor development of the posterior horn of the spinal cord in the cetacea had previously been described by many authors (Guldberg, 1885; Hatschek, 1896; Sano, 1909 usw.) and the situation is also the same in the right whale (Seki, 1958). At the first cervical level, however, the posterior horn is fairly big, as nearly the same size as the anterior horn at the same level. More rostrally, spinal tract and its nucleus of the trigeminal nerve are found of quite large size in the medulla oblongata (Figs 3 - 11). The rate of the dimension of the spinal trigeminal complex exists almost 30% of the cross sectional area at the lower medulla. Incidentally, the rate shows approximately 20% in the Sei whale (*Balaenoptera borealis*) and about 8% in the human at the same level. In the levels upper than the rostral medulla, the spinal trigeminal complex diminishes its size slightly but the rate of the dimension to the cross sectional area shows approximately 15% at the uppermost level of the medulla. Considering increase of the dimension of the surrounding structures in this level, this percent of the rate is thought to be still fairly big, while the rate is about 8% in the Sei whale and 4.5% in the human at the corresponding level. At levels upper than the middle of the inferior olive, the spinal trigeminal complex decreases gradually its nuclear mass and contrally increases fiber amount of the tract (Figs 9 - 12). At the level of the caudal limit of the superior olive, the principal nucleus and fiber mass surrounding it appear at the dorsal aspect of the spinal trigeminal complex. The principal trigeminal area expands its dimension rapidly towards the upper levels and makes its maximum extent at the level of the motor trigeminal nucleus, showing almost as nearly the same size as the motor trigeminal nucleus at the same level (Figs 12 - 14). Transition of the spinal trigeminal complex to the principal trigeminal nucleus seems not clear and the spinal tract can be traced upwards to the level of the motor trigeminal nucleus. Upper part of the principal trigeminal nucleus lies at the ventromedial aspect to the superior cerebellar peduncle and decreases suddenly its size at the uppermost pontine level.

Olszewski (1950) divided the spinal trigeminal nucleus into three portions in man and monkey in oral, interpolar and caudal. According to his criteria, these three portions are hardly divisible in the spinal trigeminal complex in the right whale because of lesser development of the gelatious substance in the caudal levels and difficulty of looking for large cells similar to those of the external cuneate nucleus in the middle levels of it. Marginal and intrafascicular cell groups of the spinal trigeminal tract, corresponding to the gray substances described by Fuse (1940) in *Delphinus delphis* and *Balaenoptera borealis,* are fairly well developed also at the upper medulla in the right whale.

Rather small sensory trigeminal nuclei had been reported by Langworthy (1932) in *Tursiops truncatus* and Jelgersma (1934) in *Phocaena communis.* Checking illustrations of studies of Hatschek and Schlesinger (1902) in *Delphinus delphis* and Hosokawa *et al.* (1969) in *Stenella coeruleoalba,* rather small sensory trigeminal nuclei could be assumed as in nearly the same extent as those of the figures of former two author's works. Referring these and other more works (Rawitz, 1909, *Phocaena communis;* Mc Farland *et al.*, 1969 and Morgane *et al.*, 1972, *Tursiops truncatus* usw.), it is highly probable that in these small Odontoceti have relatively less developed sensory trigeminal structures than those of the right whale.

Breathnach (1960) pointed out the importance of the tactile sensibility in the snout and oral regions in the cetacea in view of the poor development or absence of the olfactory sense, the alleged poverty of vision and lack of a sense of taste. Nakai and Shida (1948) described scanty but regularly arranged sinus hairs on the upper and lower lips of the Sei whale (*Balaenoptera borealis*). They thought that the hairs encounter pressure and resistance and emphasized the importance of these hairs not merely as a tactile organ in searching for tiny foods but more probably as the organ to feel the stream of water upon the head. While Ogawa and Shida (1950) noted widespread occurrence of sensory tubercles richly supplied with nerve fibers on the lips and oral cavity of Sei whale (*Balaenoptera borealis*) and Fin whale (*Balaenoptera physalus*) and concluded that they certainly represent highly sensitive tactile organs. These two authors confirmed also the existence of structures, which seem to be sensitive apparatuses having rich nerve endings in the lips, tongue, palate and basis of the mouth cavity of the right whale (Seki, 1958).

On the other hand, in Odontoceti, sinus hairs, though appears in the fetal period, are absent in the adult, and none of the description has been known on the sensory tubercles in the areas of trigeminal innervation. Attention must be paid on the fact that in these Odontoceti having rather small sensory trigeminal nuclei, perhaps without exception, conspicuously large hearing structures can be seen in their nervous system.

Reffering these previous findings and present investigation, there exist probably the whale species which are highly dependent upon the trigeminal sensitivity in their everyday life, like a typical case in the right whale, while other species are much more dependent on the hearing ability than the trigeminal sense, like such instances in *Tursiops* and *Stenella* etc. Further investigations must be needed for solution of problems on the sensory apparatuses of the head portion, including the bonnet and callosities of the right whale, and correlations to the sensory trigeminal structures in the brain of the cetacea.

The motor trigeminal nucleus is quite large mass situating at the lateral part of the pontine reticular formation and consists of big polygonal cells. It seems three cell groups could be indentified in the motor trigeminal nucleus; caudal, ventromedial and lateral. All of these cell groups can be observed at the level of the upper part of the facial nucleus. The caudal cell group is seen just above the facial nucleus (Fig. 12 R), while the dorsal subnucleus of the facial nucleus is separated caudally by a little distance from it. The caudal cell group diminishes its size at the level of the rostral end of the facial nucleus. The lateral cell group develops gradually towards the levels upper than the facial nucleus, and makes quite large cell mass at the upper pontine level. The ventromedial cell group is seen at the ventromedial aspect to the lateral cell group and diminishes its size at the upper pontine level.

THE VIIth NERVE

Facial nerve root and internal genu make a moderately thick bundle. The main facial nucleus is large enough and situating at the bottom of the reticular formation at the transitional level of the medulla and the pons. Differentiation of cells into groups is remarkable only in the dorsal subnucleus which is located at the dorsal aspect to the main facial nucleus with some distance from it and just medial to the outgoing facial nerve root (Fig. 22). The nerve cell collection of the main facial nucleus seems not so differentiated, in particular its ventral part is found as a large simple cell mass, while the dorsal part looks divided in some but indefinite groups.

On the other hand, Hatschek and Schlesinger 1902, in *Delphinus delphis;* Wilson, 1933, in *Balaenoptera sulfurea;* Jelgersma, 1934, in *Phocaena communis,* De Graaf, 1967, in *Balaenoptera physalus, Balaenoptera acutorostrata, Hyperoodon ampullatus* and *Orcinus orca,* described well marked cell groups in the facial nucleus.

Though the opinion, that there is a lack of sense of taste and questionable existence of the salivary glands in the cetacea, has been commonly accepted, Yamada (1953) described and illustrated the chorda tympani nerve in *Globicephalus* and *Balaenoptera,* and recently Yamasaki *et al*. (1978) reported taste buds in the tongue of the *Stenella coeruleoalba.* In this connection, none of noteworthy finding could be obtained in this investigation.

THE IXth, Xth AND XIth NERVES

The glossopharyngeal nerve is observed rather small and its root fibers pass through inbetween the inferior cerebellar peduncle and the spinal trigeminal tract at the uppermost medulla and seems to connect chiefly with the rostral part of the solitary tract, which is small in this level (Figs 9 R and 10 L). At the medial aspect to the spinal trigeminal complex of the medulla oblongata, except the lower levels of it, a series of nerve rootlet, seemingly concerned as the vagus nerve, is seen. The accessory nerve root is observed fairly well developed in the lower medulla though its spinal root is found only in the first cervical level.

The dorsal motor nucleus is seen from the emerging level of the glossopharyngeal nerve to the lower medulla in good development and consists of large group of medium sized polygonal cells (Fig. 27). The solitary tract is moderately big in the upper half of the medullary level (Figs 7 and 8) and reduce its size slowly to the lower levels. The nucleus ambiguus is seen clearly but not so big throughout the medulla, in particular it is less developed in levels lower than the obex (Figs 5 - 10). Hosokawa (1950) noticed the conspicuously big nucleus ambiguus in Sei whale (*Balaenoptera borealis*) in connection with the muscular laryngeal sac of this whale. Small size of the spinal root of the accessory nerve was noted by some authors (Hepburn and Waterston, 1904, in *phocaena;* Ries and Langworthy, 1937, in *physeter;* Jansen, 1953, in *Balaenoptera physalus,* Breathnach, 1955, in *Megaptera novaeangliae;* Seki, 1958, in *Eubalaena glacialis* etc.) against Hatschek's description (1896, in *Delphinus delphis*) that was observable as "Respirationsbündel" of Krause until the level of the cervical enlargement.

THE VIIITH NERVE

The acoustic system in the cetacean brain had been mentioned by many previous investigators (Spitzka, 1886; Hatschek and Schlesinger, 1902; Hofmann, 1908; Valeton, 1908; Langworthy, 1932; Ogawa and Arifuku, 1948 usw.) in view of its exstremely high stage of development than that of the other common mammals.

Cochlear nucleus in the right whale, a little protruded to the ventral surface of the brain stem at the transitional level of the pons and the medulla, seems big but not so surprising size and situates outside the inferior cerebellar peduncle (Figs 10 and 11). Dorsal nucleus or the so called tuberculum acusticum is not clearly identified as mentioned by Ogawa and Arifuku (1948). Stria acustica of Monakow starts from dorsal part of the cochlear nucleus and passing through the dorsal periphery of the Deiters's nucleus towards the medical side up to the dorsolateral part of the reticular formation (Figs 9 - 11), though farther course is not traceable. In the right whale, the Held's tract is seen clearly as somewhat dispersed thin bundles, starting from the dorsomedial part of the cochlear nucleus and proceeds to dorsal and then to medial along the dorsal periphery of the inferior cerebellar peduncle, and farther penetrates the dorsal part of the spinal trigeminal complex and the facial nucleus (Fig. 11 L), afterwards it can not be followed up. The trapezoid body is quite well developed at the ventral part of the brain stem from the uppermost medulla to the lower pontine level. The superior olivary nucleus seems not so big, composed of two parts; medial and lateral, the lateral part being smaller in size than that of the medial part, and located dorsal to the trapezoid body and medial to the facial nucleus (Fig. 12). In the territory inbetween the medial lemniscus and the medial part of the superior olivary nucleus, disseminated cell mass can be seen, which is considered as the nucleus of the trapezoid body. Preolivary nucleus of Cajal is difficult to identify. A great deal of fibers accumulated chiefly at the ventral side of the superior olivary nuclei represents the lateral lemniscus, as it goes upper levels, reaching finally to the ventral side of the inferior colliculus (Figs 13 - 17). The lateral lemniscus contains a disinct nuclear mass in it, the nucleus of the lateral lemnisus (Figs 14 - 16). The inferior colliculus is very large and protruded to the dorsal direction, and receives the lateral lemniscus in its ventral side. Brachium of the inferior colliculus is scarsely seen at the lateral border of the inferior colliculus as it is destroyed superficially (Figs 16 L and 17 L).

The vestibular nuclei are found rather small, except the Deiters's nucleus, which occupies fairly large territory of the dorsolateral part of the uppermost medullary level (Figs 11 and 23). Hatschek and Schlesinger, 1902, in *Delphinus delphis,* and Wilson, 1933, in *Balaenoptera sulfurea,* obtained the similar results as mentioned above.

THE INFERIOR OLIVE

The cetacean inferior olive had been studied and described by many authors (Hatschek and Schlesinger, 1902; Rawitz, 1909; Kankeleit, 1913; Kooy, 1917; Brunner, 1919; Kooy, 1920; Langworthy, 1932; Wilson, 1933; Jelgersma, 1934 usw.), and characteristics of the cetacean inferior olivary nucleus are the extraordinarily big size of the rostral part of the medial accessory nucleus and lesser development of the dorsal accessory and principal nuclei.

In the right whale, the oral part of the medial accessory olivary nucleus is developed in a quite large size and triangle in shape, locating closely to the midline of the upper half level of the medulla, while the dorsal accessory olivary and the principal olivary nuclei are observed in far less developed and not clearly delimited from the surrounding structures (Figs 7 - 10 and 25). Beside this, though there existed some different opinions among previous investigators as to the homology on the caudal part of the medial accessory nucleus, which is found in moderately size upwards from the level of the obex to the middle medullary levels in the right whale (Figs 6, 7 and 26).

POSTERIOR FUNICULUS AND MEDIAL LEMNISCUS

In the right whale, the posterior funiculus is not so large, missing the posterior median septum to make a small Bischoff's nucleus on the midline at the lowest medulla (Fig. 4). Wilson (1933) mentioned poor development of the gracile and cuneate nuclei in *Balaenoptera sulfurea* and presumed the median triangular nucleus to be identical with the Bischoff's nucleus. At the levels below the obex, fused Goll's nuclei of the both sides can be seen because of the disappearance of the posterior median septum and fibers running beside it (Fig. 5). In levels upper than the obex, border of the Goll's and Burdach's nuclei becomes not clear, and Monakow's external cuneate nucleus appears in the lateral part of the posterior funiculus (Fig. 27).

The medial lemniscus is found in levels upper than the obex, surrounding the inferior olivary nuclei in lower levels and locating dorsal to the pyramidal tract in upper medullary and pontine levels. In the midbrain, the medial lemniscus of both sides lies beneath the superior cerebellar peduncle and moves gradually to the lateral direction (Fig. 17).

CRUS CEREBRI AND PYRAMIDAL TRACT

In the brain stem of the cetacea, pyramidal tract and associated fiber tracts had been mentioned by many authors. Hatschek and Schlesinger (1902) pointed out the small size of the pyramid at medullary levels in *Delphinus delphis.* Langworthy (1932) distinguished a temporopontine tract in the lateral part of the cerebral peduncle and identified the medial part of it as the corticospinal and frontopontine fibers in *Tursiops truncatus,* while Kojima (1951) in *physeter catodon,* noted two different parts in the cerebral peduncle according to the fiber direction.

In the right whale, the cerebral peduncle is made of considerable amount of fibers though upper part of it being out from the matrial. The big amount of these fibers diminishes very much during its course passing through the pontine nucleus, and reaches to the bulbar pyramid which is the flat assembly of bundles of thin fibers locating ventral to the inferior olivary nucleus (Figs 8 - 12). At the pontine level, the pontine longitudinal fasciculi including the corticospinal fibers, are observed lying near the tegmentum and showing transversely flat oval in shape, and closely approaching each other on both sides of the raphe (Figs 14 and 15).

As previously described by Seki (1958), in the lower medulla, pyramid on both sides comes to fuse together and changes gradually into a wedge shaped unpaired bundle between the anterior funiculi on both sides (Figs 4 - 6). More caudalward, the pyramid, decreasing its amount of fibers, changes into a spindle shaped tract and shifts its location slowly to the depth of the anterior median fissure (Fig. 3). The pyramidal tract fibers are not traceable below the second cervical level. Pyramidal decussation can not be confirmed as the most fibers of the tract are traced in longitudinal course and it is quite hard to ascertain the crossing is really exitsts or not. Rawitz (1909) and Gans (1916) in *phocaena,* Matsumoto (1953) in *Kogia breviceps* and *Berardius bairdii,* described the pyramidal decussation, but some authors could not confirm it (Hatschek and Schlesinger, 1902, in *Delphinus delphis;* Wilson, 1933, in *Balaenoptera sulfurea;* Jelgersma, 1934, in *phocaena communis* usw.).

SUMMARY

Anatomical observations on the lower brain stem of the right whale summarised as follows, accompanied brief note on the superficial findings of the brain as a whole.

Relatively low weight of the brain is thought to be conspicuous among that of the other big whales. Complete lack of the olfactory bulb and tract were noted. The trigeminal nerve root was observed as the largest in all of the cranial nerves.

Nerve roots and their central structures of the cranial nerves were noted and discussed briefly. Nerves and nuclei of the extraocular muscles were

found as nothing particular. None of regressive finding was obtained on the hypoglossal nerve and its nucleus. The extreme largeness of the sensory trigeminal nuclei was noticed and discussed in relation to the sensory apparatuses on the head portion of the Mysticeti. The motor trigeminal nucleus was observed as quite large size and differentiated into three cell groups. The facial nerve was moderately thick and its nucleus were large enough but differentiation into cell groups was remarkable only in the dorsal subnucleus. The glossopharyngeal, vagal and accessory nerves and related nuclei were observed in usual position and size. Acoustic nerve and related nuclei were found in considerable development though they were exceeded by the sensory trigeminal structures in size. Monkow's stria acustica and Held's tract were seen clearly. Among the vestibular nuclei, the Deiters's nucleus only was strongly developed.

Oral part of the medial accessory nucleus of the inferior olivary nuclei was conspicuously developed as commonly seen in other cetacea. Bischoff's nucleus was found on the midline at the lowest medulla. Goll's and Burdach's nuclei were seen in lesser development. Fused Goll's nucleus of both sides was observed at the level below the obex.

Pyramidal tract was specific in that making wedge shaped unpaired bundle between the anterior funiculi on both sides at the lower medulla. This tract proceeded farther caudalwards into the spindle shape and moved into the depth of the anterior median fissure, decreasing its fiber amount to disappearance at the second cervical level.

ACKNOWLEDGEMENT

The author is very sad that Dr Teizo Ogawa, formerly professor of Department of Anatomy and director of the Brain Research Institute, University of Tokyo, deceased at April 29, 1984. Sincerely gratitude is due to him for his constant direction and kind advices throughout this study. The author is very sorry that the completion of this work has become so much delayed that missed his revision, and no more. The author would like forgiveness for offering this poor study to the memory of the late professor, Dr T. Ogawa.

REFERENCES

Breathnach, A.S., 1955. The surface features of the brain of the humpback whale (*Megaptera novaeangliae*). *J. Anat. (Lond.)*, 89: 343–354.

Breathnach, A.S., 1960. The cetacean central nervous system. *Biol. Rev. Cambridge Phil. Soc.*, 35: 187–230.

Brunner, H., 1919. Bemerkungen zum Aufbau des Hirnstammes der Cetaceen mit besondere Berücksichtigung der unteren Olive. *J. Psychol. Neur. (Lpz.)*, 24: 138–165.

De Graaf, A.S., 1967. Anatomical Aspects of the Cetacean Brain Stem. Van Gorcum, Assen, 169 pp.

Friant, M., 1957. Un cerveau de foetus de Rorqual (*Balaenoplera musculus L.*). *C.R. Acad. Sci., Paris*, 244: 236–238 (Cited from Breathnach, 1960).

Fuse, G., 1940. Einiges vergleichend anatomisches über ein bisher nicht genügend dargestelltes bzw.

gewürdigtes Grausystem in und an der spinale Quintuswurzel (Nuclei intra et extratrigeminales) bei einigen Wassersäugetieren (Seehund, Seebär, Seeotter, Delphin und Seiwal). *Arb. Anat. Inst. Sendai.*, 23: 165–223.

Gans, A., 1916. Die Pyramidenbahn der *phocaena. Anat. Anz.*, 49: 281–284.

Guldberg, G.A., 1885, Ueber das Centralnervensystem der Bartenwale. Christiania, Vid. Selsk. Forhdl. No. 4. 154 pp.

Hatschek, R., 1896. Ueber des Rückenmark des Delphins *(Delphinus delphis). Arb. Inst. Anat. Physiol. Z.N.S. Wien.* 4: 286–312.

Hatschek, R. und H. Schlesinger, 1902. Der Hirnstamm des Delphins *(Delphinus delphis). Arb. Neur. Inst. Wien. Univ.*, 9: 1–117.

Hepburn, D. and D. Waterston, 1904. A comparative study of the grey and white matter, of the motor cell groups, and of the spinal accessory nerve, in the spinal cord of the Porpoise *(Phocaena communis). J. Anat.*, 38: 105–118 and 295–311.

Hofmann, F., 1908. Die obere Olive der Säugetiere nebst Bemerkungen über die Lage der Cochlearisendkerne. *Arb. Neur. Inst. Wien. Univ.*, 14: 76–328.

Hosokawa, H., 1950. On the cetacean larynx, with special remarks on the laryngeal sack of the Sei whale and the aryteno-epiglottideal tube of the Sperm whale. *Sci. Rep. Whales Res. Inst.*, 3: 23–62.

Hosokawa, H., S. Igarashi, T. Kamiya and K. Hirosawa, 1969. Morphological characteristics and myelinization of acoustic system in the dolphins *(Stenella coeruleoalba). Sci. Rep. Whales Res. Inst.*, 21: 95–123.

Jansen, J., 1953. Studies on the cetacean brain. The gross anatomy of the rhombencephalon of the fin whale *(Balaenoptera physalus* L.). *Hvalråd, Skr.*, 37: 1–32. (Cited from Breathnach '60)

Jelgersma, G., 1934. Das Gehirn der Wassersäugetiere. Von Johann Ambrosius Barth. Leipzig. 238 pp.

Kankeleit, O., 1913. Zur vergleichenden Morphologie der unteren Säugetierolive (mit Bemerkungen über Kerne in der Olivenperipherie). *Arch. Anat. Physiol.*, 1–40.

Kojima, T., 1951. On the brain of the Sperm whale *(Physeter catodon* L.). *Sci. Rep. Whales Res. Inst.*, 6: 49–72.

Kooy, F.H., 1917. The inferior olive in vertebrates. *Folia Neurobiol. (Lpz.)*, 10: 205–369.

Kooy, F.H., 1920. The inferior olive in Cetacea. *Folia Neurobiol. (Lpz.)*, 11: 647–664.

Langworthy, O.R., 1932. A description of the central nervous system of the porpoise *(Tursiops truncatus). J. Comp. Neur.*, 54: 437–500.

Langworthy, O.R., 1935. The brain of the whalebone whale, *Balaenoptera physalus. Johns Hopkins Hosp. Bull.*, 57: 143–147.

Matsumoto, Y., 1953. Contributions to the study on the internal structure of the cetacean brainstem. *Acta Anat. Nippon.*, 28: 167–177, (in Japanese with abstract in English).

McFarland, W.L., P.J. Morgane and Jacobs, M.S., 1969. Ventricular system of the brain of the Dolphin, *Tursiops truncatus,* with comparative anatomical observations and relations to brain specializations. *J. Comp. Neur.*, 135: 275–368.

Morgane, P.J. and M.S. Jacobs, 1972. Comparative anatomy of the cetacean nervous system. *In* Harrison, R.J. (ed.) *Functional anatomy of marine mammals*, 1: 117–244, Academic Press, London and New York.

Nakai, J. and T. Shida, 1948. Sinus-hairs of the Sei-whale *(Balaenoptera borealis). Sci. Rep. Whales Res. Inst.*, 1: 41–47.

Nishiwaki, M., 1957. Semi-Kujira Tokubetsu Chosa no Gaiyo. (Summary of the special investigation on the right whales). *Geiken Tsushin*, 64 *(Whales Res. Inst. Tokyo):* 160–179 (in Japanese).

Ogawa, T. and S. Arifuku, 1948. On the acoustic system in the cetacean brains. *Sci. Rep. Whales Res. Inst.*, 2: 1–20.

Ogawa, T. and T. Shida, 1950. On the sensory tubercles of lips and of oral cavity in the Sei and the Fin whale. *Sci. Rep. Whales Res. Inst.*, 3: 1–16.

Omura, H., 1958. North pacific right whale. *Sci. Rep. Whales Res. Inst.*, 13: 1–52.

Omura, H., S. Ohsumi, T. Nemoto, K. Nasu and T. Kasuya, 1969. Black right whales in the North Pacific. *Sci. Rep. Whales Res. Inst.*, 21: 1–78.

Olszewski, J., 1950. On the anatomical and functional organization of the spinal trigeminal nucleus. *J. Comp. Neur.*, 92: 401–413.

Pilleri, G., 1964. Morphologie des Gehirnes des "Southern Right Whale", *Eubalaena australis* Desmoulins 1822 (Cetacea, Mysticeti, Balaenidae). *Acta Zool. (Stockholm)*, 46: 245–272.

Rawitz, B., 1909. Das Zentralnervensystem der Cetaceen. II. Die Medulla oblongata von *Phocaena communis* and *Balaenoptera rostrata*. *Arch. Mikr. Anat. Entw.*, 73: 182–260.

Ries, F.A. and O.R. Langworthy, 1937. A study of the surface structure of the brain of the whale *(Balaenoptera physalus* and *Physeter catodon)*. *J. Comp. Neur.*, 68: 1–47.

Riese, W., 1928. Ueber das Vorderhirn das Walfötus *(Megaptera Boops)*. *Anat. Anz.*, 65: 255–260.

Riese, W., 1936. Ueber die Entwicklung des Wahlhirns. *Proc. Royal Acad. Amsterdam.* 39: 97–109.

Sano, T., 1909. Vergleichend-anatomische und physiologische Untersuchungen über die Substantia gelatinosa des Hinterhorns. *Arb. Neur. Inst., Wien. Univ.*, 17: 1–71.

Seki, Y., 1958. Observations on the spinal cord of the right whale. *Sci. Rep. Whales Res. Inst.*, 13: 231–251.

Seki, Y., 1982. An evaluation of the P - T (Phosphor molybdic acid and Tin chloride) method for staining the general strucure of central nervous tissues. *Okajimas Folia Anat. Jpn.*, 58: 987–996.

Spitzka, E.C., 1886. The intra-axial course of the auditory tract. *New York Med. Journ.*, Sept. 18: 315–318. (Cited from Hosokawa et al. 1969 and Ogawa and Arifuku 1948).

Valeton, M.T., 1908. Beitrag zur vergleichenden Anatomie des hinteren Vierhügels des Menschen und einiger Säugetiere. *Arb. Neur. Inst. Wien. Univ.*, 14: 29–75.

Wilson, R.B., 1933. The anatomy of the brain of whale *(Balaenoptera sulfurea)*. *J. Comp. Neur.*, 58: 419–481.

Yamada, M., 1953. Contribution to the anatomy of the organ of hearing of whales. *Sec. Rep. Whales Res. Inst.*, 8: 1–79.

Yamasaki, F., S. Komatsu and T. Kamiya, 1978. Taste buds in the pits at the posterior dorsum of the tongue of *stenella coeruleoalba*. *Sci. Rep. Whales Res. Inst.*, 30: 285–290.

EXPLANATION OF FIGURES

Figs 3–18. A little enlarged (× 4.5) photographs of selected sections stained by the Weigert-Pal carmine (Figs 3–12) or the Kultschitzky's method (Figs 13–18).
Serial section number of each section is as follows:

Fig. 3 : P–85
Fig. 4 : P–170
Fig. 5 : P–245
Fig. 6 : P–305
Fig. 7 : P–375
Fig. 8 : M–120
Fig. 9 : M–230
Fig. 10 : M–300
Fig. 11 : M–390
Fig. 12 : M–480
Fig. 13 : A–112
Fig. 14 : A–182
Fig. 15 : A–282
Fig. 16 : A–402
Fig. 17 : A–462
Fig. 18 : A–562

Figs 19–27. Photographs showing internal structures of selected sections (showing left side in each, except the Fig. 27) stained by the P-T method, a little magnified (× 10 or × 15). Serial section number, level and magnification of each section are indicated as follows:

Fig. 19 : A–544, level of the oculomotor nucleus, × 10.
Fig. 20 : A–464, level of the trochlear nucleus, × 10.
Fig. 21 : A–74, upper pontine level, × 10.
Fig. 22 : M–464, level of the facial nerve root, × 15.
Fig. 23 : M–344, level of the Deiters's nucleus, × 15.
Fig. 24 : Same section, same side as Fig. 23, spinal trigeminal complex and facial nucleus, × 15.
Fig. 25 : M–174, ventral part of the middle medullary level, × 10.
Fig. 26 : P–414, ventral part of the lower medullary level, × 15.
Fig. 27 : P–384, dorsal part of the lower medullary level, right side, × 10.

LIST OF ABBREVIATIONS IN FIGURES

Aqd	Aqueduct of the midbrain
CA	Anterior horn
CI	Inferior colliculus
CrC	Crus cerebri
FA	Anterior funiculus
FL	Lateral funiculus
FLM	Medial longitudinal fascicle
FLo	Pontine longitudinal fasciculi
FP	Posterior funiculus
FR	Reticular formation
FS	Solitary tract
IOLm	Medial nucleus of the inferior olive
LL	Lateral lemniscus
LM	Medial lemniscus
Nam	Nucleus ambiguus
NB	Nucleus of Bischoff
NCE	Nucleus cuneatus externus
NCo	Nucleus of the cochlear nerve
ND	Nucleus of Deiters
NDX	Dorsal motor nucleus of the vagus nerve
NFP	Nuclei of the posterior funiculi
NI	Nucleus intercalatus
NLL	Nucleus of the lateral lemniscus
NMeV	Mesencephalic nucleus of the trigeminal nerve
NMoV	Motor nucleus of the trigeminal nerve
NPo	Nuclei pontis
NPV	Principal nucleus of the trigeminal nerve
NRL	Lateral reticular nucleus
NRm	Nucleus ruber magnocellularis
NSpV	Spinal nucleus of the trigeminal nerve
NTr	Nucleus of the trapezoid body
NVeI	Nucleus inferior of the vestibular nerve
NVeM	Nucleus medialis of the vestibular nerve
NIII	Oculomotor nucleus
NIV	Trochlear nucleus
NVI	Abducens nucleus
NVII	Facial nucleus
NVIId	Dorsal subnucleus of the facial nucleus
NXII	Hypoglossal nucleus
PCI	Inferior cerebellar peduncle
PCM	Middle cerebellar peduncle
PCS	Superior cerebellar peduncle
Py	Bulbar pyramid
Ra	Raphe
RIII	Oculomotor nerve
RIV	Trochlear nerve
RV	Trigeminal nerve
RVI	Abducens nerve
RVII	Facial nerve
RIX	Glossopharyngeal nerve
RX	Vagus nerve
RXIc	Cranial root of the accessory nerve
RXII	Hypoglossal nerve
SHe	Tract of Held
SMo	Stria of Monakow
SN	Substantia nigra
SOLl	Lateral nucleus of the superior olive
SOLm	Medial nucleus of the superior olive
TMeV	Mesencephalic root of the trigeminal nerve
TSpV	Spinal root of the trigeminal nerve
VQ	Fourth ventricle

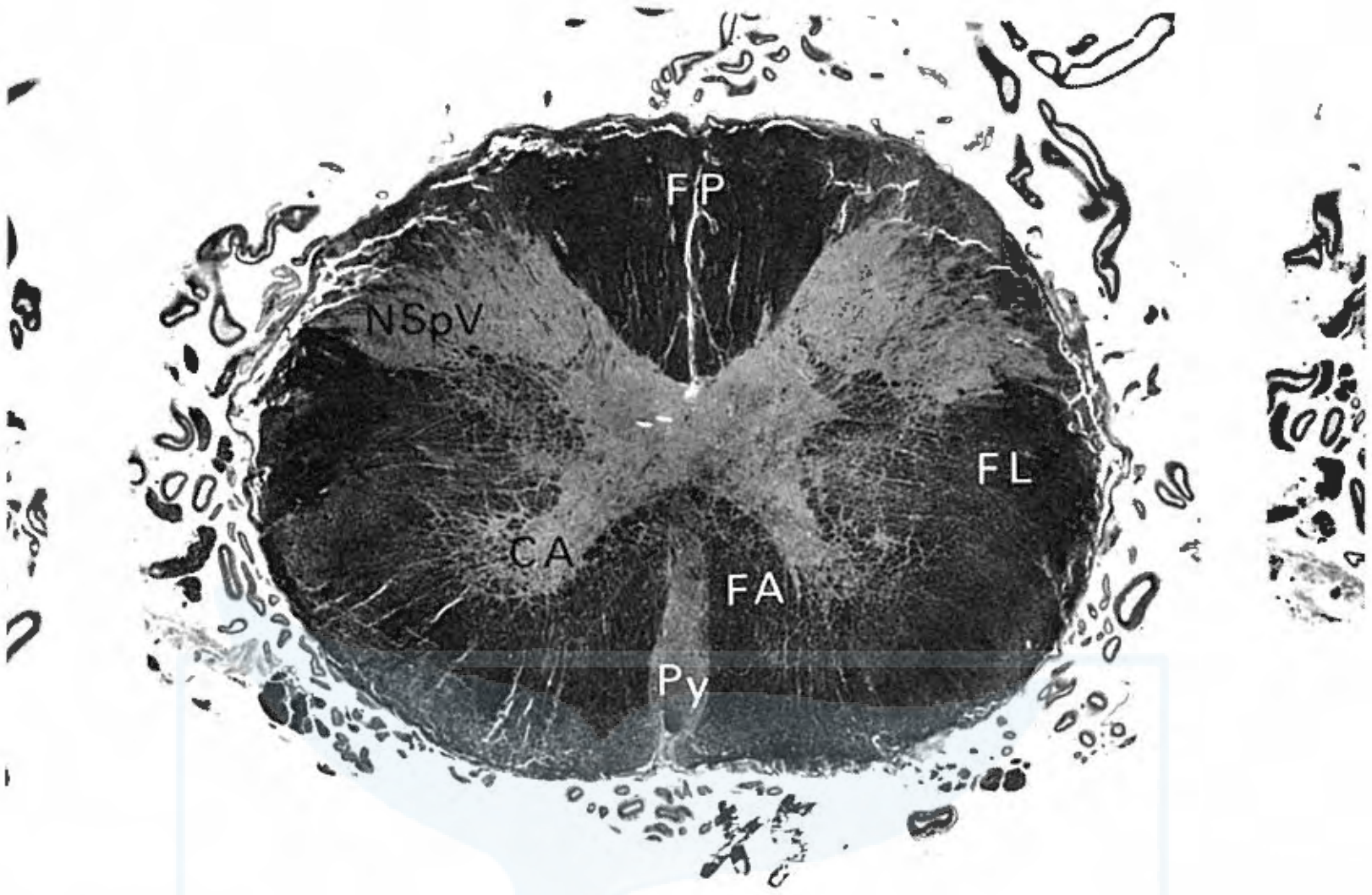

Fig. 3

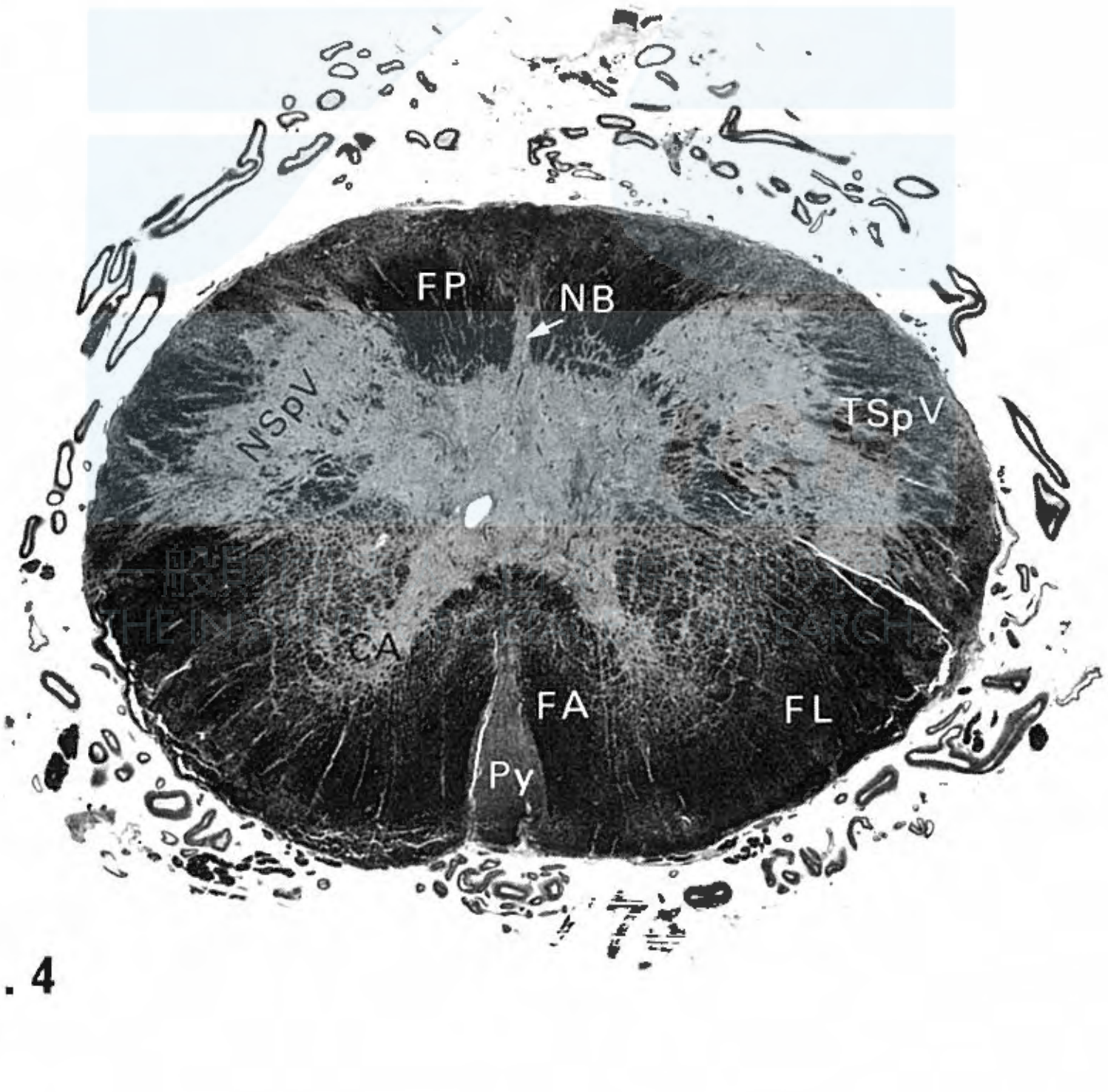

Fig. 4

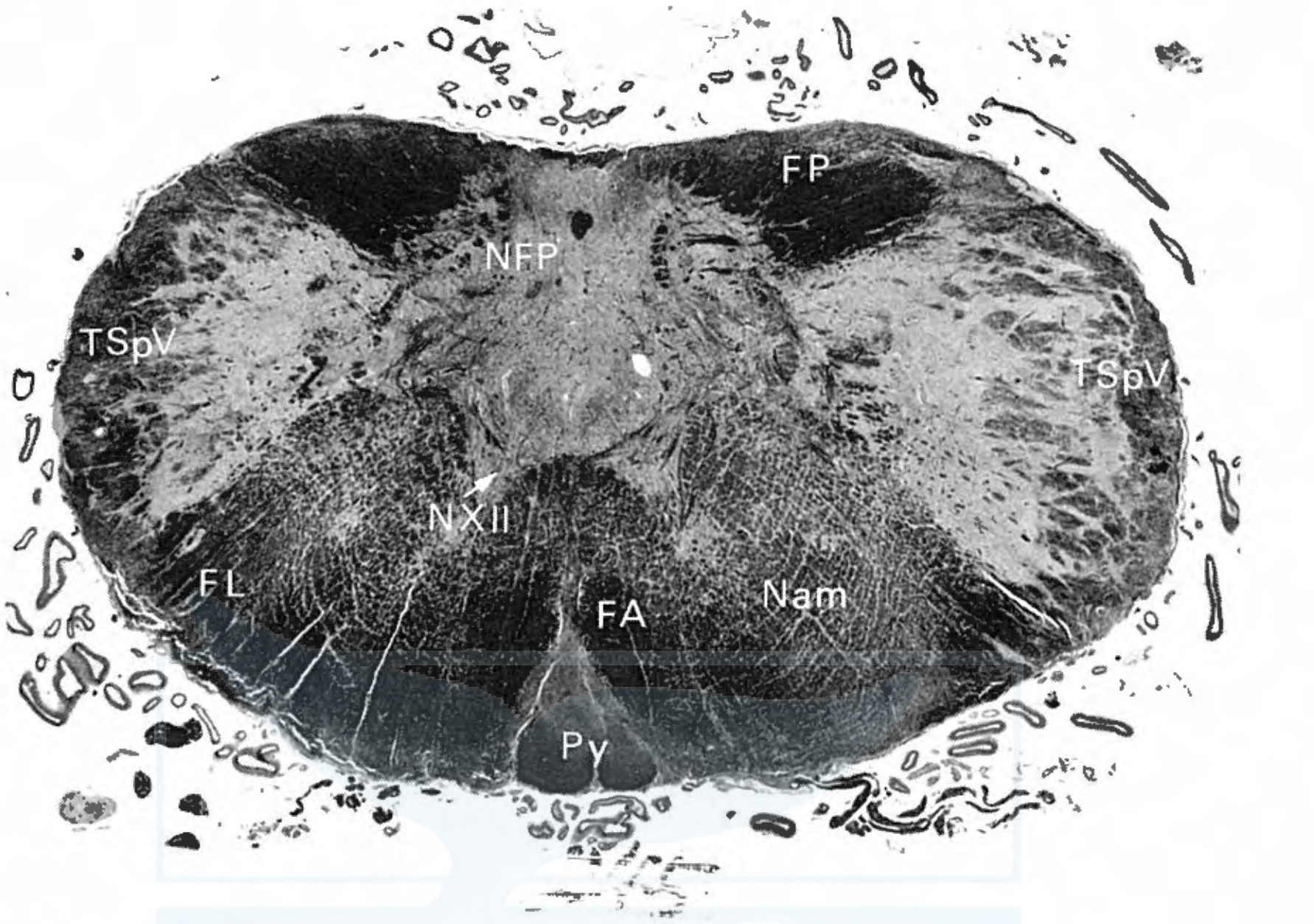
FP
NFP
TSpV
TSpV
NXII
FL
FA
Nam
Py

Fig. 5

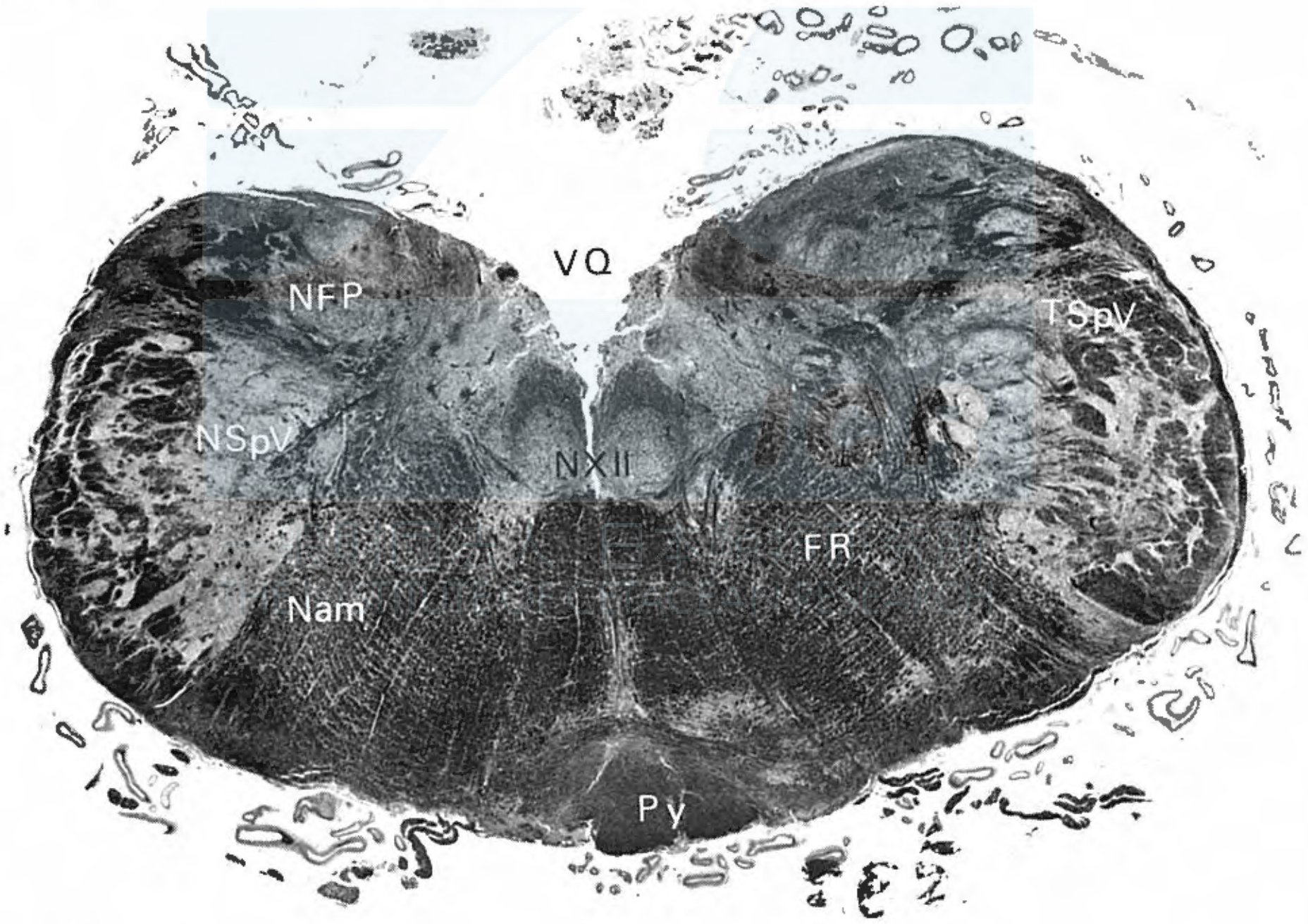
VQ
NFP
TSpV
NSpV
NXII
FR
Nam
Py

Fig. 6

Fig. 7



Fig. 8

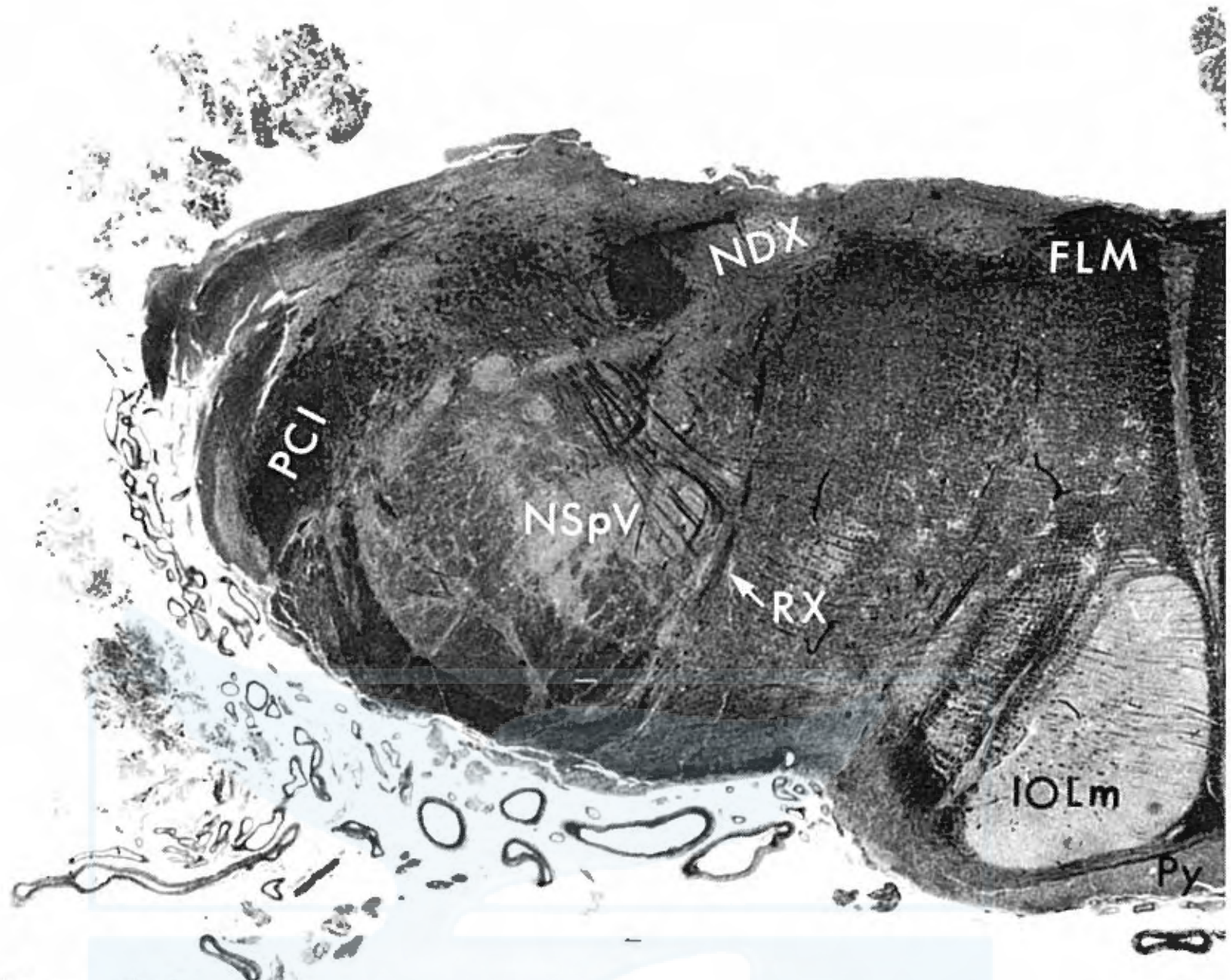

Fig. 9 L

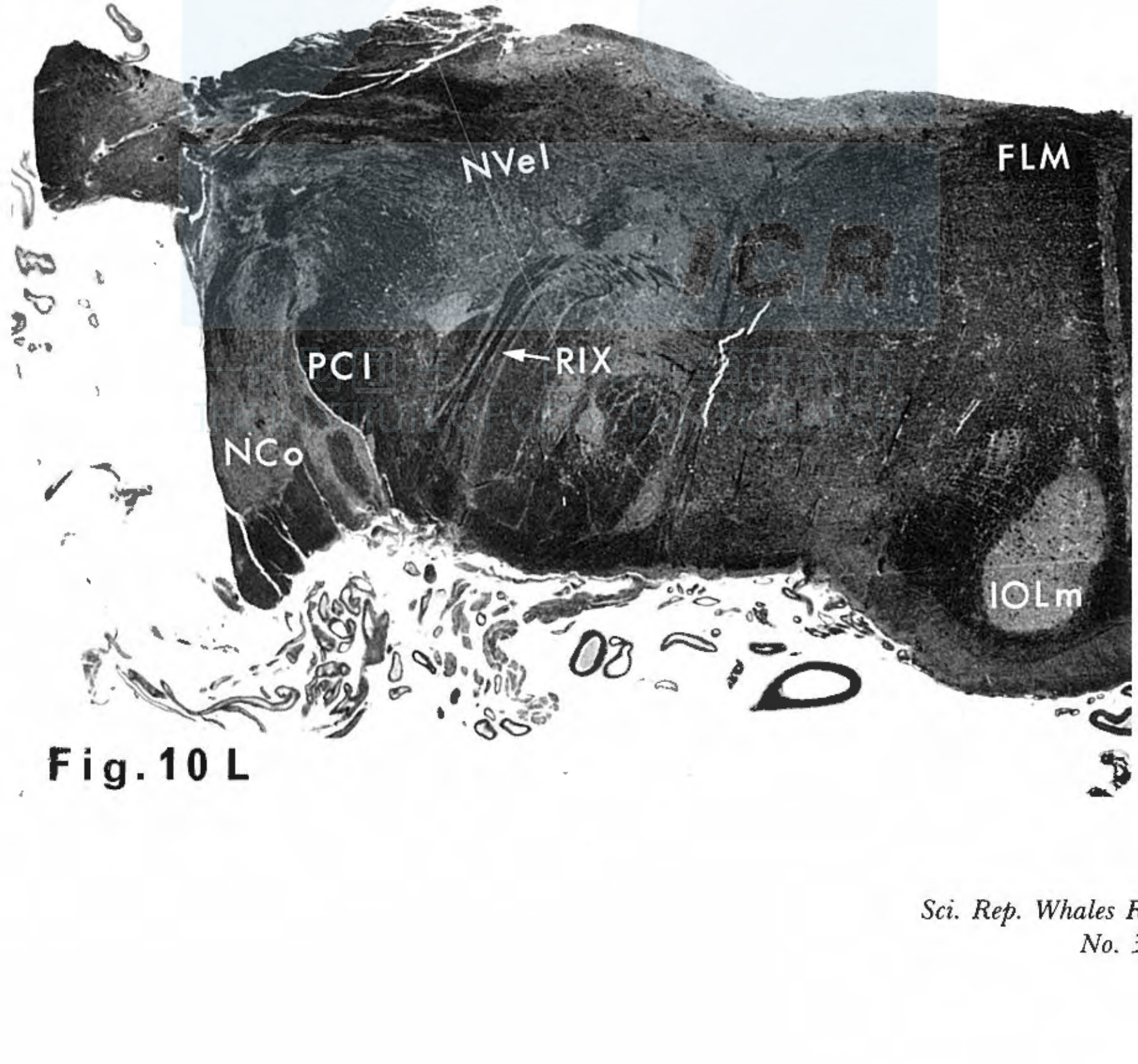

Fig. 10 L

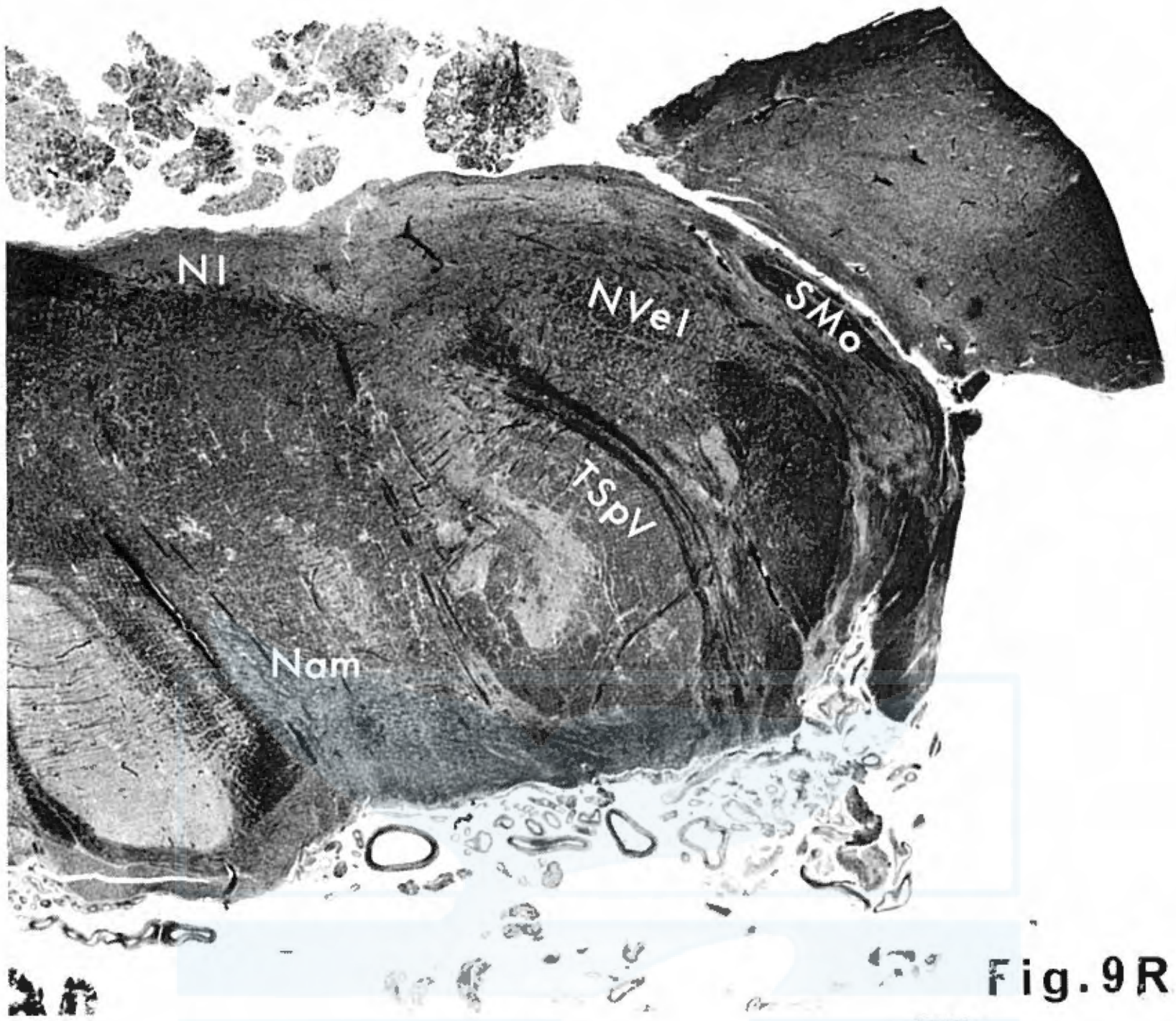

Fig. 9R

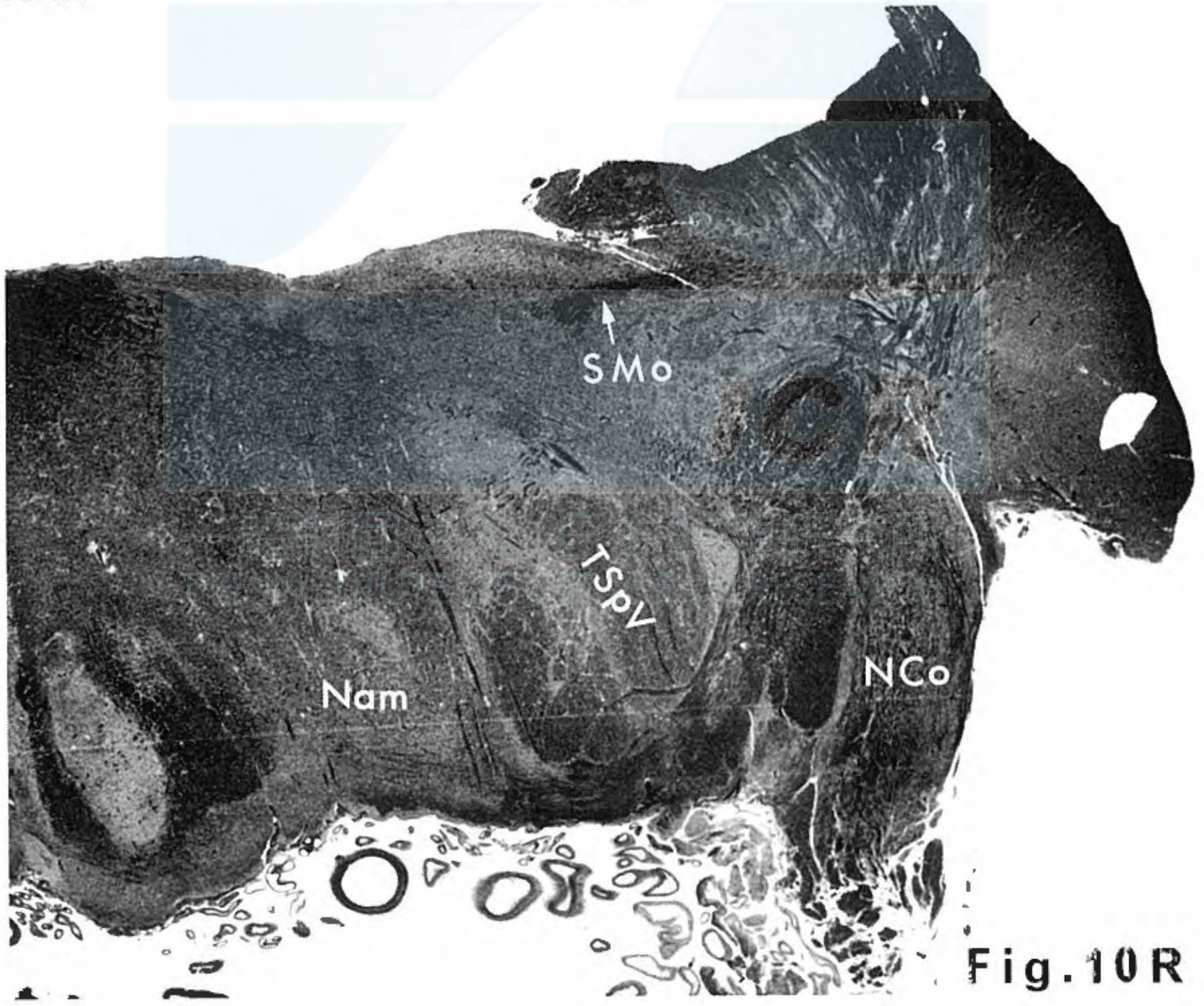

Fig. 10R

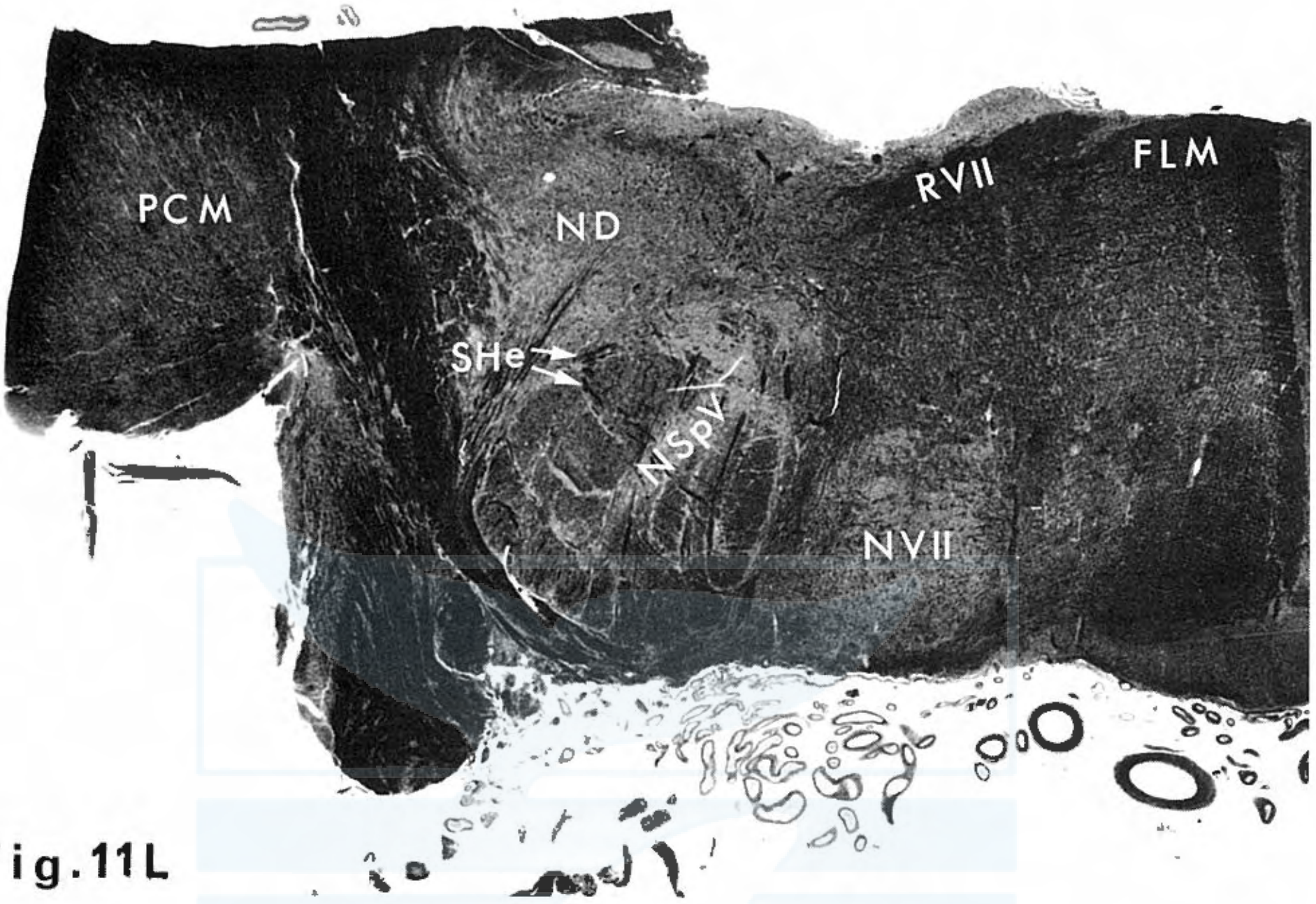

Fig.11L

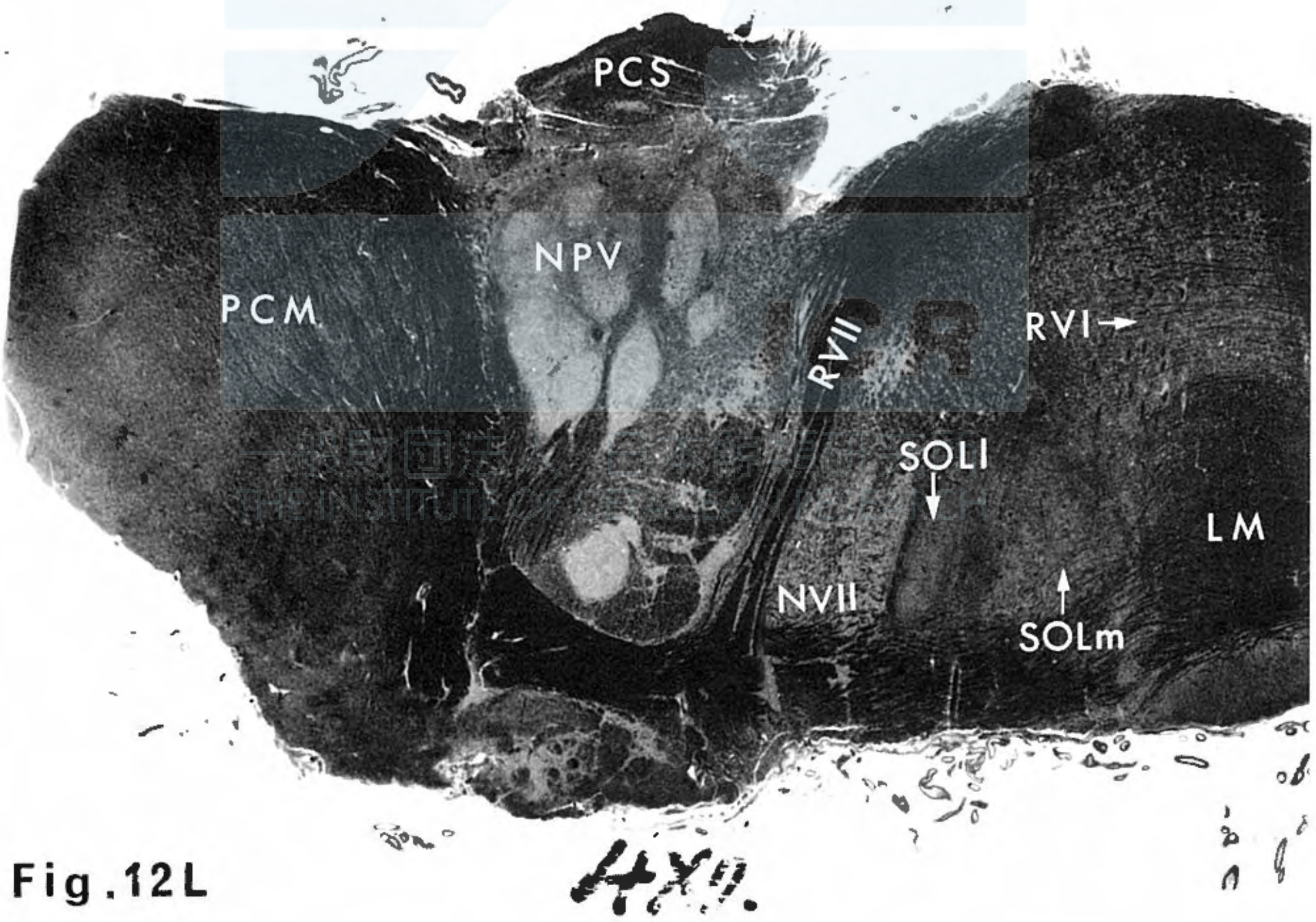

Fig.12L

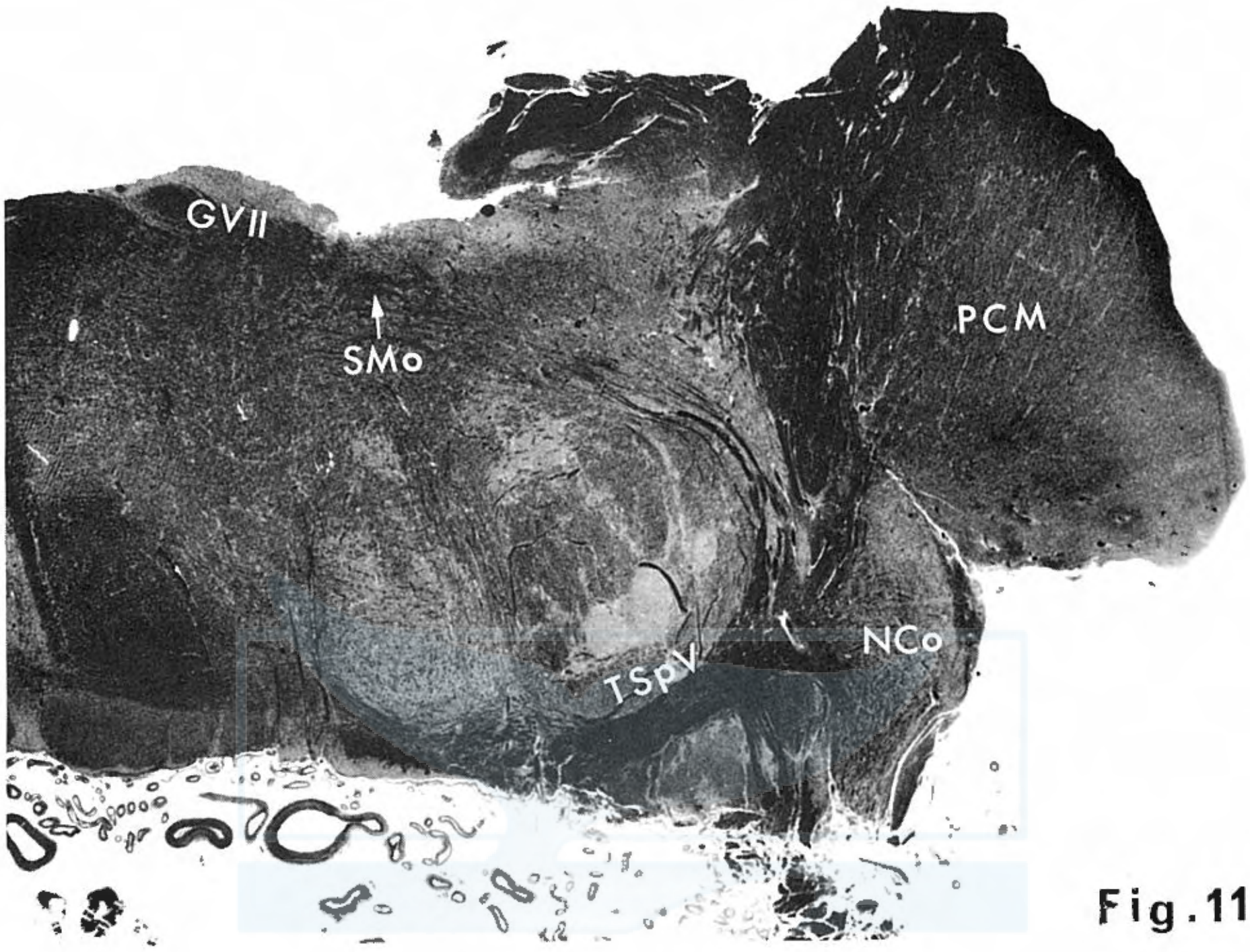

Fig. 11R

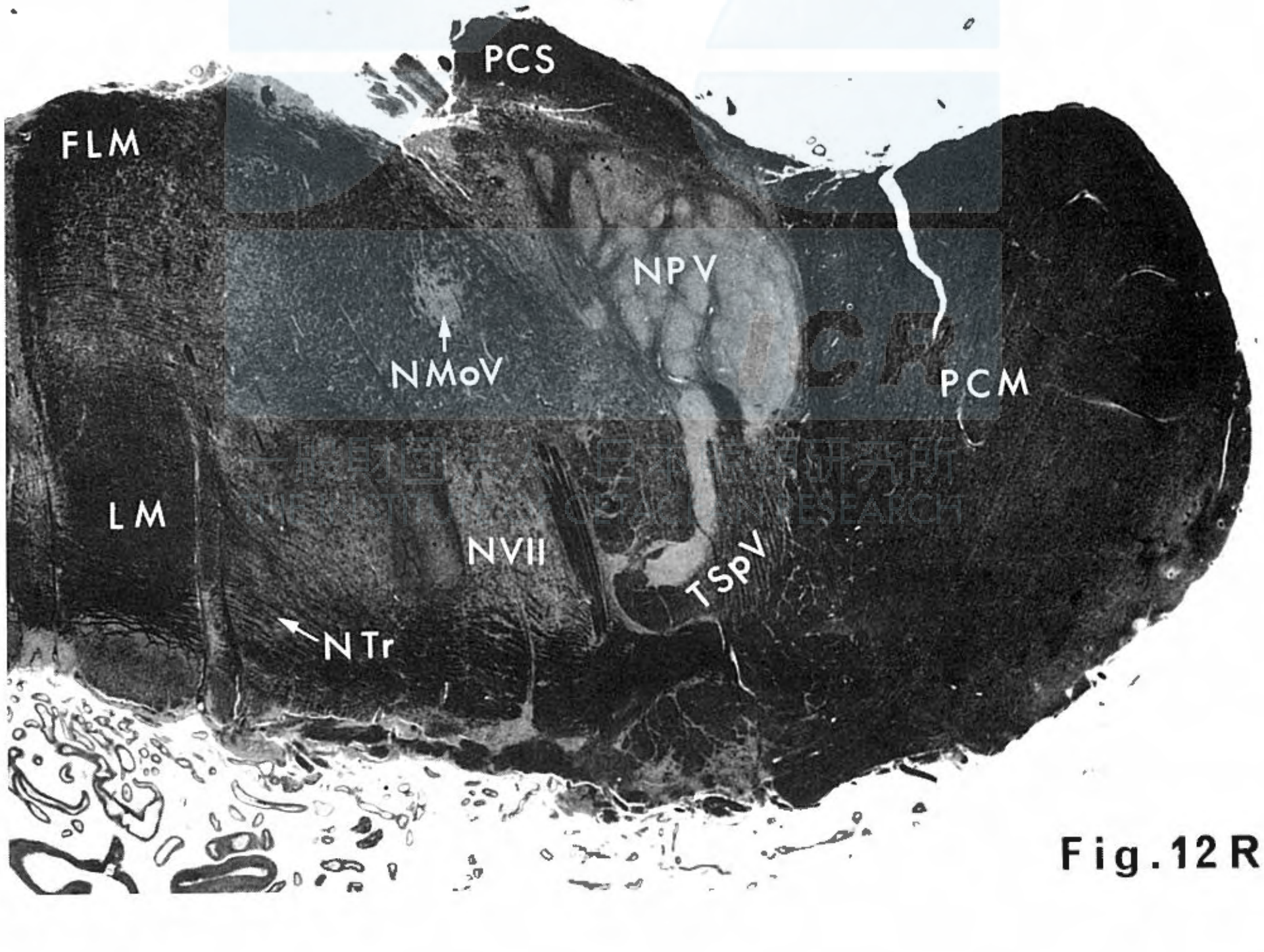

Fig. 12R

Fig.13L

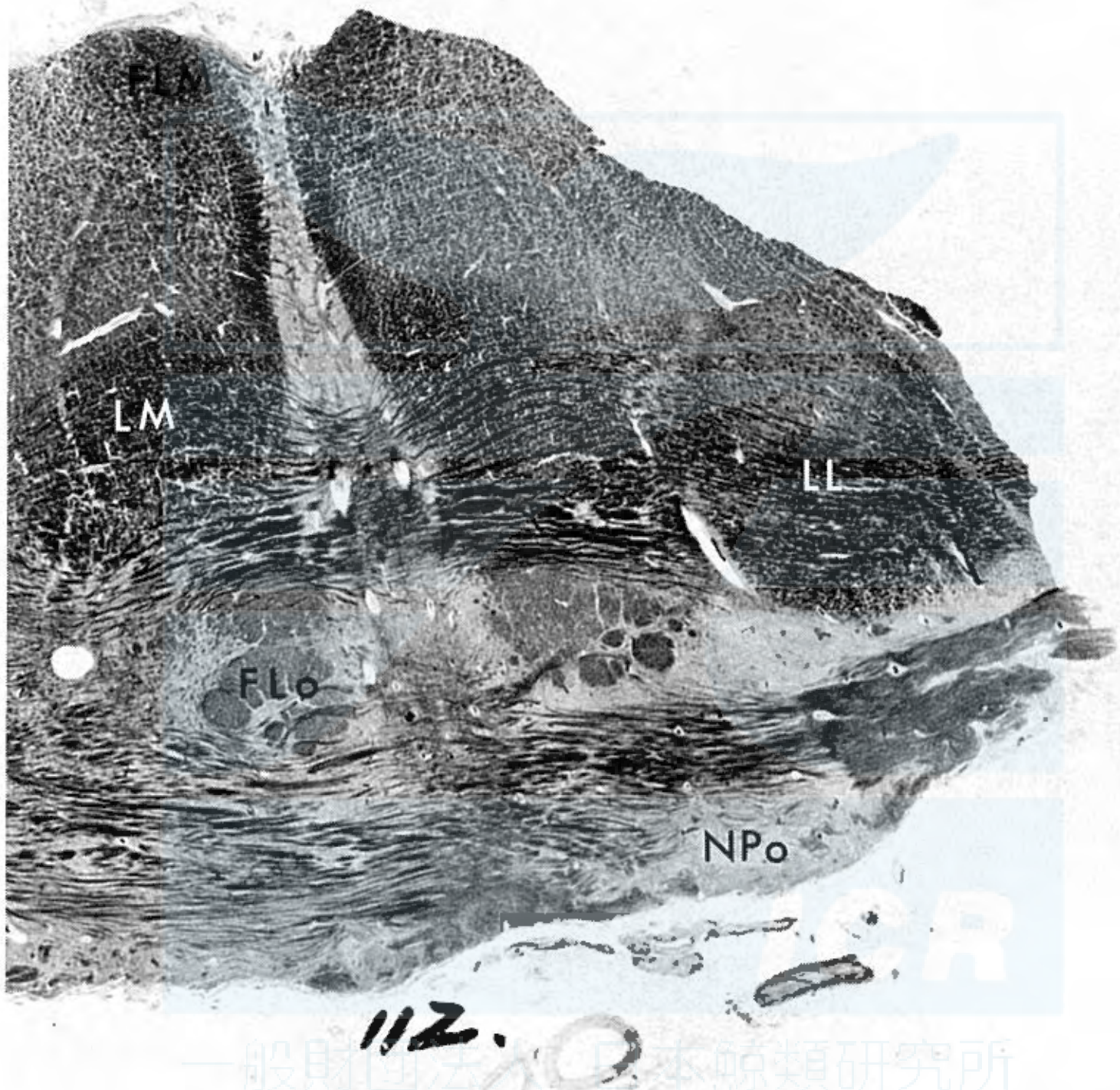

Fig. 13 R

1X2.

Fig.14L

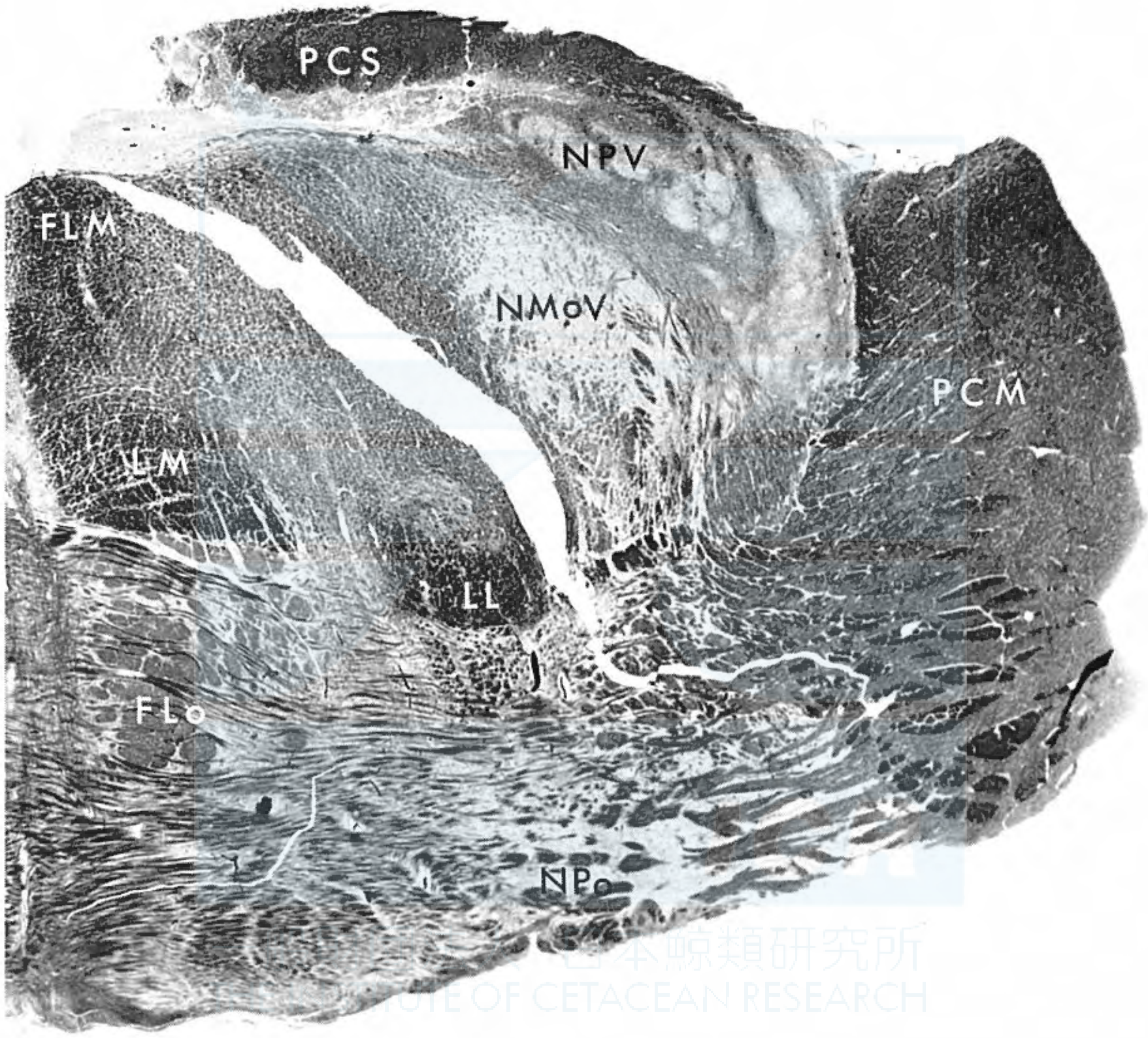

Fig. 14 R

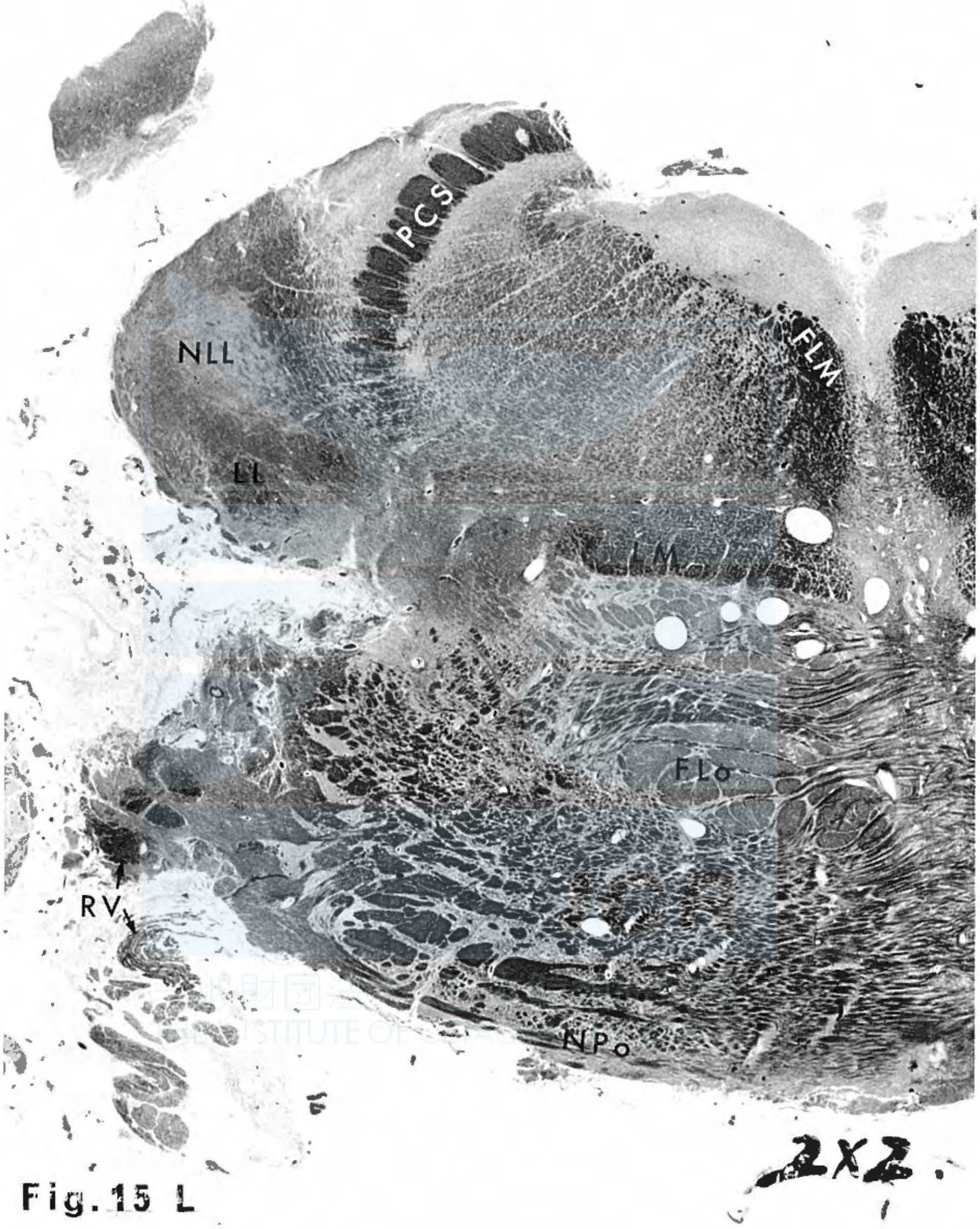

Fig. 15 L

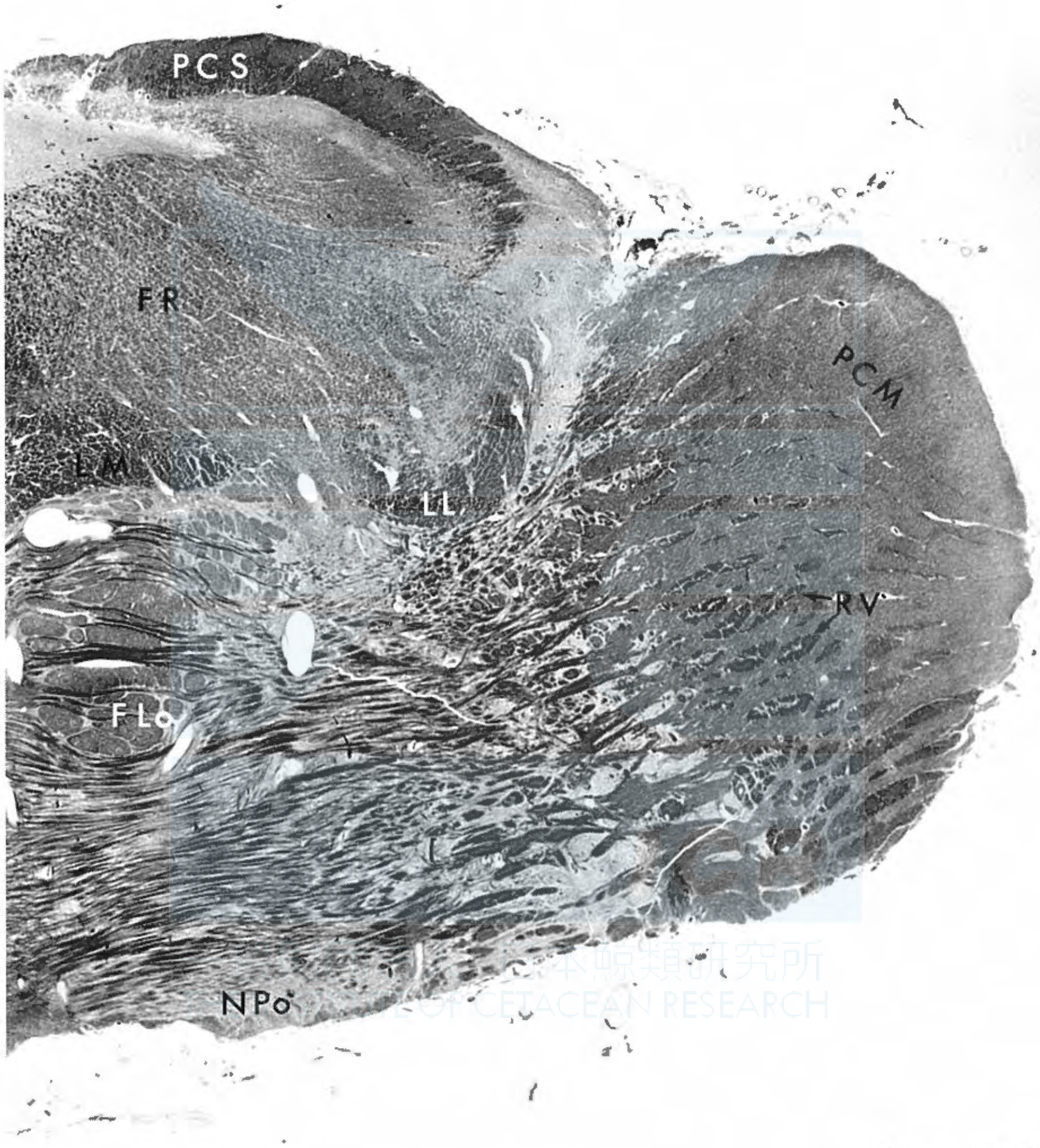

Fig. 15R



Fig.16L



Fig. 16R



Fig.17L



Fig. 17R

Fig. 18

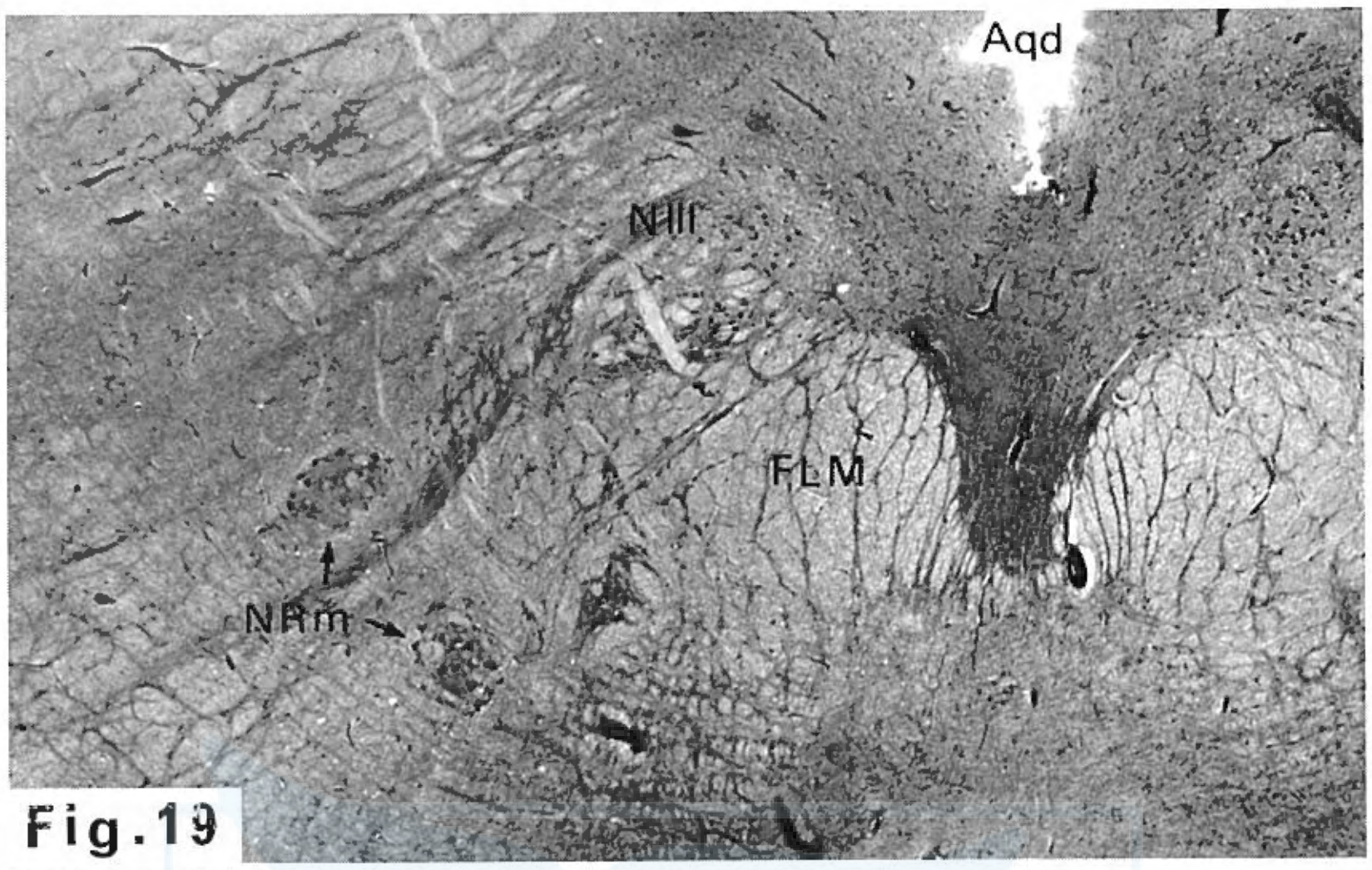

Fig. 19

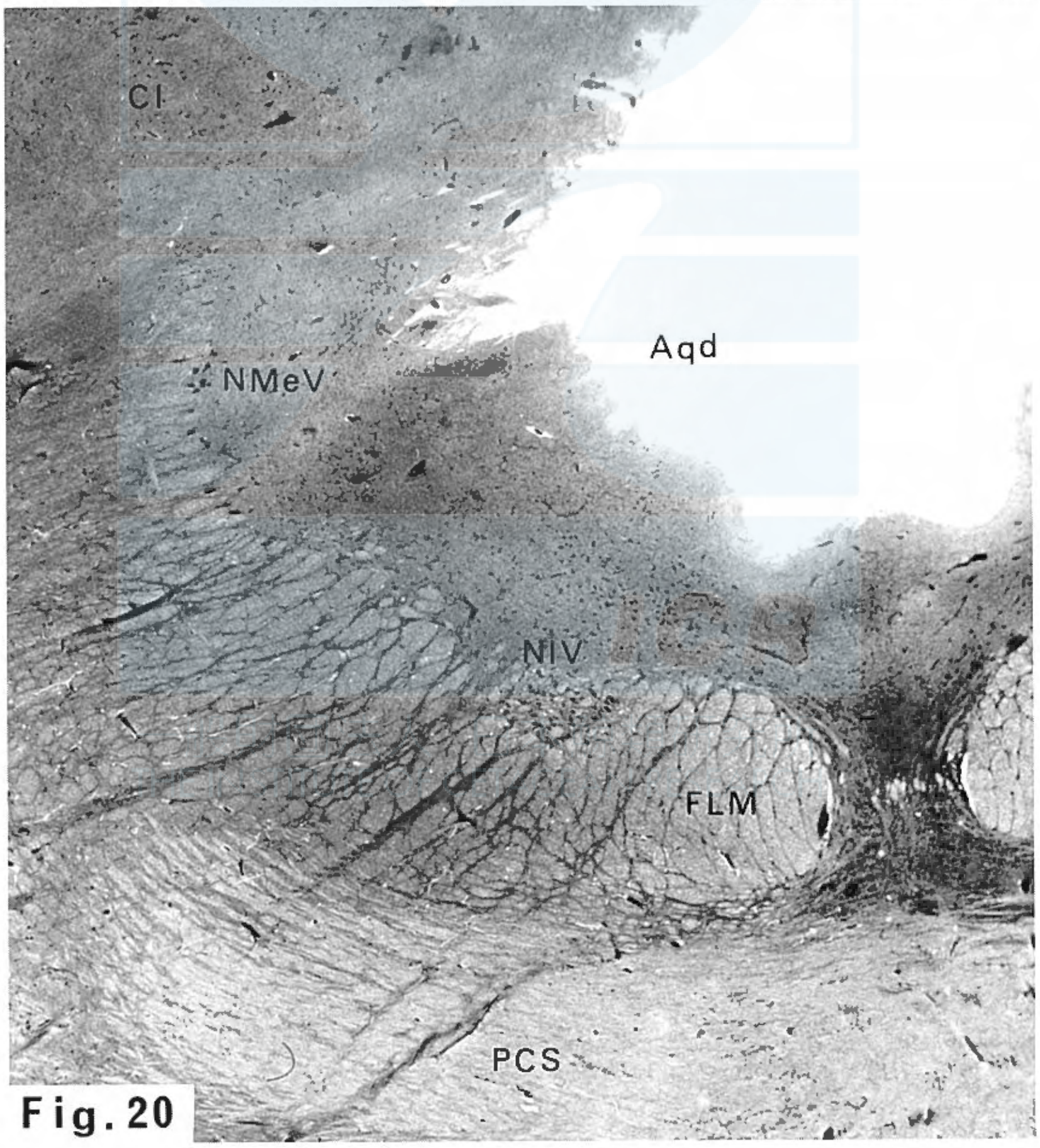

Fig. 20

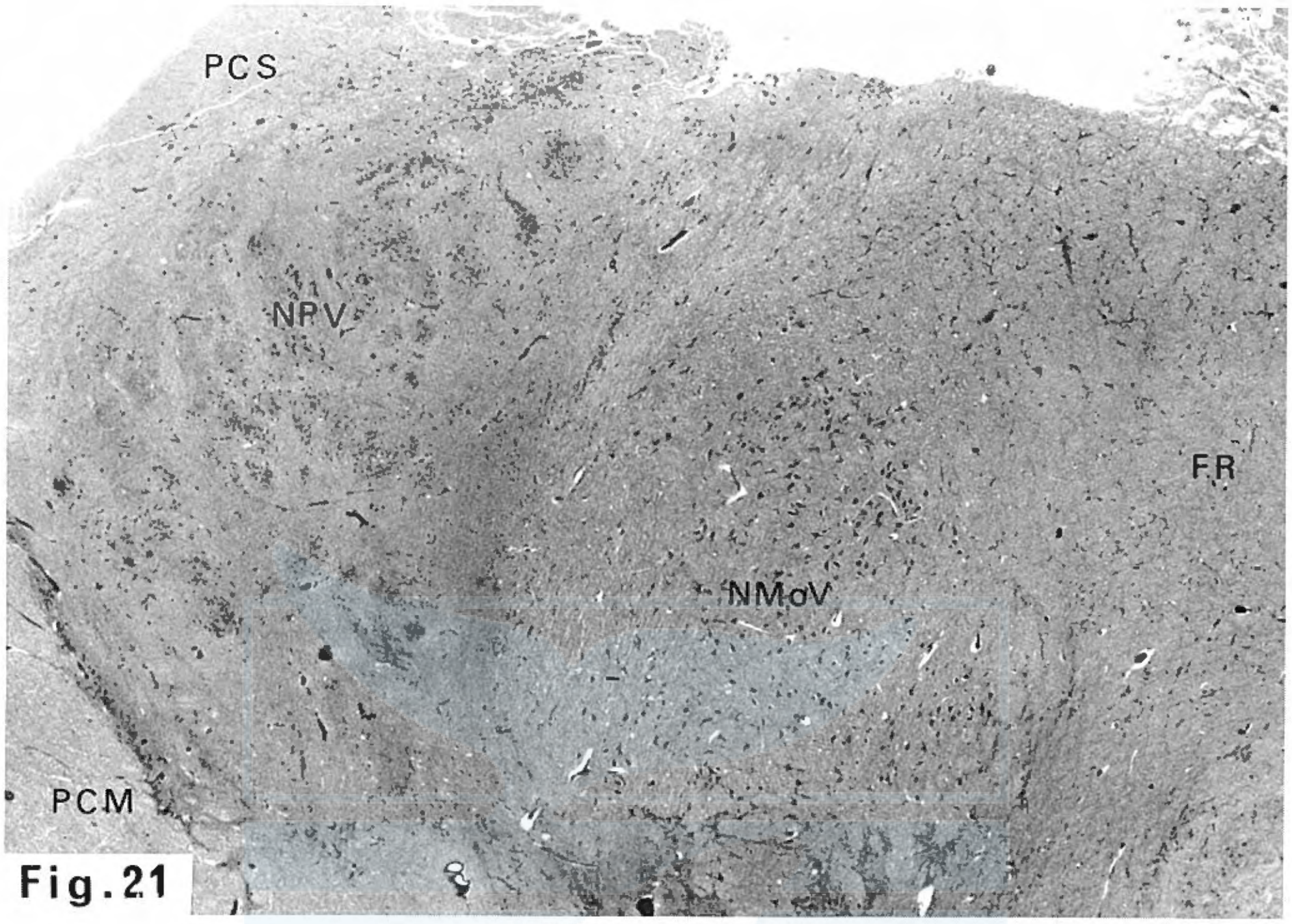

Fig.21



Fig.22

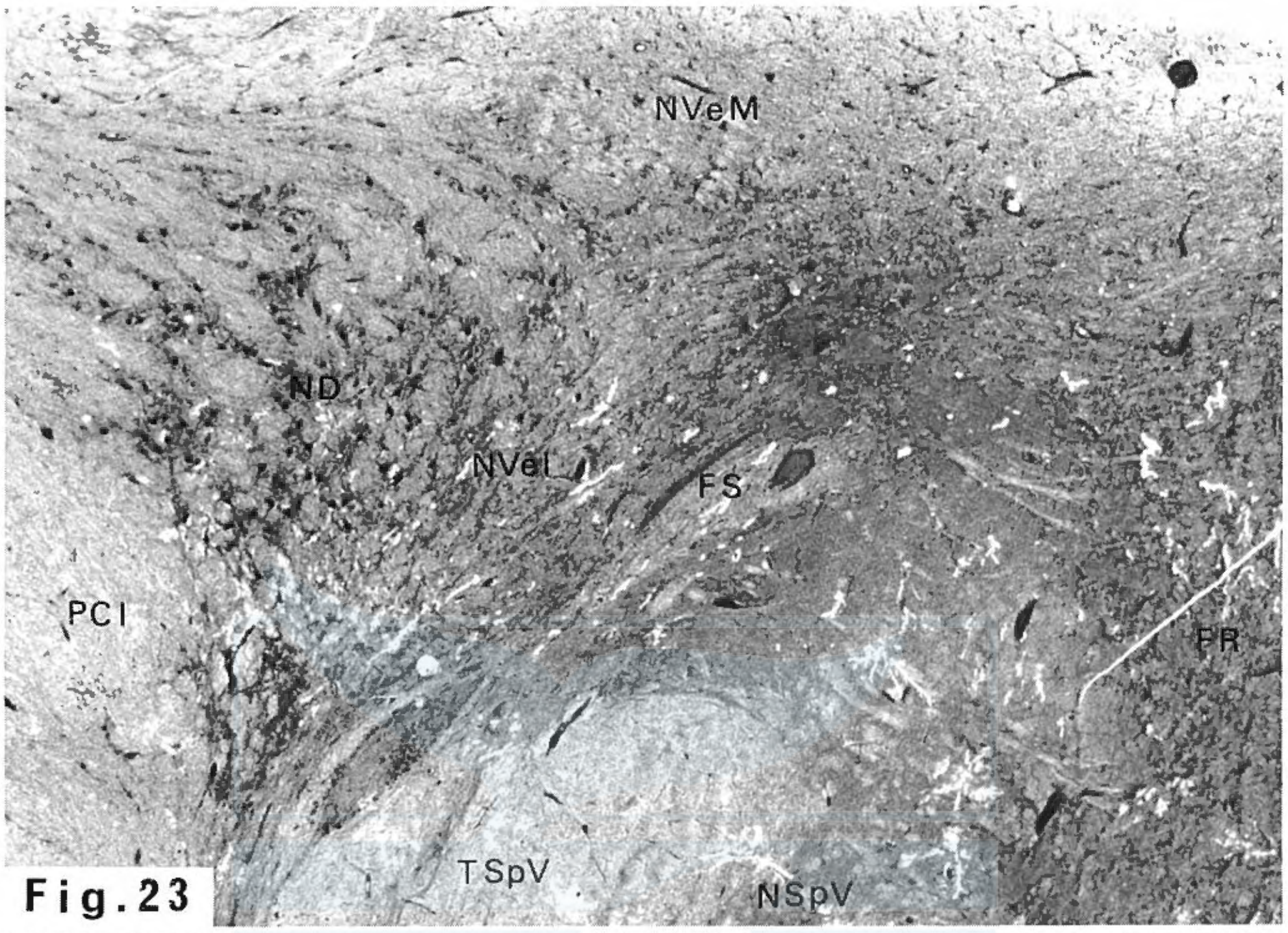

Fig. 23

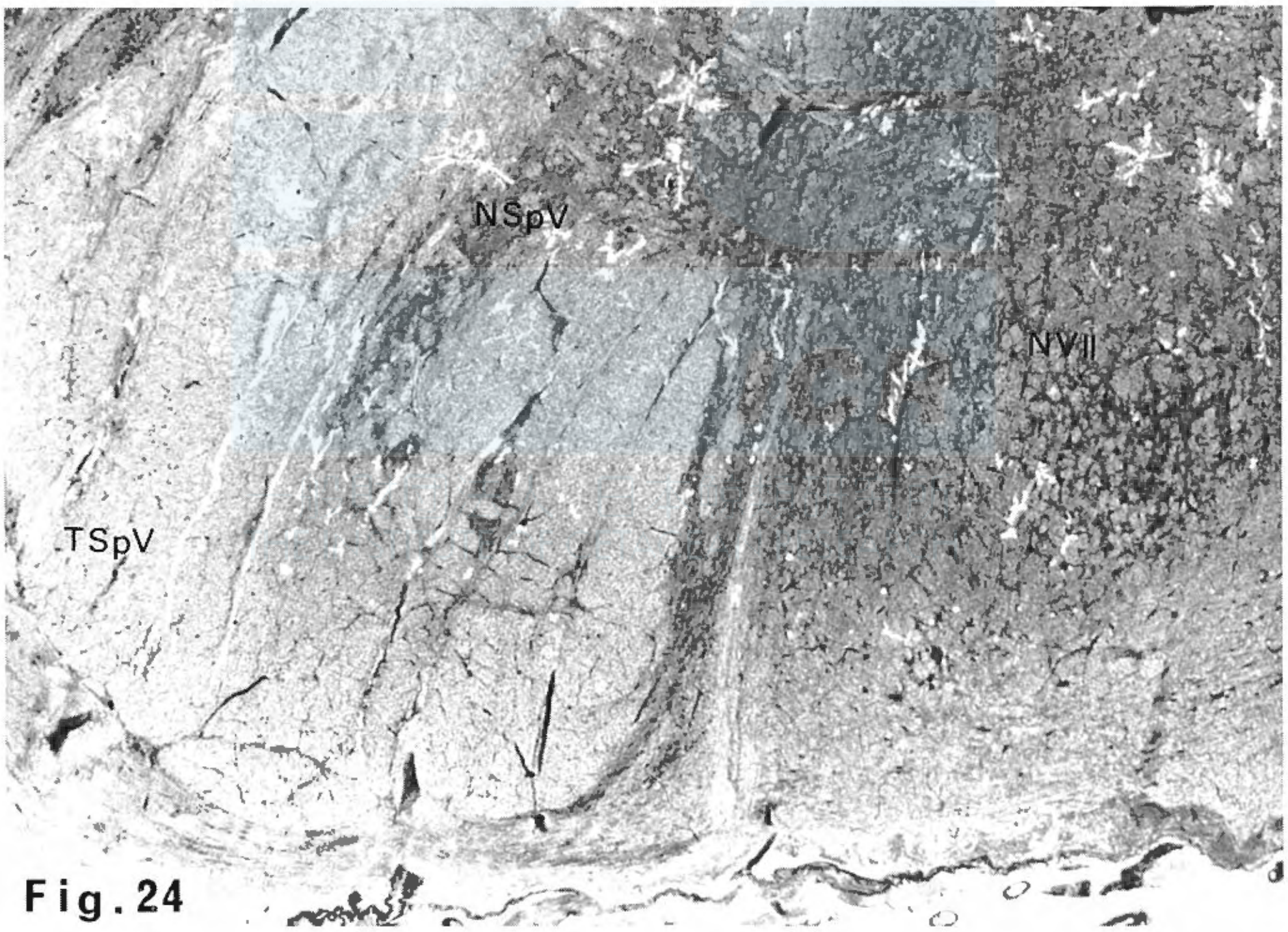

Fig. 24

Fig.25



Fig.26



Fig. 27