THE STOMACH OF THE BOUTU, *INIA GEOFFRENSIS*: COMPARISON WITH THOSE OF OTHER PLATANISTIDS

FUSAO YAMASAKI* AND TOSHIRO KAMIYA**

* *Department of Biology, Sapporo Medical College, Sapporo*
** *Anatomical Laboratory, College of Medical Technology, University of Tsukuba, Ibaraki*

ABSTRACT

The stomach of the Boutu, *Inia geoffrensis*, was examined macro- and light microscopically, and was compared with those of the three other species of Platanistidae as well as with those of some sea dolphins. The stomach of the *Inia* consisted of a forestomach, main stomach, connecting channel, and pyloric stomach. The esophagus was more straightly continuous with the main stomach than with the forestomach, and the opening to the main stomach was larger than that to the forestomach. The biflucating manner of the esophagus of two species of Platanistidae, *Inia* and *Platanista*, was different from that of sea dolphins, in which the esophagus leads directly to the forestomach. The forestomach of the *Inia*, lined with stratified squamous epithelium, was relatively smaller than that of the *Platanista*, and those of sea dolphins. The main stomach of the *Inia* was a large thick-walled musclar sac, rather resembling that of *Pontoporia*, without any partitions as seen in the *Platanisata* and *Lipotes*. It was lined with a plicated glandular mucous membrane possessing mucous, parietal, and chief cells. A narrow zone of cardiac glands existed only adjacent to the esophagus. The main stomach communicated with the pyloric stomach by a crooked, narrow connecting channel, which lay in the caudo-dexter part of the main stomach. The channel was similar to that of the *Pontoporia* in its location and shape. The elongated tubular pyloric stomach lay in the dorso-dexter part of the connecting channel, and was smaller than the globular pyloric stomach of *Platanista* and the J-shaped one of the *Pontoporia*. The mucosae of the channel and pyloric stomach were similar and contained pyloric glands. The histological nature of each part of the stomach observed in the three species of Platanistidae and in other sea dolphins was fundamentally the same. A distinct sphincter could be seen between the end of the pyloric stomach and the duodenal ampulla as in other dolphins.

INTRODUCTION

A number of morphological studies of the stomach in several species of sea dolphins have been made by several investigators. Those done on the stomach of the fresh water dolphins, Platanistidae (in which four genera, *Pontoporia*, *Platanista*, *Lipotes*, *Inia* are included), however, seem to be very small in number, probably due to this family's special distribution. Burmeister (1867, 1869) and Anderson (1879) re-

Sci. Rep. Whales Res. Inst.,
No. 33, 1981, 69–81

ported upon the anatomy of the Franciscana, *Pontoporia blainvillei*, and the Susu, *Platanista gangetica*, respectively, the structures of the stomachs of which were described briefly. We also made macro- and light microscopical observations of the stomachs of *Platanista* (Yamasaki and Takahashi, 1971) and *Pontoporia* (Yamasaki *et al.*, 1974). Hinton and Pycraft (1922) made a preliminary note on the morphology of the Baiji, *Lipotes vexillifer*, including a very brief description of the morphology of the stomach. Recently, anatomical reports on the stomach of *Lipotes* have appeared from Chen and Chen (1975), and Zhou *et al.* (1978, 1979ab). Since among the stomachs of Platanistidae the morphology of that of *Inia* has not yet been reported upon, the structure of the stomach of this dolphin will be reported upon here and will be compared with those of the three other species of Platanistidae and some sea dolphins which have been described.

MATERIAL AND METHODS

The specimen of the stomach of the Boutu (Amazon dolphin), *Inia geoffrensis*, (body length 204 cm, female) used for this study was provided by the Kamogawa Sea World, Chiba, Japan, after death from unidentified disease. Owing to contraction due to fixation, and deformity caused by transportation to our laboratory, the external features of the stomach seemed to vary considerably from the natural state. The organ was preserved in 10% formalin solution and small pieces were taken for light microscopy. Paraffin sections from these were stained with hematoxylin-eosin, Azan, PAS and Alcian blue for histological examinations.

The stomachs of *Platanista* and *Pontoporia* already reported upon by us and of *Stenella coerureoalba* were reexamined for comparision.

OBSERVATIONS

Although the stomach may vary in size and the appearance of the exterior or the interior may depend on whether the stomach is in a fixed or unfixed state as well as on the amount of its contents, an empty *Inia* stomach fixed was examined and the following features were obtained. The stomach of the *Inia* consisted of three compartments; fore, main, and pyloric stomachs. A narrow compartment or channel connected the main stomach with the pyloric stomach. The first part of the duodenum immediately distal to the pyloric stomach was dilated and formed the duodenal ampulla. External grooves, which might have been visible between compartments in good condition, could not be clearly distinguished owing to considerable deformity. The thick-walled esophagus, which had distinct longitudinal folds with many fine transverse folds in its interior, was more straightly continuous with the main stomach than with the forestomach, and its thick mucous folds generally continued toward those of the main stomach.

Forestomach The forestomach was located in the dorsal and slightly left side of the mainstomach and was a pear-shaped muscular sac (Fig. 1). The cranial two-thirds of its ventro-dexter wall adhered to the dorsal wall of the main stomach.

The depth of the forestomach, from the biflucation between the fore- and main stomach to the bottom of the forestomach, was approximately 12 cm and its width was about 4 cm at the lower widest part. The interior of the forestomach had firm, mainly longitudinal folds. Several folds were continuous with those in the esophagus but were far thinner. There were also occasional transverse folds. The wall of the forestomach was far thinner than that of the esophagus, and was about 5 mm in thickness at the dorso-sinister wall, becoming thick, about 7 mm or more, at the bottom and at the wall facing the main stomach. There was no definable sphincter at the opening.

The mucosa of the forestomach was non-glandular, consisting of stratified squamous epithelium continuing from the esophagus (Fig. 3). Its thickness, however, was about half or less than that of the esophagus, measuring from 0.3 to 0.4 mm in thickness. The superficial cells of the epithelium appeared to have lost their nuclei and undergone cornification. The connective tissue papillae occupied about 80% of the total thickness of the epithelium. The tunica musclaris was far thinner than that of the esophagus, consisting of inner circular and outer longitudinal smooth muscle layers, about 0.5 mm thick in all near the bottom of the forestomach, with the former being roughly twice the thickness of the latter. No glands were seen within the forestomach.

Main stomach This was a firm, thick-walled muscular sac and was the largest compartment (Fig. 1). It was somewhat pear-shaped and measured about 18 cm in depth, and 11 cm across at the upper widest part. The entrance was approximately 1.5 cm in diameter and no definable sphincter existed. The main stomach was lined with a thick, mucous membrane thrown into numerous thick folds giving the whole a labyrinthine appearance. In the lower part, however, the folds were somewhat longitudinal in arrangement. An abrupt change at the entrance from the stratified squamous epithelium of the esophagus to the glandular epithelium of the main stomach was exhibited by the mucous membrane (Fig. 4). This epitheliar border obliquely ran from the cranio-dexter to the caudo-sinister reaching about 2 cm lower than the septum between the main and forestomachs. There was an opening, about 3 mm in diameter, that led into the next compartment, a connecting channel, at the ventro-dexter wall of the main stomach, about 2 cm from the caudal end of the main stomach. The wall, which seemed to be considerably contracted by fixation, was very thick, from 1 to 2.5 cm.

Light microscopically, tubroalveolar glands composed of light cells of one kind could be seen only along the narrow zone, about 1 mm in breadth, adjacent to the border between the esophagus and the main stomach (Fig. 4). Although the material was in poor condition, these glands were clearly distinguishable from the remaining glands of the main stomach and were surely cardiac glands. The glands covering the remainder of the main stomach were seen to be of the same structure. They were simple and tubular, with little evidence of branching, and measured from 2 to 2.5 mm in length (Fig. 5). The glandular mucosa, with surface mucous cells which were stained with PAS, were continuous with the epithelial lining of the gastric pits, measuring about one eighth of the length of the glands. Although post-mortem degeneration of the gland cells prevented an exact histological examination, chief and parietal cells could be seen along the cripts. Staining with PAS and Alcian blue revealed no evidence of mucous neck cells. Parietal cells were numerous, being uniformly distributed down to the base of the gland. Chief cells were not so basophilic in dyeing in our specimen. The approximate ratio of

1

2

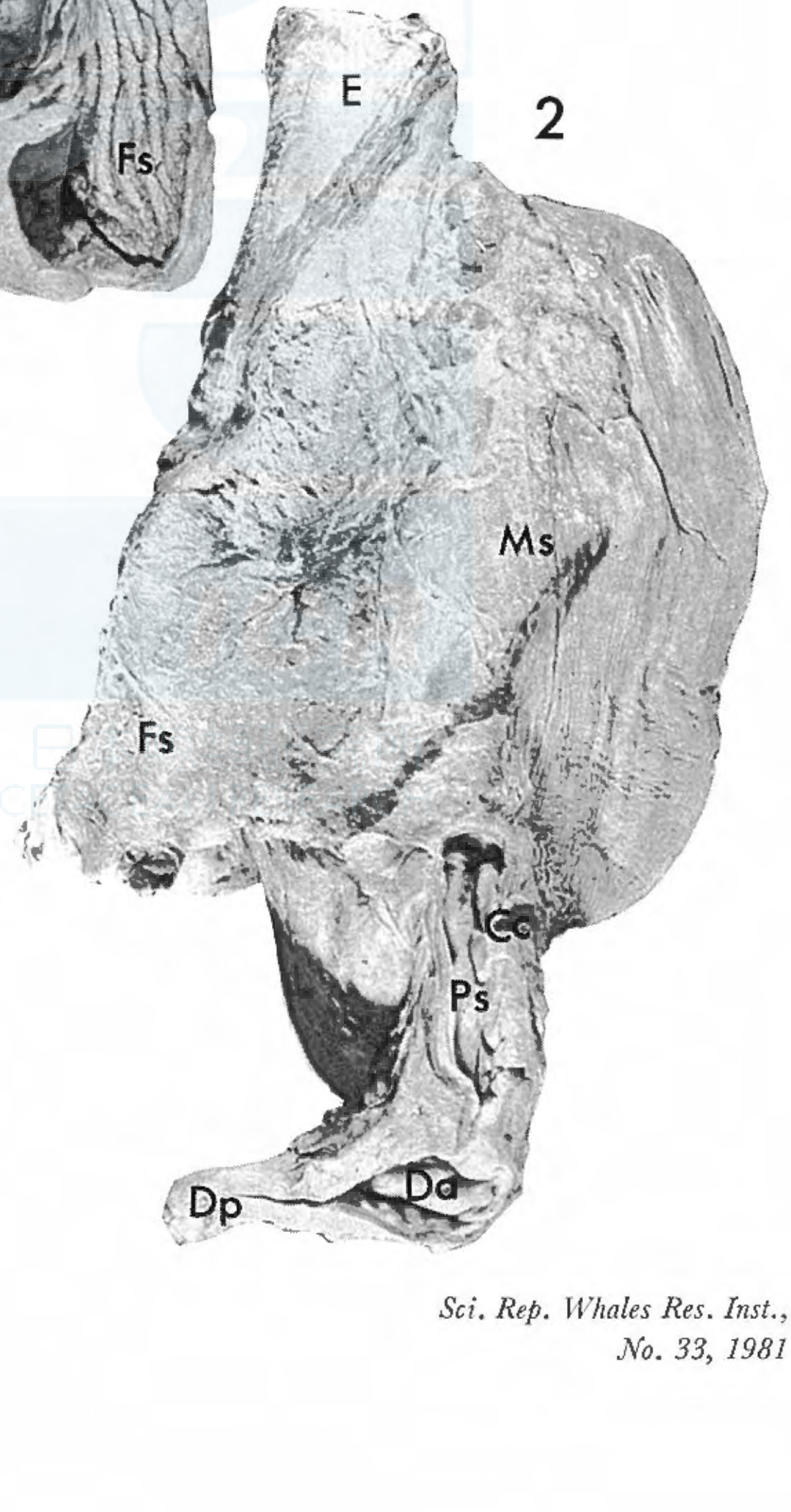

the parietal cells to the chief cells was 1: 3 or less. Musclaris mucosa did not form a conspicuous compact layer. Several relatively well developed smooth muscle layers, from 0.5 to 1 cm in thickness mainly arranged circularly, could be seen in the loose connective tissue of the very thick tela submucosa. There were many relatively thick blood vessels and few thin nerve fiber bundles in the submucosa. The muscular coat consisted of two complete layers (inner circular and outer longitudinal). The former was about twice as thick as the latter, with both together measuring about 1.5 mm.

Connecting channel The channel was situated on the right near the caudal end of the main stomach and, on the whole, was roughly in a sagittal plane (Fig. 1). The course of the channel was rather dorsad in direction for approximately 1 cm, then dextro-caudad for about 2 cm. Thereafter it curved upwards for about 2 cm, reaching almost to the dorsal side of the main stomach. It then curved to the right for a short distance, after which it entered the pyloric stomach. The diameter of the channel was about 8 mm throughout its whole course, with there being no sphincteric structures along the channel, though its entrance become slightly narrower. The inner surface of the channel exhibited some low longitudinal folds. The caudo-ventral wall of the channel of the mid-part was thin, about 5 mm thick, with the remainder being far thicker.

The mucosa of the connecting channel was composed of tubular glands of a mucous type (Fig. 6). The thickness of the mucosa was from 0.5 to 1 mm. The pits extended about halfway the length of the glands. The glands were not tightly packed and were separated by a relatively well developed lamina propria. Muscularis mucosa was inconspicuous. The submucosa was about half the thickness of that of the main stomach and was relatively vascularized. The muscularis consisted of two layers and measured approximately 1 mm or more in all at the ventral wall. The muscle on the dorso-sinister side of the channel was continuous with that surrounding the main stomach.

Pyloric stomach The pyloric stomach was an elongated tubular compartment, with its cranio-ventral part closely abuting the dorso-dexter wall of the main stomach (Fig. 2). It was situated in a cranio-sinister to caudo-dexter position, lying roughly in a frontal plane. The pyloric stomach was approximately 6 cm in length and about 1.5 cm or more in diameter. The opening from the connecting channel was present on the ventral wall and was about 1.5 cm away from the cranial end of the pyloric stomach. The pyloric sphincter, containing muscle and with an opening

←Fig. 1. The inner aspect of the stomach and the initial part of the duodenum of *Inia geoffrensis*, which is cut off along the lesser and greater curvatures. The esophagus is more straightly continuous to the main stomach than to the forestomach. Note the differences of thickness in the wall, and the appearance of the mucosa of the forestomach and of the main stomach. E-esophagus; Fs-forestomach; Ms-main stomach; Cc-connecting channel; Ps-pyloric stomach; Da-duodenal ampulla; Dp-duodenum proper. An arrow indicates the entrance of the connecting channel.

←Fig. 2. Dorsal view of the stomach and the initial part of the duodenum of the *Inia*. A portion of the interior of the anal part of the connecting channel, the pyloric stomach, and the duodenal ampulla are seen. for abbreviations see Fig. 1.

3

4

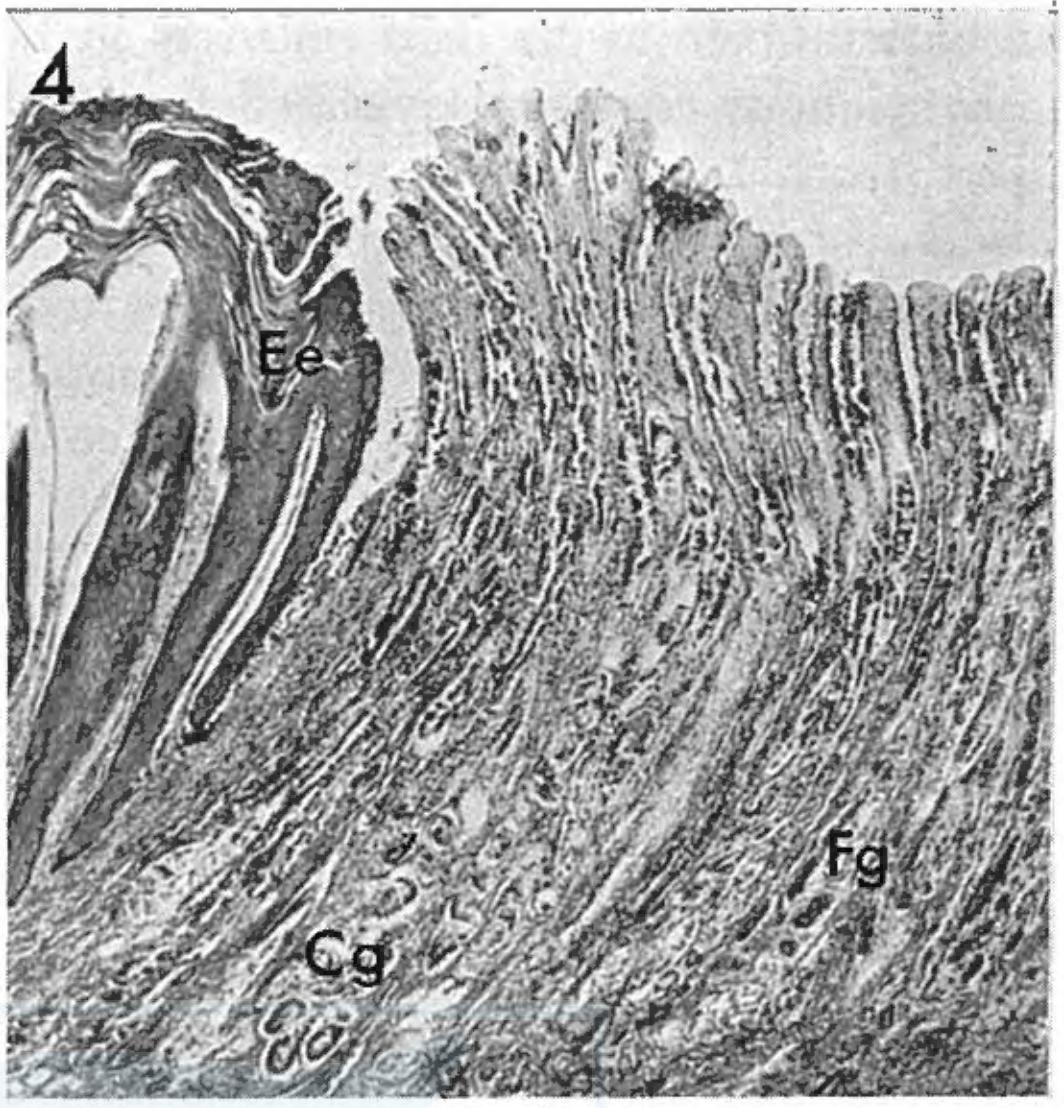

5

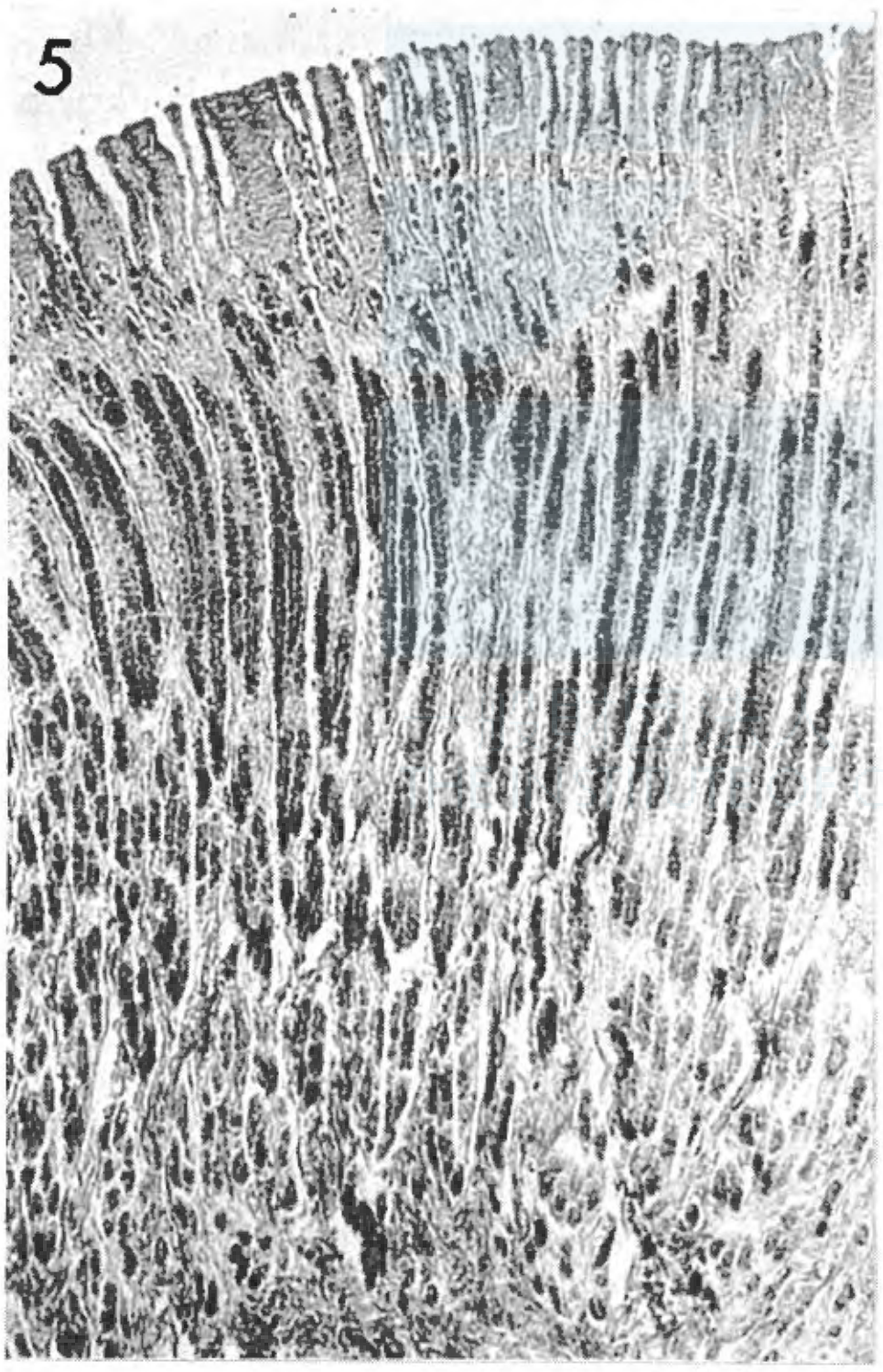

6

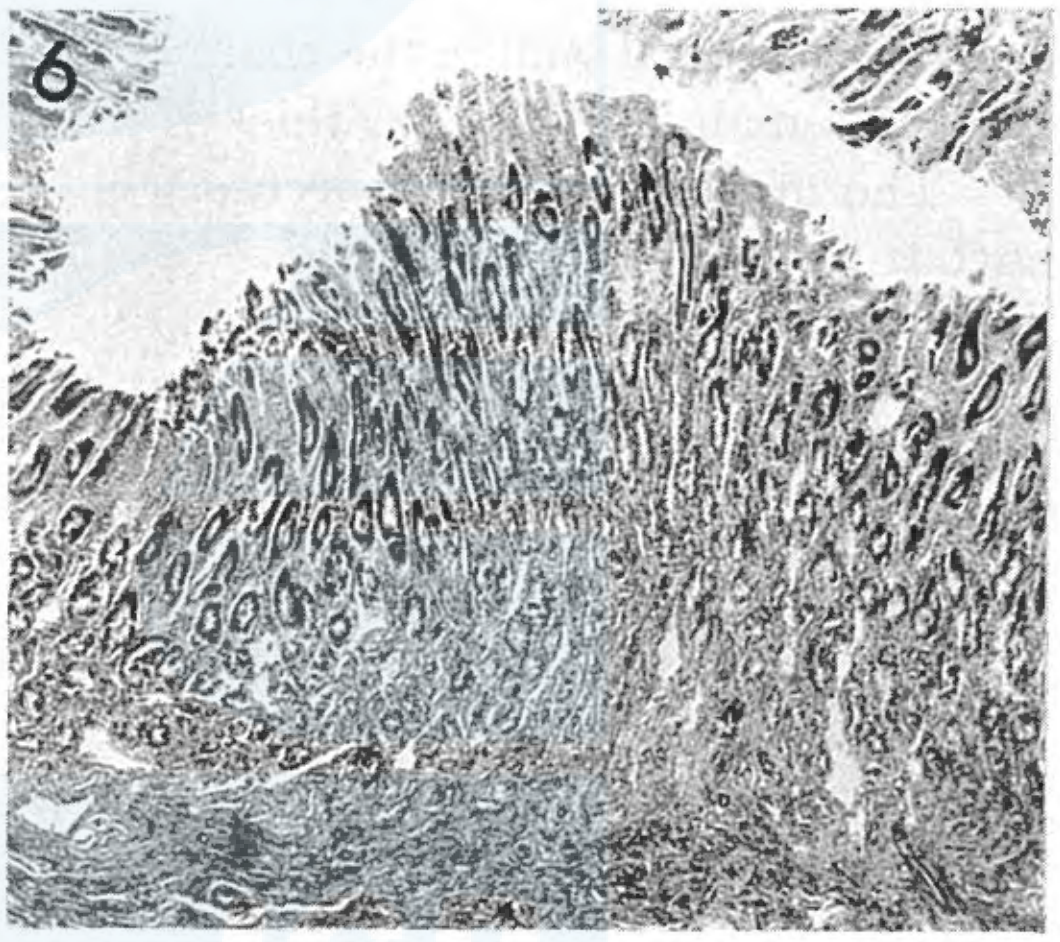

7

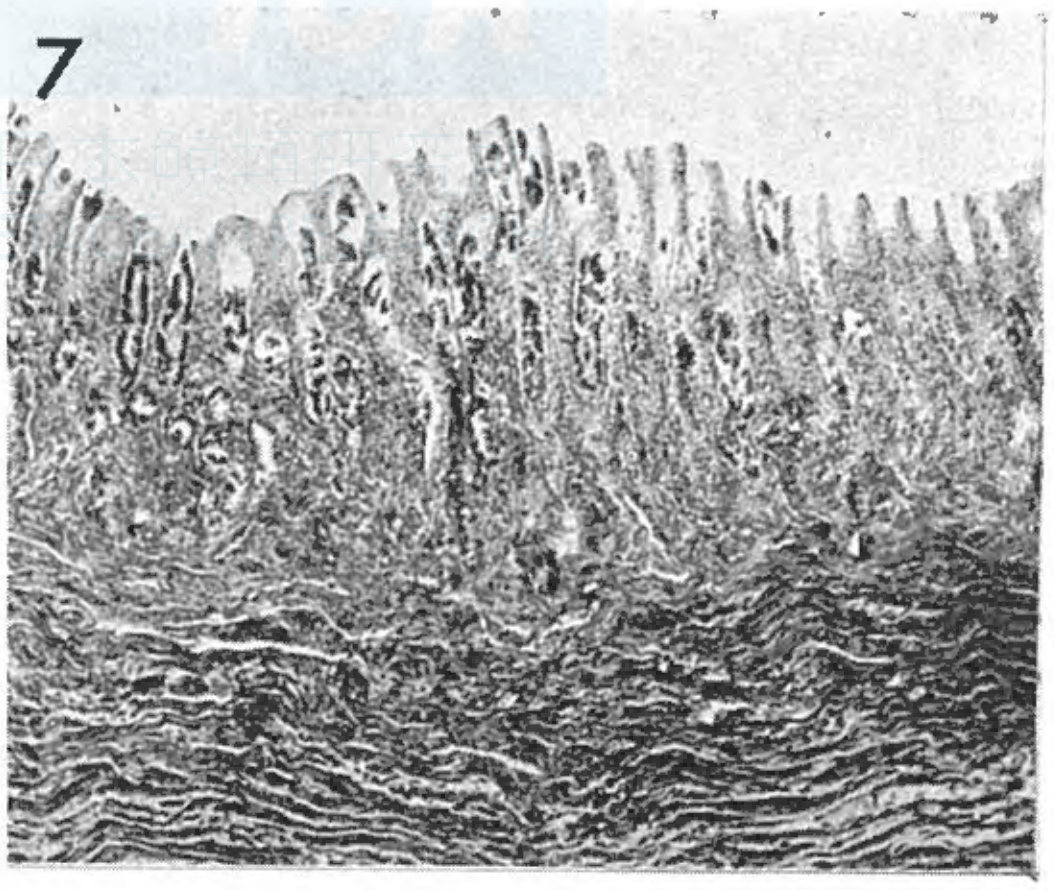

about 2 mm in diameter, lay at the distal end of the pyloric stomach. The opening led into the duodenal ampulla which was about 2.5 cm in diameter (Figs 1 and 2). The wall of the pyloric stomach was approximately 5 mm in thickness. Its inner surface exhibited several folds arranged longitudinally which might be obliterated in the living state.

The histological structure of the pyloric mucosa was fundamentally similar to that of the connecting channel (Fig. 7). The mucosa was about 0.6 mm thick. The lamina propria contained some lymphatic nodules in places. The appearance of the musclaris mucosa, submucosa, and muscularis also resembled those of the connecting channel.

COMPARATIVE CONCLUSIONS AND DISCUSSION

As shown in Figure 8, there are considerable interspecific morphological differences in the stomach of Platanistidae. One notable difference is the presence or absence of the forestomach, which is an esophageal diverticulum existing in most cetaceans and which is sometimes referred to as the first or esophageal stomach. That is, the forestomach exists in *Platanista** (Anderson, 1879; Yamasaki and Takahashi, 1971) and *Inia***, but not in *Pontoporia* (Burmeister, 1867, 1869; Brownell and Ness, 1970; Yamasaki *et al.*, 1974) and *Lipotes* (Hinton and Pycraft, 1922; Chen and Chen, 1975; Zhou *et al.*, 1978, 1979ab).

The esophagus of the *Inia* seems to be more straightly continuous with the main stomach than with the forestomach, and the opening of the forestomach is rather smaller than that of the main stomach. In *Platanista* the esophagus leads to the forestomach and main stomach with roughly the same diameter through the biflucation which Anderson (1879) described as the " common opening ". In the case of sea dolphins (Gihr and Pilleri, 1969; Harrison *et al.*, 1970; Smith, 1972; our observation) the esophagus leads to the forestomach directly. The opening of

←Fig. 3. A photomicrograph of the forestomach wall. Stratified squamous epithelium and the tunica musclaris are thin compared with those of the esophagus. No glands are seen within the forestomach. H-E stain. ×25

←Fig. 4. A photomicrograph of the epithelial transition between the esophagus and the main stomach. Cardiac glands are found at a narrow zone between the esophageal mucosa and the fundic glands. Ee-esophageal epithelium; Cg-cardiac glands; Fg-fundic glands. H-E stain. ×40

←Figs 5, 6 and 7. Same magnification photomicrographs of the mucosa of the main stomach (Fig. 5), the connecting channel (Fig. 6), and the pyloric stomach (Fig. 7). Note the differences in the glandular nature and thickness of each mucosa. H-E stain. ×40

---

* Anderson (1879) and Yamasaki and Takahashi (1971) referred to the forestomach as the " first cavity " and the " first compartment ", respectively.

** We mentioned the presence of the forestomach of the *Inia* in the description of the digestive tract of *Pontoporia* (Yamasaki *et al.*, 1974).

the forestomach from the esophagus, which usually projects rather like a nozzle into the forestomach, is far larger than that of the main stomach. These specific features in *Inia* and *Platanista* suggest that swallowed food may enter the forestomach and main stomach at the same time or the main stomach first, while in sea dolphins swallowed food may enter the forestomach directly.

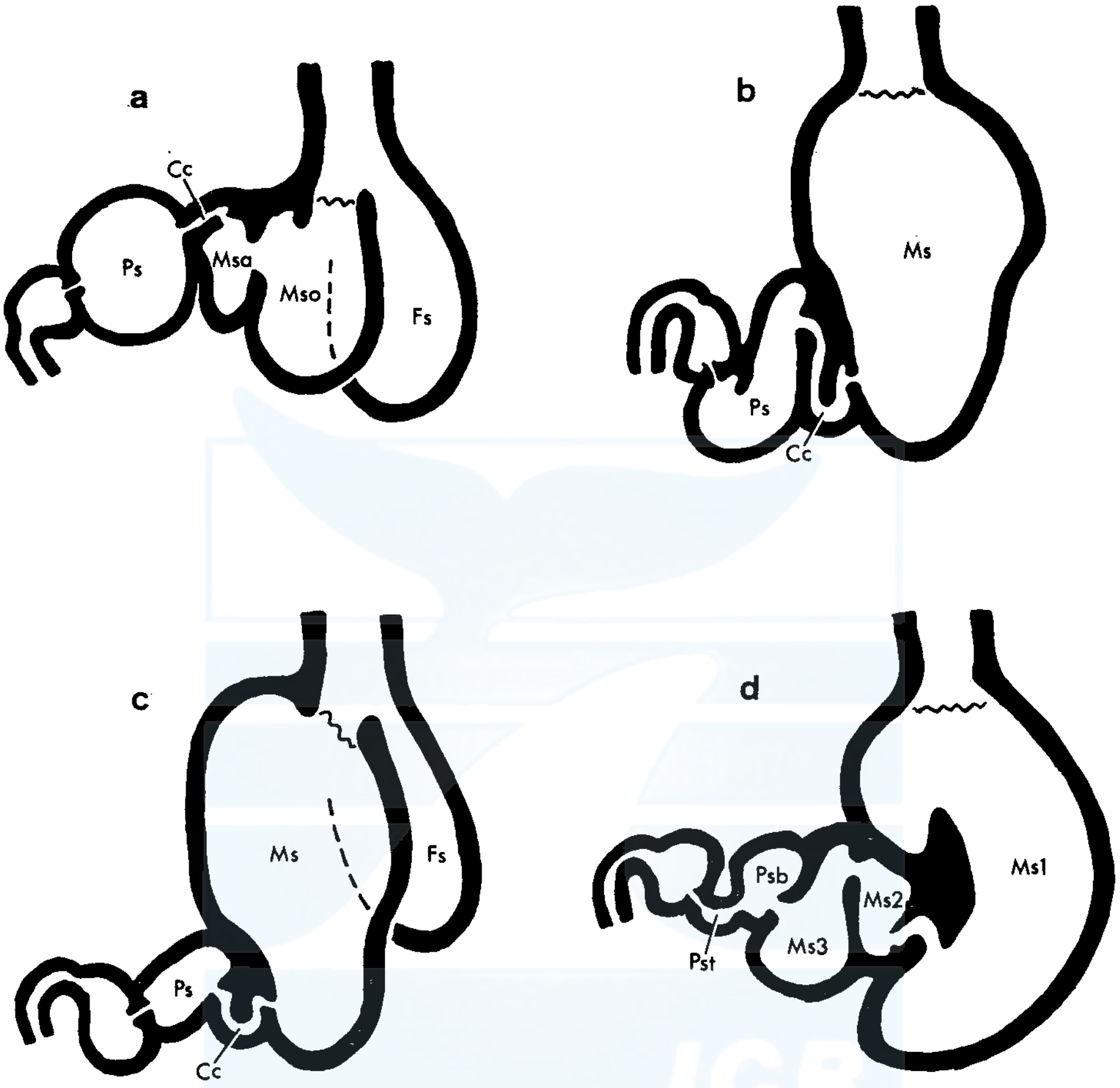

Fig. 8. Diagramatic representation of four stomachs of Platanistidae: a-*Platanista*, b-*Pontoporia*, c-*Inia*, and d-*Lipotes* (modified after Zhou *et al.*, 1979b). Note the relationships of the position, proportion, and communication of each compartment. Fs-forestomach; Ms-main stomach; Mso and Msa-oral and anal parts of the *Platanista* stomach; Ms1, Ms2 and Ms3-first, second and third parts of the *Lipotes* main stomach; Cc-connecting channel; Ps-pyloric stomach; Psb and Pst-bulbous and tubular parts of the *Lipotes* pyloric stomach.

The forestomach of the *Inia* observed was a pear-shaped muscular sac, and was considerably small compared with the main stomach. It was also relatively smaller than that of the *Platanista*. In observed cases of sea dolphins, it has been bigger (Jungklaus, 1898; Gihr and Pilleri, 1969; Harrison *et al.*, 1970; our observation), or smaller (Smith, 1972) than the main stomach. The forestomachs of the observed *Inia* and *Platanista*, however, were relatively small in depth and width when compared with those of sea dolphins.

Harrison *et al.* (1970) suggested that sea dolphins take as many fish as possible when the opportunity arises. The forestomach in adult dolphins is therefore considered to act as a place for the storage and breaking down of foods. In unweaned cetacean calves the forestomach is much smaller than in adults (Slijper, 1962; Smith, 1972), and in Mysticeti, which feed on small plankton, the forestomach is smaller than the main stomach (Slijper, 1962). In addition, *Hyperoodon* and *Ziphius* have no forestomach (Weber, 1886; Slijper, 1962). It is also said that these animals, which feed exclusively on soft food such as squid, could easily dispense with the forestomach. However, comparing the stomachs of the four species of Platanistidae with their food habits, provides some indication that there may be no direct relationship between the presence or absence of the forestomach and food habits, since dolphins having no forestomach are known to not always feed only on soft food*. In addition, since the muscular layer of the forestomach of the *Inia* and *Platanista* seems to be comparatively thinner than that of sea dolphins, it could be said that such a function, storage and breaking down of foods, in the forestomach of the *Inia* and *Platanista* is inferior to that in sea dolphins. According to Smith (1972), it is thought by several investigators that despite the non-glandular nature of the forestomach of sea dolphins some chemical activity takes place there involving gastric juice from the main stomach. If this usually occurs in the cetacean forestomach, it may be assumed that gastric juice may flow far more easily in *Inia* and *Platnista* than in other dolphins.

Hinton and Pycraft (1922) stated that the stomach of *Lipotes* was very primitive in form, the ventriculus (probably indicating the forestomach) being widely confluent with the second compartment (=main stomach) in *Platanista* and other dolphins. Although further developmental studies may be expected to clarify whether this deficiency in the forestomach of *Pontoporia* and *Lipotes* is the result of regression or confluence with the main stomach or is a case of original lack of development, it is of interest to consider the biological meanings that may be attached to this problem of the forestomach of Platanistidae.

The border line between the esophagus and the main stomach is quite clearly indicated by the abrupt change in lining, from stratified squamous epithelium to a glandular mucosa in all species of Platanistidae, while the line of the *Inia* runs almost transversely, or at a right angle to the long axis of the main stomach (Fig. 8c).

As shown in Figure 8, the main stomach of the *Inia* is rather a simple sac, with its shape resembling that of the *Pontoporia*. On the other hand, the main stomach

---

* See for food habits: Burmeister, 1869; Brownell and Ness, 1970; Fitch and Brownell, 1971; Pilleri, 1971; Brownell and Herald, 1971; Pilleri, 1972; Chen and Chen, 1975; Zhou *et al.*, 1977; Chen *et al.*, 1980.

of *Platanista** and *Lipotes*** is divided into two and three parts respectively: the oral and anal compartments in the former (Yamasaki and Takahashi, 1971), and the first, second, and third compartments in the latter (Zhou *et al.*, 1978; Zhou *et al.*, 1979ab). The partitioning of the anal part of the main stomach of the *Lipotes* can be seen to be more complicated than that of the *Platanista*. Although it is difficult to compare the relative sizes of the main stomachs of the species of Platanistidae with one another, in species lacking a forestomach the main stomach seems to be bigger in proportion than that of species having a forestomach. If one includes the anal two compartments as part of the main stomach the volume of the main stomach of the *Lipotes* may be considered to be rather large. This may be a compensation for the absence of the forestomach for the storage of food.

The cardiac glands, which were found for the first time in the cetacean stomach by Hosokawa and Kamiya in 1971 in a blue whale, exist at the narrow zone adjacent to the esophageal mucosa in the *Inia* as well as in *Platanista* (Yamasaki and Takahashi, 1971) and *Pontoporia* (Yamasaki *et al.*, 1974). In a *Lipotes* described by Zhou *et al.* (1978) the cardiac gland zone was more well developed than those in the *Platanista* and *Pontoporia* we reported. Although Smith (1972) stated that no cardiac glands existed in the *Phocoena phocoena*, the glands may usually be found in other cetacean stomachs when all parts of this region are examined. All of the mucosa of the main stomach consist of glands of the same type, except for a narrow zone of cardiac glands. Superficial mucous cells, chief cells, and parietal cells have been detected in gastric epithelium in the *Inia*, *Platanista*, and *Pontoporia* we observed. Mucous neck cells have not been detected in these dolphins, possibly due to post-mortem changes. The numerical ratio of parietal cells to chief cells was approximately 1: 3 or less in all three species observed. This is in good accordance with the results of Harrison *et al.* (1970) and Smith (1972) in several sea dolphins, and of Hosokawa and Kamiya (1971) in baleen whales. It is interesting that this ratio of dolphins living in fresh water is almost the same as that for those living in the sea. Zhou *et al.* (1978; 1979b) found the mucous glands intermingled with fundic glands of the main stomach of the *Lipotes*, and stated that this was a characteristic feature of this dolphin.

The chief functions of the main stomach and forestomach of cetaceans are, respectively, chemical and mechanical digestion. Sand and small stones are often found in the cetacean forestomach and may play some part in mechanical digestion along with the highly muscular wall (Slijper, 1962). In *Lipotes*, dozens of stones, 3 cm in maximum diameter, were reported in the main stomach by Zhou *et al.*

---

* Anderson (1879) and Yamasaki and Takahashi (1971) referred to the main stomach as the " second cavity " and the " second compartment ", respectively. Anderson did not consider the second cavity as two separate chambers.

** Hinton and Pycraft (1922) observed that the stomach of the *Lipotes* was less completely segmented proximally than in most other genera and found that towards the pylorus several small compartments were shut off as usual. Chen and Chen (1975) indicated that the stomach consisted of four chambers, two large proximal compartments separated by a rudimentary septum, and two anal ones communicating by small openings with each other and with the second compartment.

(1977), suggesting the possibility of the employment of stones in mechanical digestion.

The connecting channel of the *Inia* observed was situated in the ventro-dexter region near the caudal end of the main stomach and was rather similar to that of the *Pontoporia* in its location and shape (Figs 8b and 8c). In *Platanista* the channel* is located at the cranio-dexter region of the anal part of the main stomach (Fig. 8a). The entrance of the channel of the *Inia* and *Pontoporia* is located near the caudal end of the main stomach, while in *Platanista* it is found at the cranial wall of the anal compartment of the main stomach. According to Zhou *et al.* (1978; 1979b) no connecting channel exists in *Lipotes* (Fig. 8d). In the case of sea dolphins (*Stenella, Delphinus, Tursiops* observed by Harraison *et al.*, 1970), the connecting channel is located near the cranial end of the main stomach. However, in *Tursiops* shown by Slijper (1962), in *P. phocoena* observed by Smith (1972), and in *Stenella* in our observation the connecting channel was located consistently towards the caudal end of the main stomach. Its entrance was placed nearly at the mid-part of the ventro-dexter wall of the main stomach in our specimen. Although Gihr and Pilleri (1969) did not mention the connecting channel in *Stenella* and *Delphinus*, they observed in their communication two different alternatives between the second and third stomachs (which may correspond to the main stomach and the connecting channel, respectively) in Odontoceti; the opening of the third stomach may be situated in the middle of the second stomach or in a more proximal position. They stated that the junction in the *Stenella styx* was placed well to the proximal end, so that this led to the conclusion that the stomach of this dolphin was highly differentiated. If this conclusion is acceptable, the Platanistidae stomach may be of an undifferentiated type. The connecting channel of Platanistidae is longest in *Pontoporia* (about 8 cm), shortest in *Platanista* (2 cm), and intermediate in *Inia* (4 cm). *Platanista*'s seems to be noticeably shorter than those in sea dolphins. Although the entrance and exit of the channel of the observed Platanistidae became slightly narrow, no marked sphincteric structures or constrictions existed along its course. The channel, except for that in the *Lipotes*, however, at least may as a whole perform a valvular or sphincteric function. In Platanistidae there may be a tendency for a long channel to exist in species having a stomach with a simple main stomach (e.g. *Pontoporia* and *Inia*), and for a short channel (*Platanista*) or the absence (*Lipotes*) of a channel in species with complicated partitions of the main stomach. Septal structures seen in the anal part of the main stomach in *Platanista* and *Lipotes* may have some sphincteric functions. Harrison *et al.* (1970) have made several suggestions on the biological significance of the connecting channel of sea dolphins. Even taking these suggestions into consideration, it is difficult to explain the relationship between the developmental degree and the functions of each kind of channel of Platanistidae. The histological nature of the connecting channel is identical with the pyloric stomach, and is fundamentaly the same in three species of Platanistidae and also in sea dolphins described by former authors (Har-

---

* This was called the " passage " by Anderson (1879) and Yamasaki and Takahashi (1971).

rison *et al.*, 1970; Smith, 1972). The channels of all dolphins should be considered as a part of the pyloric stomach.

Although the pyloric stomach of the *Inia*, which in tubular in shape (Fig. 8c), is situated at the caudo-dexter part of the main stomach is a similar manner to that of the *Pontoporia* (Fig. 8b), it is considerably smaller than that of the *Pontoporia.* While those of the *Platanista** and of *Lipotes*, (Figs 8a and 8d), are globular in shape, that of the latter is rather small, with its anal part becoming a narrow tube (Zhou *et al.*, 1978; Zhou *et al.*, 1979b). The pyloric stomach of sea dolphins (Harrison *et al.*, 1970; Smith, 1972; our observation) is an elongated tubular structure and far bigger than those of Platanistidae. A distinct sphincteric structure exists at the distal end of the pyloric stomach in all species of Platanistidae as well as in other dolphins. In Platanistidae this structure is obviously the one which can be considered as a sphincter of the stomach, which may regulate the neutralization of stomach contents by the backflow of duodenal contents.

When comparing the stomachs of four species of Platanistidae with one another, considerable interspecific differences can be found as mentioned above. The digestive tract distal to the stomach of each species of this family also varies considerably from species to species: for example at the macroscopic level, the whole length of the intestine is 55, 50, 15, and 10 times longer in proportion to body length in *Pontoporia* (Yamasaki *et al.*, 1975), Inia (unpublished), *Lipotes* (Chen and Chen, 1975), and *Platanista* (Takahashi and Yamasaki, 1972), respectively. *Platanista*'s intestine is very unique among Platanistidae; there being a marked caecum as observed in some baleen whales. The structure of the stomach ought to be closely related to that of the whole digestive tract and closely concerned with food habits. It is assumed that the modifications of the digestive tract seen in each species of Platanistidae do not always show a characteristic feature that results from adapting to living only in fresh water, since *Pontoporia* is actually found only in coastal sea water. Although sufficient consideration could not be taken concerning the biological significance of the modifications of the stomach in this study, further morphological observations of the stomach of all species of Platanistidae will be useful to the study of the morphology and function of general cetacean stomachs.

ACKNOWLEDGEMENTS

We wish to thank Dr. T. Tobayama of the Kamogawa Sea World, Chiba, for kindly supplying the *Inia* stomach for this study.

REFERENCES

ANDERSON, J., 1879. *Anatomical and zoological researches: comprising on account of the zoological results of the two expeditions to Western Yunnan 1868 and 1875; and a monograph of the two cetacean genera, Platanista and Orcella. 2 vols. B. Quaritch, London.*

---

* This was called the "third gastric cavity" and the "third compartment" by Anderson (1879) and Yamasaki and Takahashi (1971), respectively.

BROWNELL, R. L. JR. and R. NESS, 1970. Preliminary notes on the biology of the Franciscana, *Pontoporia blainvillei* (Cetacea: Platanistidae). *Proc. for Sixth Anual Conf. on Biol. Sonar and Diving Mammals*, pp. 23–28.

BROWNELL, R. L. JR. and E. S. HERALD, 1972. *Lipotes vexillifer. Mammalian sp.*, 10: 1–4.

BURMEISTER, H., 1867. Preliminary observation on the anatomy of *Pontoporia bleinvillii. Proc. Zool. Soc. Lond.*, pp. 484–489.

BURMEISTER, H., 1869. *Pontoporia blainvillii* Gray. *In: Descripción de cuatro especies de delfinides de la costa Argentina en el Oceano Atlántico. Anal. Mus. Público Buenos Aires*, 1: 384–445.

CHEN, I. and W. CHEN, 1975. Notes on some morphological and anatomical features of the white-flag dolphin, *Lipotes vexillifer. Acta Hydrobiol. Sinica*, 5: 360–368. (in Chinese with English summary).

CHEN, P., P. LIU, R. LIU, K. LIN and G. PILLERI, 1980. The distribution, ecology, behavior and protection of the dolphins in the middle reach of Chang Jiang River (Wuhan-Yueyang). *Oceanologia et Limnologia Sinica*, 11: 73–84. (in Chinese with English summary).

FITCH, J. E. and R. L. BROWNELL, JR., 1971. Food habits of the Franciscana, *Pontoporia blainvillei* (Cetacea: Platanistidae) from South America. *Bull. Marine Sci.*, 21: 626–636.

GIHR, M. and G. PILLERI, 1969. On the anatomy and biometry of *Stenella styx* Gray and *Delphinus delphis* L. (Cetacea, Delphinidae) of the Western Mediterranean. *In: Investigation on cetacea* (Berne), 1: 15–65. ed. by G. Pilleri, Berne.

HARRISON, R. J., F. R. JOHNSON and B. A. YOUNG, 1970. The oesophagus and stomach of dolphins (Trsiops, Delphinus, Stenella). *J. Zool. Lond.*, 160: 377–390.

HINTON, M.A.C. and W. P. PYCRAFT, 1922. Preliminary note on the affinities of the genus Lipotes. *Annals and Magagine of Natural History Lond.*, (Ser. IX) 10: 232–234.

HOSOKAWA, H. and T. KÁMIYA, 1971. Some observations on the cetacean stomachs, with special considerations on the feeding habits of whales. *Sci. Rep. whales Res. Inst.*, 23: 91–101.

JUNGKLAUS, F., 1898. Der Magen der Cetaceen. *Jena Z. F. Naturriss.*, 32: 1–94. (cited from Gihr and Pilleri, 1969).

PILLERI, G., 1971. On the La Plata dolphin, *Pontoporia blainvillei* off the Uruguayan coasts. *In: Investigation on cetacea*, (Berne), 3: 59–68.

PILLERI, G., 1972. *Poppiana argentinianus* Rathbuen, 1906 (Crustacea, Decapoda) in the Stomach contents of *Inia geoffrensis* from the Rio Ibaré, Bolivia. *In: Investigation on cetacea* (Berne) 4: 104.

SLIJPER, E. J., 1962. Whales. Hutchinson, London.

SMITH, G.J.D., 1972. The stomach of the harbor porpoise *Phocoena phocoena* (L). *Can. J. Zool.*, 50: 1611–1616.

TAKAHASHI, K. and F. YAMASAKI, 1972. Digestive tract of Ganges dolphin, *Platanista gangetica*. II. small and large intestines. *Okajimas Fol. anat. jap.*, 48: 427–452.

WEBER, M., 1886. *Vergleichung des Magens mit dem anderer Säugethiere. In: Studien über Säugethiere. Ein Beitrag zur Frage nach dem Ursprung der Cetaceen*, pp. 54–66. *Gustav Fisher. Jena.*

YAMASAKI, F. and K. TAKAHASHI, 1971. Digestive tract of Ganges dolphin, *Platanista gangetica*. I. oesophagus and stomach. *Okajimas Fol. anat. jap.*, 48: 271–293.

YAMASAKI, F., K. TAKAHASHI and T. KAMIYA, 1974. Digestive tract of La Plata dolphin, *Pontoporia blainvillei*. I. oesophagus and stomach. *Okajimas Fol. anat. jap.*, 51: 29–52.

YAMASAKI, F., K. TAKAHASHI and T. KAMIYA, 1975. Digestive tract of La Plata dolphin, *Pontoporia blainvillei*. II. small and large intestines. *Okajimas Fol. anat. jap.*, 52: 1–26.

ZHOU, K., W. QIAN and Y. LI, 1977. Studies on the distribution of Baiji, *Lipotes verxillifer* Miller. *Acta Zool. Sinica*, 23: 72–79. (in Chinese with English summary).

ZHOU. K., W. QIAN and Y. LI, 1978. Recent advances in the study of the Baiji, *Lipotes vexillifer. Acta Nanjing Normal Coll.*, 1: 8–13. (in Chinese with English summary).

ZHOU. K., W. QIAN and Y. LI, 1979a. The osteology and the systematic position of the Baiji, *Lipotes vexillifer. Acta Zool. Sinica*, 25: 58–74. (in Chinese with English summary).

ZHOU. K., Y. LI and W. QIAN, 1979b. The stomach of the Baiji, *Lipotes vexillifer. Acta Zool. Sinica*, 25: 95–100. (in Chinese with English summary).