BRAIN MORPHOGENESIS IN *STENELLA COERULEOALBA*

TOSHIRO KAMIYA

Department of Anatomy, Faculty of Medicine, University of Tokyo, Tokyo

PAUL PIRLOT

Département des Sciences Biologiques, Université de Montréal, Montréal

ABSTRACT

Based on a series of 15 embryos and two new-born spcimens of *Stenella coeruleoalba*, a description of the changes in shape of the brain as size increases is given. Such changes involve strong brachycephalization and proliferation of transverse gyri. A temporary fetal pattern of the cortex in this species reminds one of a permanent adult condition in more primitive dolphins. The prominent development of vestibulocochlear nerve and the temporal region is also emphasized.

INTRODUCTION

One of the fundamental problems involved in any attempt at understanding the biology of animals is that of the relations between structures and functions, that is between morphology and physiology. Part of the treatment of that problem is an investigation of the ontogeny of brain structures, which is necessarily related to the emergence of brain functions. This points to the value of studying ontogenetic series i.e. embryonic and young animals.

The present paper is concerned with the gradual growth and differentiation of the brain in a dolphin, that is with its morphogenesis. The complexity of that problem is well known. The study of the vertebrate brain raises particular and intricate question concerning the relation between size and shape in the course of specific ontogenesis (see a review by Gould, 1966). We would like to contribute to the discussion with observations on a good series of brains from fetal dolphins. Both the size and the structural complexity of the brain in these animals make it a particularly favourable material; further, the well known high encephalization and corticalization of dolphins, as well as the sophistication of their sensory system (sonar) render such a study especially interesting. Kamiya (1962) and Hosokawa *et al.* (1969) have studied the embryonic development of the acoustic system with the myelinization method in *Stenella coeruleoalba*.

MATERIAL AND METHOD

The dolphin species dealt with here is *Stenella coeruleoalba*. Fifteen embryos ranging in size from 3.6 to 74.0 cm in body-length and two postnatal young (115.5 and 135.0 cm long respectively) were used. This selection of specimens was made from

Sci. Rep. Whales Res. Inst.,
No. 26, 1974, 245–253

a series of 67 individuals (48 prenatal and 19 postnatal) which is being used for another growth study (Pirlot and Kamiya, in preparation). All that material was collected by Kamiya from Kawana and Futo, Shizuoka Prefecture (Table 1).

The principle of this study is to compare the prenatal brains with the postnatal ones and also to compare the prenatal brains with each other. The brains were examined from four distinct aspects: in lateral view (norma lateralis), in sagittal section (norma media), in dorsal view (norma verticalis) and in ventral view (norma basalis). A series of photographs were taken for each aspect and will be commented upon below. In order to make the visual study as easy as possible, we used the full area of the photograph in each case. Thus the brains are not shown to scale. The real size, however, can be estimated readily from the small scale provided with each picture. The dissecting work was done by Kamiya and the photographs also taken by him on 35 mm film with a 55 mm Takuma 1: 2 lens or a 100 mm Takuma 1: 4 lens mounted on a bellow attachment with Asahi body.

TABLE 1. MATERIAL.

Body length (cm)	Sex	Body weight (g)	Brain weight (g)
3.6		3.4	0.2
6.0		7.0	0.4
7.5		11.0	0.8
10.4		26.8	1.6
19.0		115.0	5.6
24.0	F	300.0	15.0
26.0	F	362.0	18.0
31.0	M	460.0	21.0
32.0	M	500.0	25.0
35.0	F	640.0	32.0
38.4	M	870.0	37.0
42.0	F	930.0	51.0
42.5	M	1220.0	58.0
51.0	F	1780.0	110.0
74.0	F	4020.0	228.0
115.5	F	19450.0	680.0
135.0	M	—	740.0

RESULTS

The description follows the order of the four distinct aspects as defined above, with a preliminary note on the postnatal brain.

Postnatal brain. It is convenient to start with a rapid examination of the postnatal brain of the 135.0 cm specimen (Plate I, 1). The caudad expansion of the hemisphere is striking; in fact, the cerebellum is almost invisible from above because it is covered by the telencephalon. Another impressive characteristic is the relative cephalo-caudal shortness or the relative great transverse width of the entire brain (brachycephaly). The complex cortical folding resulting in numerous gyri can be appreciated. It will be noted that no major sulci, either in a longitudinal or transverse direction, exist. In norma basalis (Plate I, 2), the bulging of the temporal cortex is especially noticeable as well as the large size of the cerebellum. One must also note the enormous vestibulocochlear nerve as well as the large trigeminal and optic nerves. In norma lateralis (Plate I, 3), the multiplicity of the gyri is also quite striking and the presence of a Sylvian fissure can be pointed to. This must be compared with *Platanista gangetica* (Plate IV, 3) and also with the pictures in Pilleri and Gihr (1970, Plate 7) for *Tursiops truncatus*, and also in Gruenberger, (1970, Fig. 5) for *Inia geoffrensis* as well as in Pilleri (1972, Plate 4) for *Platanista* again. One important feature that we shall have to comment upon later is the absence in *Stenella* of the cephalo-caudally oriented and longitudinal sulci that are typical for *Platanista* (Pilleri, 1972, Plate 1). The suprasylvian and ectosylvian fissures are but slightly visible in our specimen; they seem to be somewhat clearer in *Inia* (Gruenberger, 1970, Fig. 6) and in *Pontoporia blainvillei* (Pilleri, 1972, Plate 15, 3). On the other hand, the fan-shaped arrangement of the gyri, frontward and upward from the Sylvian fissure, is striking in *Stenella*, much more so than in *Inia* (Gruenberger, 1970, Fig. 6). In norma media, the relatively strong antero-ventral development of the hemisphere is noticeable. The genu of the corpus callosum accordingly reaches fairly far forward and downward. Well marked are the mesencephalon roof (corpora quadrigemina) and the pontine transverse formation. The colliculi inferiores, however, appear to be relatively smaller than in *Tursiops* (Pilleri and Gihr, 1970, Plate 3) and *Platanista* (Pilleri, 1972, Fig. 10), if, as it seems, all those sections are really comparable (sagittal). A great difference between those species is the relatively poor distinctness of the gyrus cinguli in *Stenella*, whereas this is so clear in *Platanista* and in *Pontoporia* (Pilleri, 1972, Fig. 5 and Plate 5, 10) as well as in *Inia* (Gruenberger, 1970, Fig. 7).

All those features, briefly described for *Stenella* in comparison with other dolphins, especially Platanistidae, will be reconsidered hereafter in the ontogenetic sequence of prenatal and young postnatal specimens.

Norma lateralis in ontogeny (Plates II, III, IV). The first three figures of Plate II refer to the same specimen. They firstly show the embryo before dissection (Fig. 1), with the two humps made by the bulging telencephalon and mesencephalon. In Fig. 2, one sees the dissection in progress, with the above named parts of the brain still *in situ*. The mesencephalic and cervical flexures are quite clear, and the pontine flexure on the dorsal side as well. For the sake of comparison, it may be mentioned that these three flexures are already present in a 6.7 mm human embryo (about 34 days) according to Hamilton, Boyd and Mossman (Fig. 153). Figure 3 presents the same brain after dissection. A comparison of Figs. 3, 4 and 6 reveals immediately the attenuation of the coiled, elongate and almost tubular aspect of the total brain as well as the relative increase of the telencephalon. The overall shape becomes bulkier, the parts (telencephalon, mesencephalon, rhombencephalon) begin to telescope into each other. On Plate III, Fig. 1, the apparent dilatation of the hemisphere increases. Between stages of Figs. 1 and 2 of Plate III, the morphogenesis progresses considerably from a qualitative viewpoint in particular: this is remarkable since the total size increase between the two stages is about 37% whereas it was over 80% between the two preceeding stages (Plate II, Fig. 6 and Plate III, Fig. 1) with less morphological differentiation. In this important step (Figs. 1 and 2 of Plate III), the surfaces of the hemispheres and of the cerebellum begin to differentiate while their size increases. The mesencephalic roof sinks and disappears beneath the overhanging cortex in lateral view. A Sylvian fissure begins to appear. Figuers 4 to 6 show the formation of the gyri. From 3 through 6, their fan-shaped arrangement above the Sylvian fissure becomes more marked. The coiled aspect of the gyri is predominent from stage 5 of this plate. A certain longitudinal orientation of the first groves may be seen temporarily in Figures 3 and 4 but this is temporary. On Plate IV, Fig. 1, we have a view of the brain shortly before birth while Figure 2 represents the brain shortly after birth. The question of size set apart, the general aspect is very much similar in both specimens. The gyri, however, are more tightly packed in the postnatal specimen than in the other one. Contrasting with our postnatal example, one can notice the longitudinal (cephalo-caudal) orientation of the gyri in the brain of *Platanista*, Plate IV, 3. The radial arrangement as seen in *Stenella* practicially does not exist in the platanistids.

Norma media in ontogeny (Plate V). We present on Plate V six sagittal sections of fetal brains of *Stenella*, from 24 to 51 cm, that is through stages corresponding roughly to those of Plate III. The gradual formation of the corpus callosum can be observed as well as the begining and complexification of the gyri on the medial surface. One can appreciate the relative morphic stability of the brain-stem portion: there is little change of shape in it. The relative size of the mesencephalic bulge (colliculi) decreases from section 1 to section 6. The fissura splenialis is well marked but the fissura genui much less so and the fissura suprasplenialis also is quite faint. In the early postnatal (Plate I, 4), the same fissurae are also difficult to trace, except for the caudal half of the splenial fissure, contrarily to what can be observed in the platanistids brains shown by Pilleri (1972).

Norma verticalis in ontogeny (Plates VI, VII). Both the change in relative size of parts and the change in shape can be fully appreciated from the fetal series seen in dorsal view. This sequence (12 specimens) is particularly striking.

It starts with the predominence of the mesencephalon, which makes, with the medulla oblongata, the main mass of the very early Mammalian brain, as shown quantitatively by Pirlot and Bernier (in press). The lateral hemispheric lobes are still quite small in Fig. 1 while the cerebellum is no more than an annular thickening. Stages in Figs. 2 to 5 are characterized by the relative decrease of the caudal half of the brain and the rapid increase of the hemispheres. The colliculi begin to shape up clearly in Fig. 2. It will be noticed that, for a time, the cerebellum remains almost unchanged in outline, a fact observed in bats by Pirlot and Bernier (in press). The rapid and profound modification of the brain surface between sizes 19 and 26 cm, already observed in the norma lateralis aspect, is also very striking in dorsal view. It is important to note the longitudinal (cephalo-caudal) orientation of the sulci that appears in Figs. 6 and 7 of Plate VI. The first one seems to be the fissura lateralis (fissura marginalis) (Fig. 6) while the fissura endolateralis begins to be visible on Fig. 7. Both are better marked at the 35 cm stage (Plate VII, 1) but they become somewhat less distinct soon after (38 and 51 cm, Plate VII, 2 and 3). In fact, that is due to the rapid complexification of the gyri system in all directions: among those gyri, the first fissures become less conspicuous. The foliation of the cerebellum is well under way from 26 cm (Plate VI, 6). The sequence 26 to 74 cm corresponds to a marked and rapid increase in both mass and suprficial area. That period must be one of very active histological proliferation all over the surface of the brain. In Plate VII, 5, the anterior cerebral artery is visible in the fissure lateralis (left side of the picture with arachnoid membrane). Finally, another striking feature that can be observed in the photographs (although these are not to scale) is the fast change in the width/length ratio. This ratio passes roughly from 58% at 3.6 cm to 82% at 10.4 cm, practically 100% at 19 cm, 114% at 31 cm, 133% at 74 cm i.e. shortly before birth and also soon after (115.5 cm). This of course simply reflects the change from an elongate outline to a rather telescoped shape which occurs in all developing Mammals but the modification is particularly strong in this dolphin.

Norma basalis in ontogeny (Plates VIII, IX). As seen from the ventral aspect, the morphogenesis of the brain is mainly characterized by a gradual differentiation of distinct regions and thus a general structural complexification. In the first four stages shown here (Plate VIII, 1 to 4), the main masses, that is prosencephalic and rhombencephalic, are visible, at first deeply then later shallowly separated by the mesencephalic flexure. The lateral lobes and the cerebellum, however, begin to shape up in Fig. 4 (10.4 cm). Thereafter, the differentiation is fast: the modelling of the whole undersurface progresses rapidly while the hypothalamic and pontine regions begin to show theire spective specific structures (Plate VIII, 5 to 7; Plate IX, 1 and 2). The hypophyseal mass is early visible in this series. The cranial nerves posterior to the optic appear as early as stage 19.0 cm (Plate VIII, 5). The trigeminal is first visible but the facial-acoustic-vestibular complex takes shape as a large double root a little afterward and is clearly visible at 35.0 cm (Plate IX, 1). Nervus vagus (X), nervus accessorius (XI) and nervus hypoglossus (XII) intermingled and nervus abducens (VI) are also formed in the 51 cm fetus. Nervus oculomotorius (III) is visible at 115.5 cm but was probably lost in the dissection of smaller embryos. The inferior olive starts bulging from the 19.0 cm stage and is quite distinctly individualized at stage 42.0 cm or even before.

CONCLUSION

From the above study of a series of prenatal and early postnatal brains of *Stenella coeruleoalba*, we can draw the following conclusions.

a) **General morphogenesis.** The changes in shape, as size increases, are very striking, in the sequence under consideration. The brain of this species starts its development with elongate outlines as is the case in all Mammals. But the modification is much more pronounced than in most other Mammals, in the sense that the final stage of embryonic life shows an exceptionally broad and short brain. A detailed quantitative analysis of the components' growth could give a satisfactory account of what really occurs from that viewpoint during that remarkable ontogeny; we have such an analysis in preparation.

b) **Cortical morphogenesis** Gross anatomical observations of the cerebral lobes reveal interesting features. Dolphins are probably amont the most strongly gyrencephalic Mammals outside the Primates. But, in this respect, they are not uniform. In the adult stage, the genus *Stenella* differs markedly from some Platanistid genera with which we were able to compare it on the basis of other material as well as of published reports and pictures. Indeed, *Stenella* is characterized by the predominence of transverse (in the broadest sense) or at least not longitunidally oriented gyri and sulci. Its superficial cortical pattern is extremely complicated with a large number of oblique sulci. But, in young embryos, longitudinal groves are the first ones to appear, as we have shown. They become more or less blurred or obliterated later as the adult pattern gradually sets in. This raises the recurrent question of repetitive processes in ontogeny. The platanistids show an obviously longitudinal orientation of the gyri and, further, platanistids are considered, on various grounds, a primitive group among dolphins. Our observations thus raise a fundamental problem in ontogeny with respect to phylogeny and evolution in general: are the temporary longitudinal sulci in *Stenella* a case of ontogenetic repetition? Only a new investigation along this line on the morphogenesis of dolphin brain can throw some light on that problem.

c) **Morphogenesis in relation to sensory functions.** The relationships between the rate of development of the sensory control centers in fetal life and the start of sensory activities are a very intricate problem. We will not venture into discussing its implications in the case of *Stenella*, but we must nevertheless insist upon the importance of the two following observed facts. Firstly, we have stressed the enormous size of the vestibulocochlear nerve (VIII) and, at the same time, the relatively great development of the temporal region in *Stenella*, both becoming obvious as growth proceeds. The possible correlation between an extensive use of hearing abilities, including sonar, and the development of the temporal cortical area remains mysterious, as far as we know. But whatever the results of researches on that point may be, our observations are of interest. Secondly, we would like to point to the total absence of an olfactory bulb in the rostro-ventral region of the brain in *Stenella* as seen in gross morphological aspects.

APPENDIX

Embryos smaller than 3.6 cm were too small to permit dissection and photography of the brain in gross morphological view. Approximately sagittal sections, however, could be prepared for some of them as shown on Plate X. It is probably easier to look at them in a decreasing size order.

In all embryos, the neurocoele is still quite large as can be expected. In Fig. 4, the spinal cord is visible over most of its length and the cervical flexure at the fourth ventricle level is strongly marked. The ventral portion of the neural tube is thick, especially in the pons-oblongata region, while its roof remains thin except where the cerebellum is forming. A thalamic mass has been cut parasagitally and the mesencephalic flexure is well marked. The third ventricle is still wide and the parasagittal section also cuts a large lateral ventricle. The blow-hole is visible dorsally to the snout and mouth.

Figure 3 presents a much younger stage (about 2/3 of the former in length). It is not quite so well centered but it shows about the same features as figure 4 in a less advanced state. The blow-hole can be seen again and the flexures are marked. Figures 2 and 1 are definitely different in aspect. While the membranous roof of the fourth ventricle is showing the concavity that will correspond to the pontine and cervical flexures, the more rostral structures do not show yet the various parts very distinctly. The common neurocoele just begins to divide into distinct cavities. In Fig. 1, the general tube-like appearance can be noted, the forming brain overhanging indistinct notochordal tissue.

ACKNOWLEDGEMENTS

We wish to express our gratitude to the Ministry of Education of Japan for financing the collection and study of the dolphin with a grant to the first author, and to the Japan Society for the Promotion of Science for a Visiting Professorship at the University of Tokyo to the second author. Thanks are also due to Mr. N. Miyazaki of the Ocean Research Institute, University of Tokyo for his help in collecting the material and to Dr. John Nelson, Monash University, Australia, for checking the English text.

REFERENCES

GOULD, S. J., 1966. Allometry and size in ontogeny and phylogeny. *Biol. Rev.*, 41: 587–640.

GRUENBERGER, H. B., 1970. On the cerebral anatomy of the Amazon dolphin *Inia geoffrensis*. *Investigations on Cetacea*, 2: 129–144.

HAMILTON, W. J., J. D. BOYD and H. W. MOSSMAN, 1972. *Human embryology*. Heffer, Cambridge, 646 pp.

HOSOKAWA, H., 1955. Cross-section of a 12 mm dolphin embryo. *Sci. Rep. Whales Res. Inst.*, 10: 1–68.

HOSOKAWA, H., S. IGARASHI, T. KAMIYA, and K. HIROSAWA, 1969. Morphological characteristics and myelinization of acoustic system in the dolphins (*Stenella caeruleoalba*). *Sci. Rep. Whales Res. Inst.*, 21: 95–123.

KAMIYA, T., 1962. The acoustic system and the behavior in the dolphin. *Rep. Res. Minist. Educ. Agr.* (II) 1962: 111–112. (in Japanese)

PILLERI, G., 1972. The cerebral anatomy of the Platanistidae (*Platanista gangetica, Platanista indi, Pontoporia blainvillei, Inia geoffrensis*). *Investigations on Cetacea*, 4: 44–70.

PILLERI, G. and M. GIHR, 1970. The central nervous system of the Mysticete and Odontocete whales. *Investigations on Cetacea*, 2: 89–127.

PIRLOT, P. and R. BERNIER, (in press). Embryonic brain growth in a fruit-bat.

EXPLANATION OF PLATES

PLATE I

External form of the brain with arachinoid. Male, 135 cm long.
Fig. 1. Dorsal view.
Fig. 2. Ventral view.
Fig. 3. Laterial view of the left half.
Fig. 4. Medial surface of the right half.
II: Optic nerve V: Trigeminal nerve VIII: Vestibulocochlear nerve

PLATE II

External form of the embryo and brain.
Fig. 1. Photograph of the left side of 3.6 cm long embryo.
Fig. 2. Same embryo with cranial bone removed and brain shown *in situ*.
Fig. 3. External form, left half of the brain of 3.6 cm long embryo.
Fig. 4. Embryo, 6.0 cm long.
Fig. 5. Embryo, 7.5 cm long.
Fig. 6. Embryo, 10.4 cm long.

PLATE III

External form of the left half of the brain.
Fig. 1. Embryo, 19.0 cm long.
Fig. 2. Embryo, 26.0 cm long.
Fig. 3. Embryo, 32.0 cm long.
Fig. 4. Embryo, 35.0 cm long.
Fig. 5. Embryo, 38.4 cm long.
Fig. 6. Embryo, 51.0 cm long.

PLATE IV

External form of the left half of the brain.
Fig. 1. Embryo, 74.0 cm long, with arachnoid.
Fig. 2. Female, 115.5 cm long.
Fig. 3. *Platanista gangetica*, male, 117 cm long.

PLATE V

Median section of the right half of the brain.
Fig. 1. Embryo, 24.0 cm long.
Fig. 2. Embryo, 26.0 cm long.
Fig. 3. Embryo, 32.0 cm long.
Fig. 4. Embryo, 35.0 cm long.
Fig. 5. Embryo, 42.5 cm long.
Fig. 6. Embryo, 51.0 cm long.
Figs. 2, 4 and 5 with midbrain removed and showing gyrus.

PLATE VI

External form of the brain in dorsal view.
Fig. 1. Embryo, 3.6 cm long.
Fig. 2. Embryo, 6.0 cm long.
Fig. 3. Embryo, 7.5 cm long.
Fig. 4. Embryo, 10.4 cm long.
Fig. 5. Embryo, 19.0 cm long.
Fig. 6. Embryo, 26.0 cm long.
Fig. 7. Embryo, 31.0 cm long.

PLATE VII

External form of the brain in dorsal view.
Fig. 1. Embryo, 35.0 cm long.
Fig. 2. Embryo, 38.4 cm long, left hemisphere with arachnoid.
Fig. 3. Embryo, 51.0 cm long.
Fig. 4. Embryo, 74.0 cm long, with arachnoid.
Fig. 5. Female, 115.5 cm long, left hemisphere with arachnoid and arrow show anterior cerebral artery.

PLATE VIII

External form of the brain in ventral view.
Fig. 1. Embryo, 3.6 cm long.
Fig. 2. Embryo, 6.0 cm long.
Fig. 3. Embryo, 7.5 cm long.
Fig. 4. Embryo, 10.4 cm long.
Fig. 5. Embryo, 19.0 cm long.
Fig. 6. Embryo, 24.0 cm long.
Fig. 7. Embryo, 26.0 cm long, right hemisphere with arachnoid.

PLATE IX

External form of the brain in ventral view.
Fig. 1. Embryo, 35.0 cm long.
Fig. 2. Embryo, 42.0 cm long, right hemisphere with arachinoid.
Fig. 3. Embryo, 51.0 cm long.
Fig. 4. Embryo, 74.0 cm long, hemisphere with arachinoid.
Fig. 5. Female, 115.5 cm long, right hemisphere with arachinoid.
P: Pons O: Olive C: Crus cerebrum VII: Facial nerve.
VIII: Vestibulocochlear nerve.

PLATE X

Longitudinal median sections of embryos.
Fig. 1. Embryo, 1.1 cm long.
Fig. 2. Embryo, 1.7 cm long.
Fig. 3. Embryo, 2.4 cm long.
Fig. 4. Embryo, 3.5 cm long.

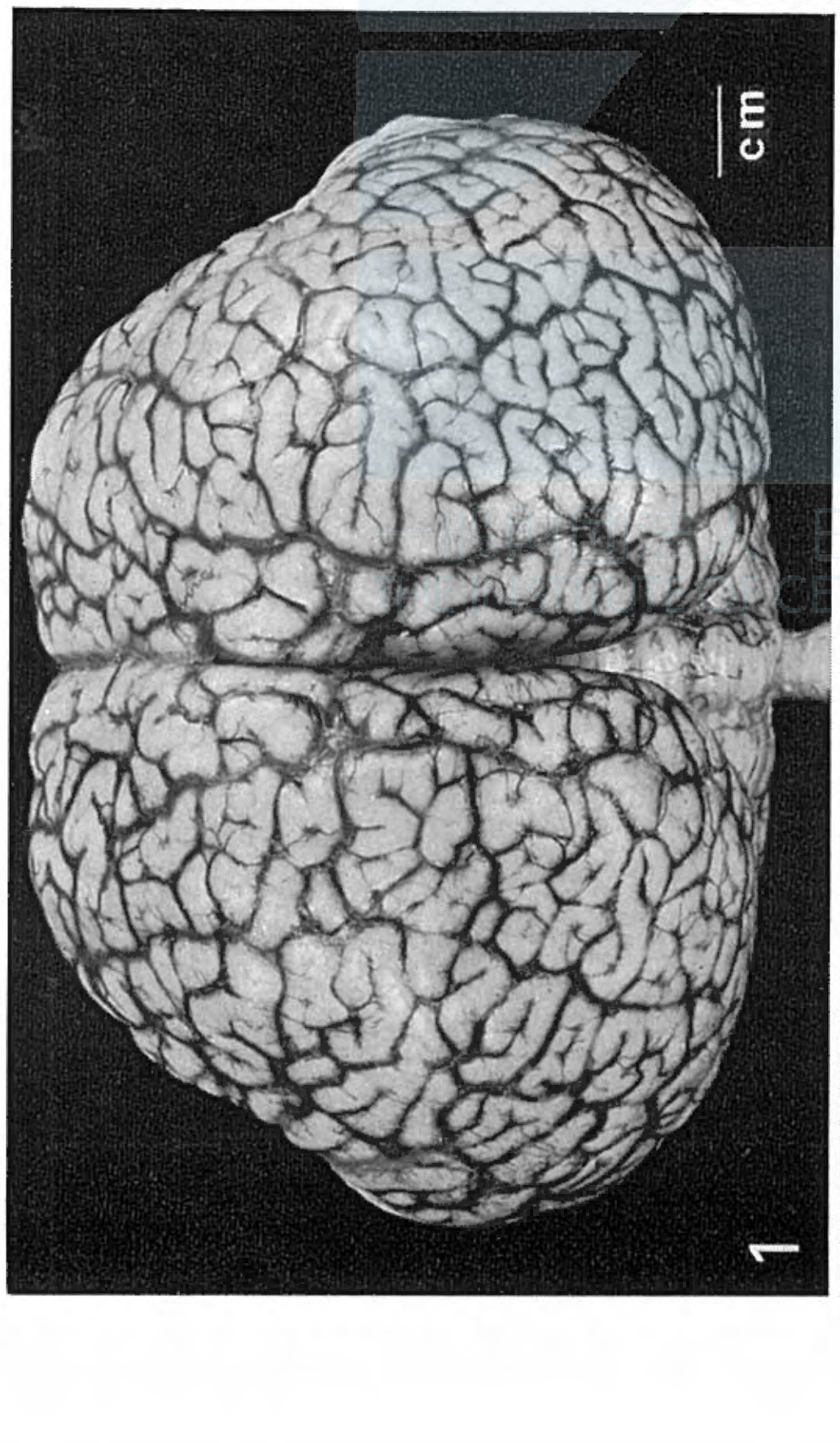
1

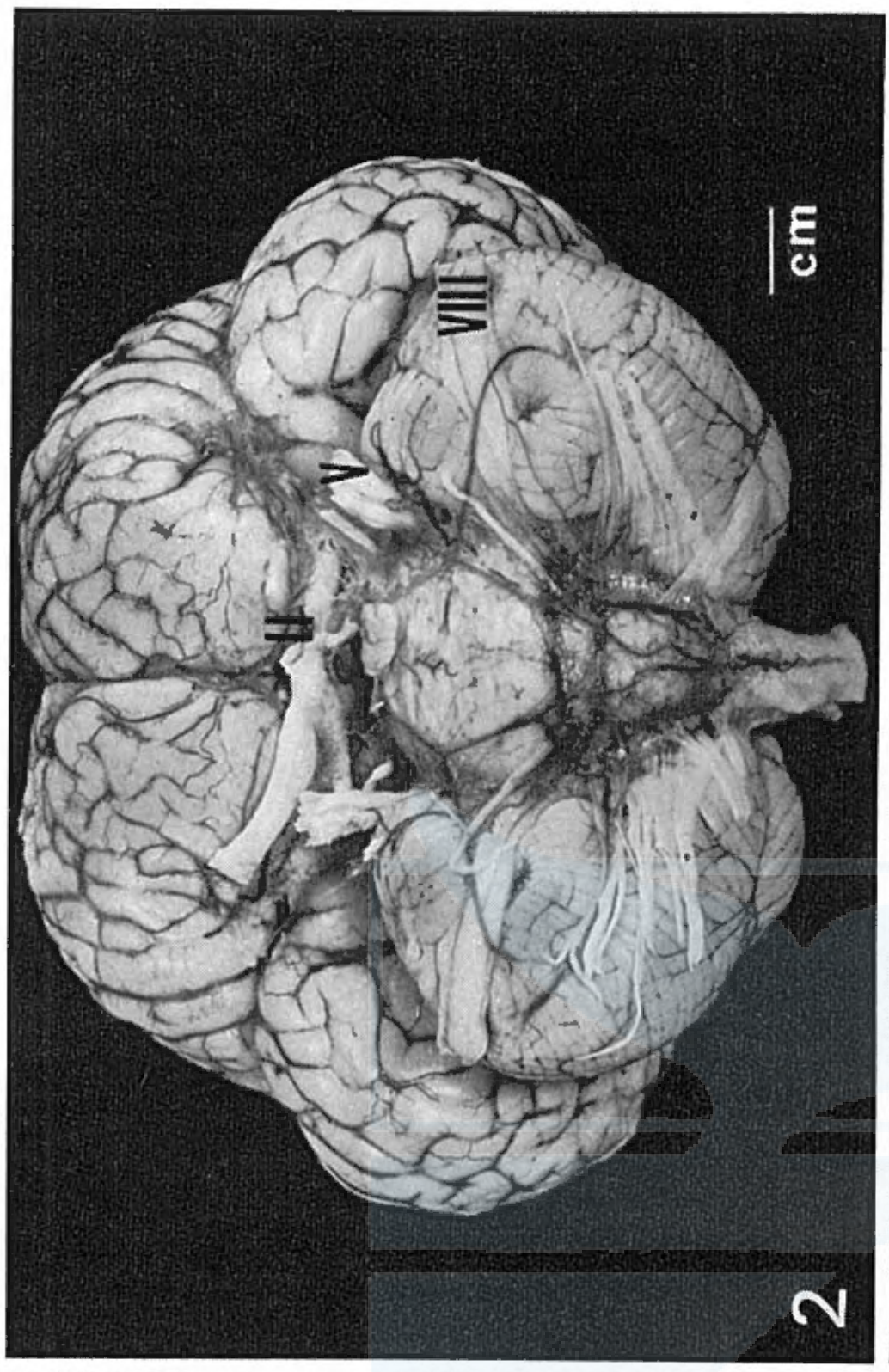
2

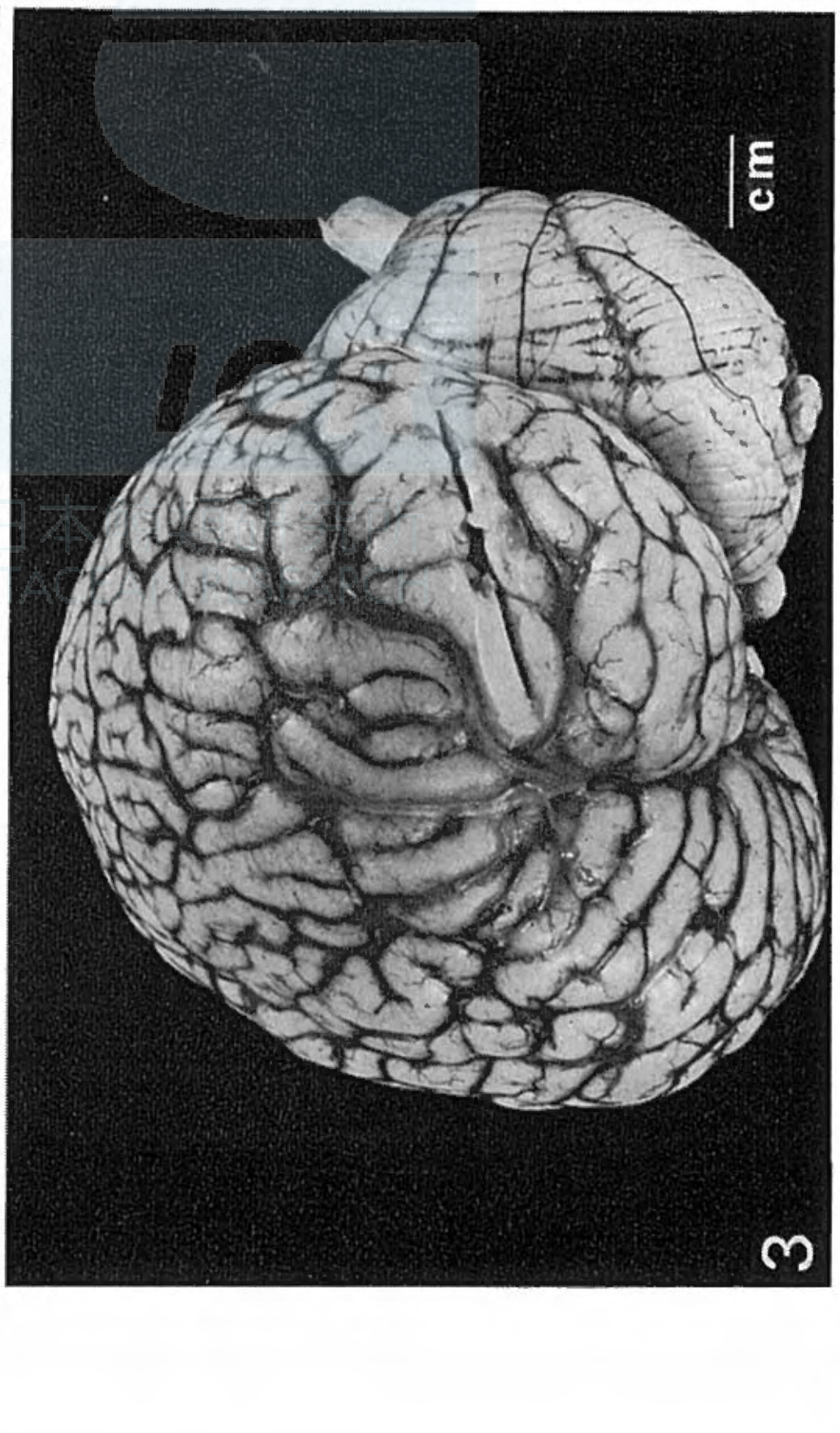
3

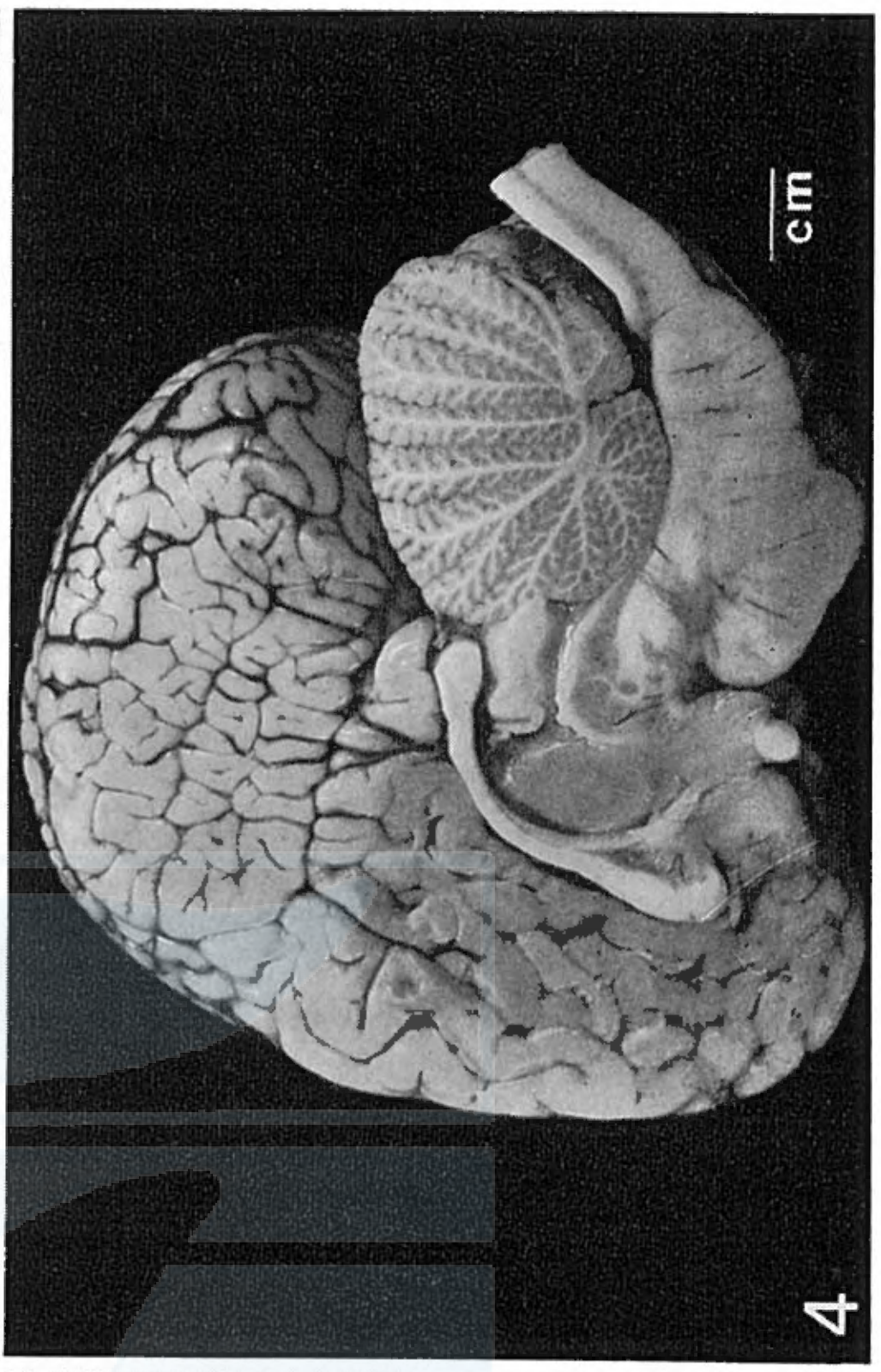
4


1
5 mm


2
5 mm

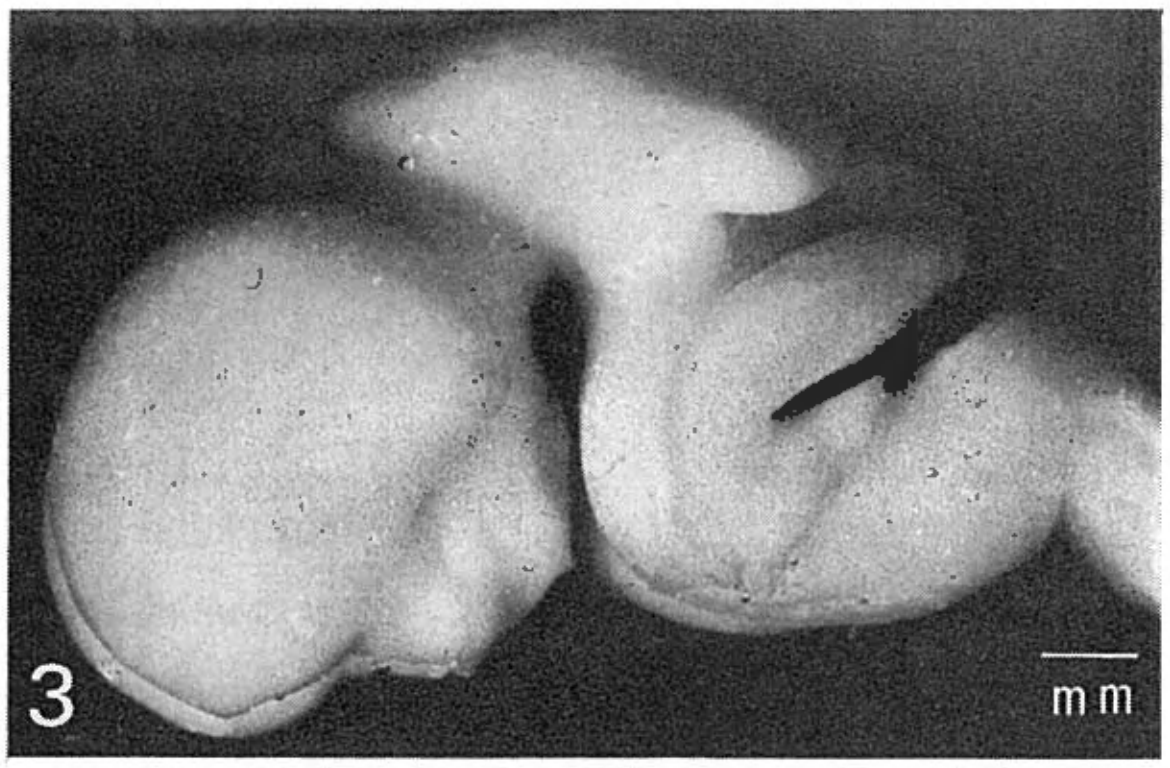
3
mm

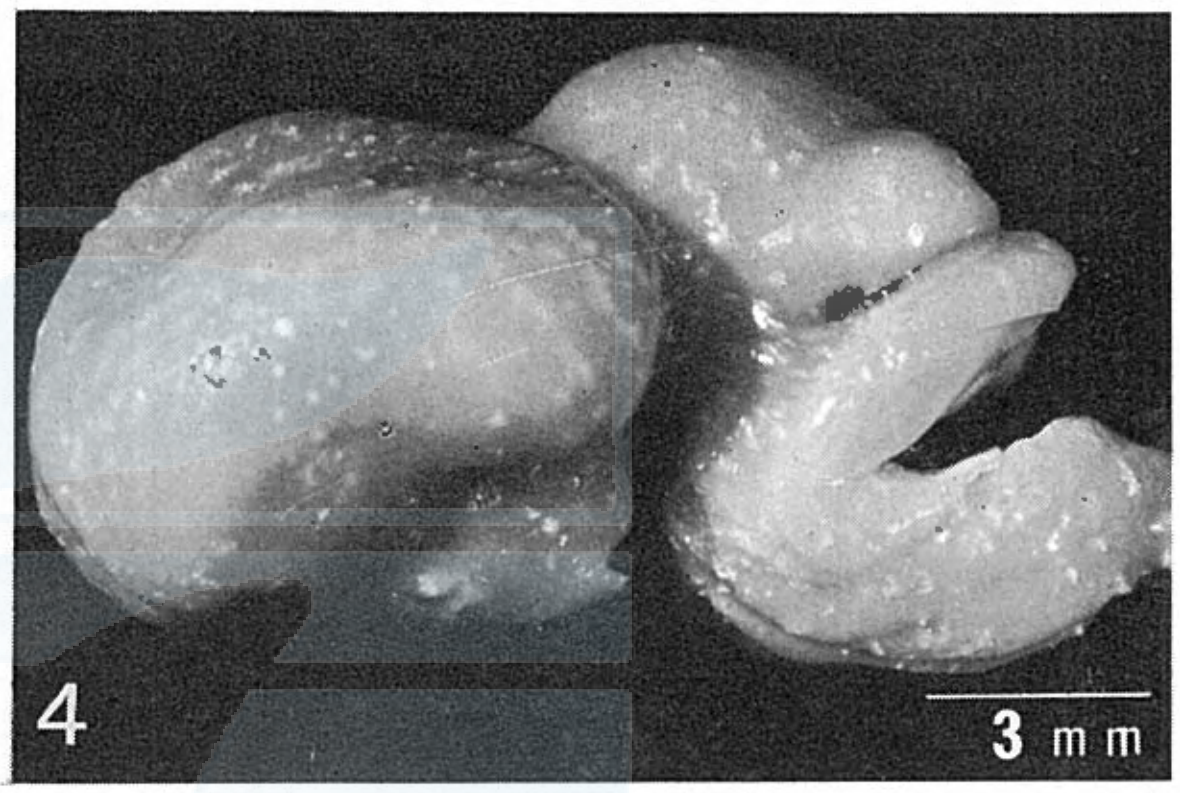
4
3 mm

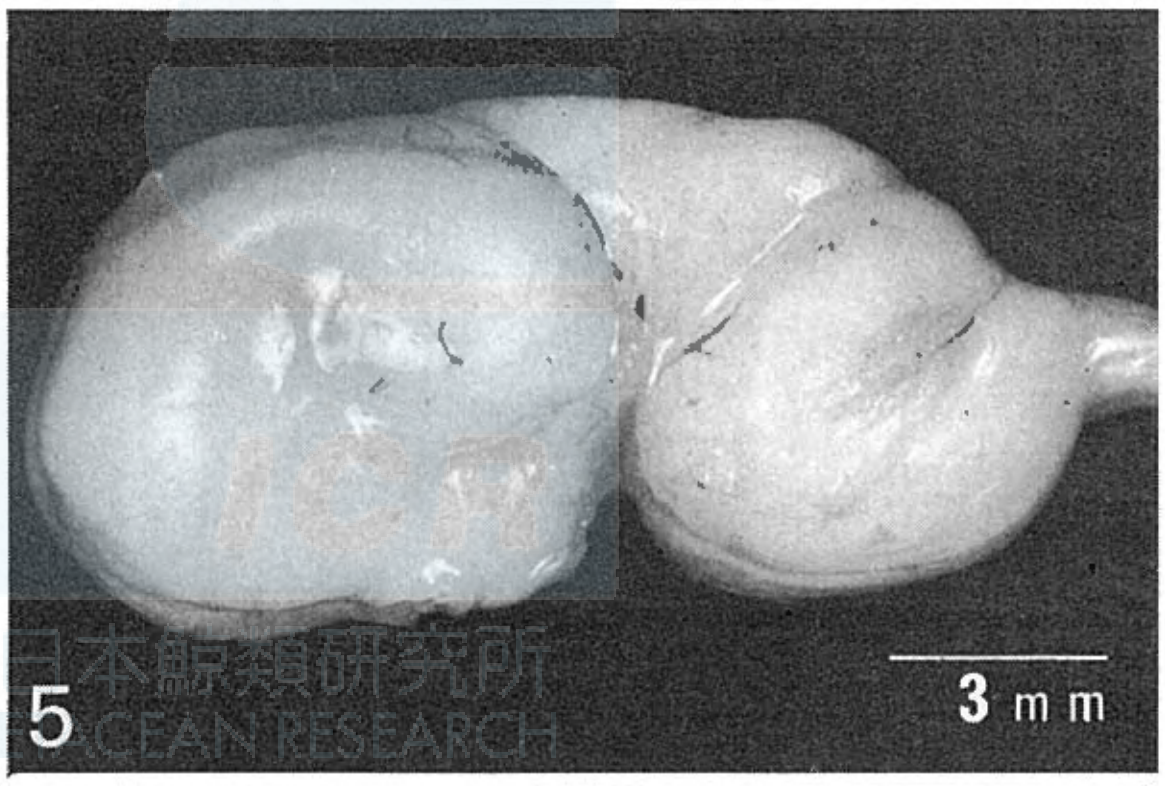
5
3 mm

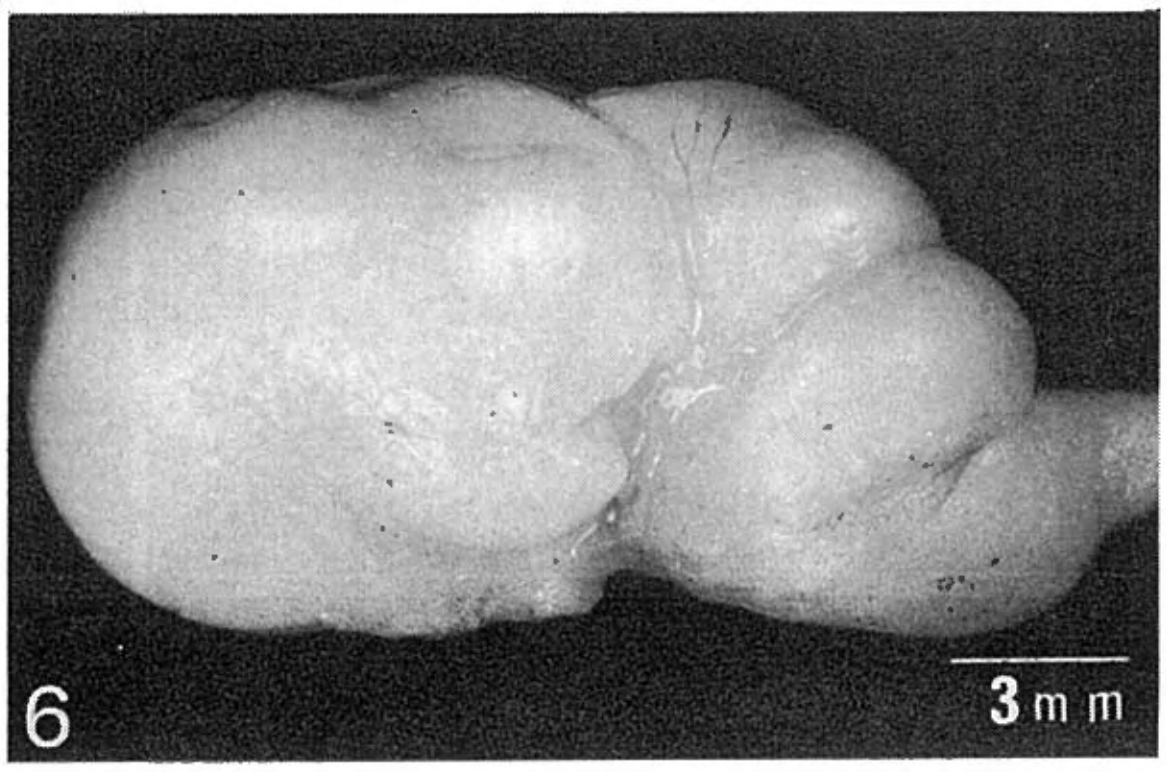
6
3 mm

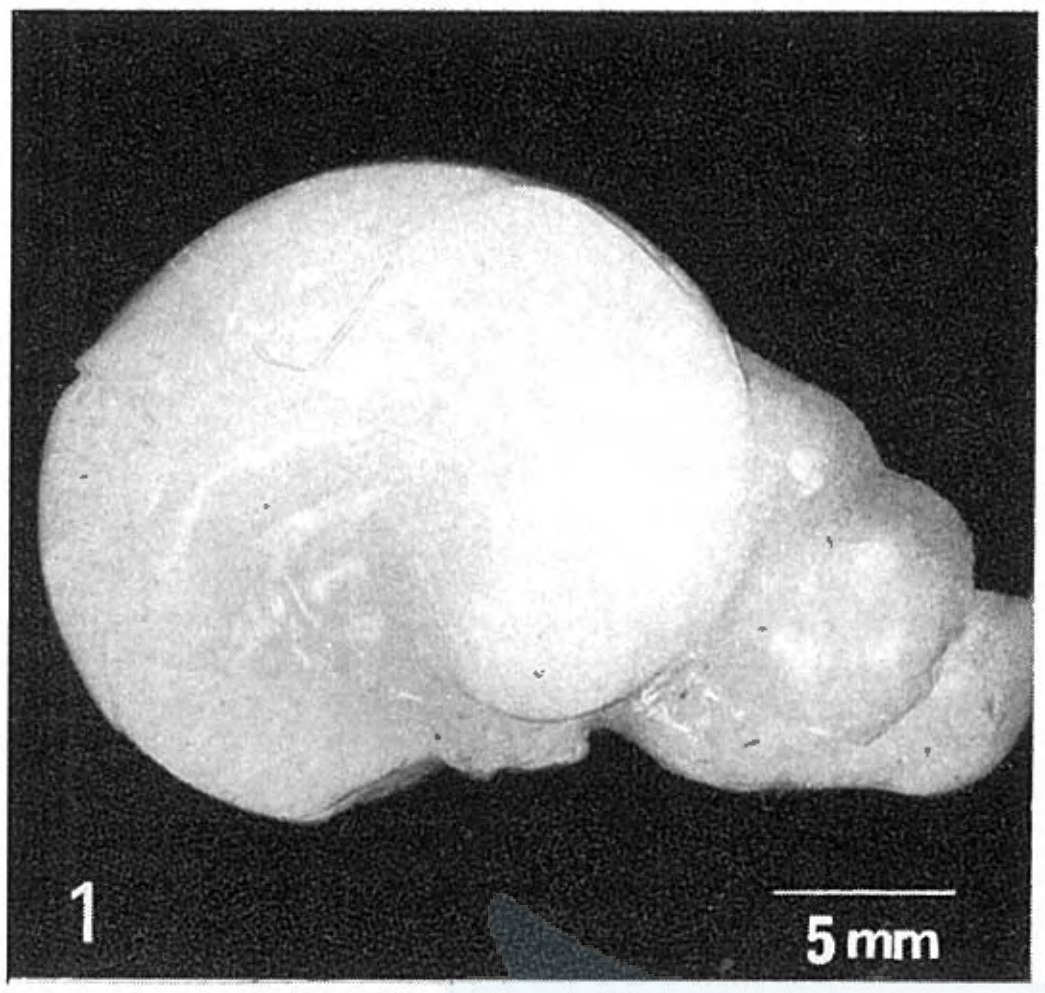
1
5 mm

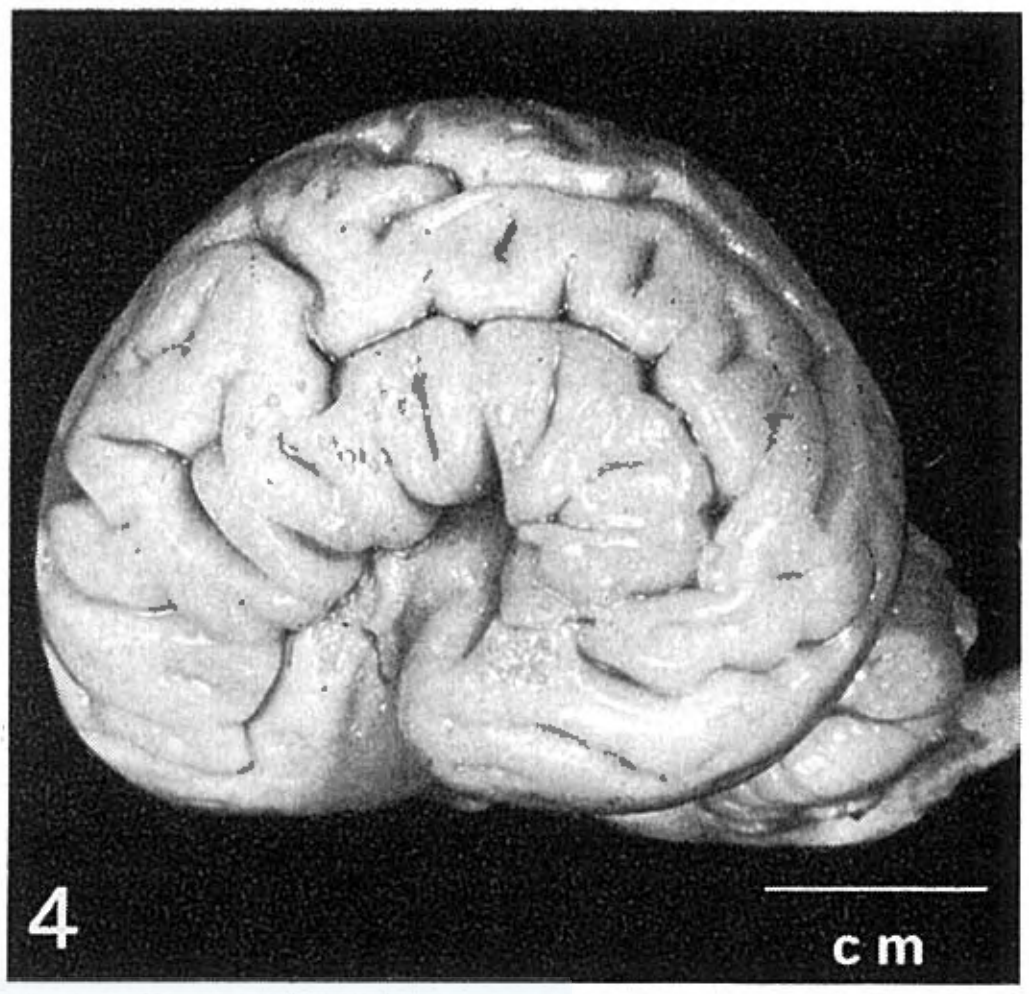
4
cm

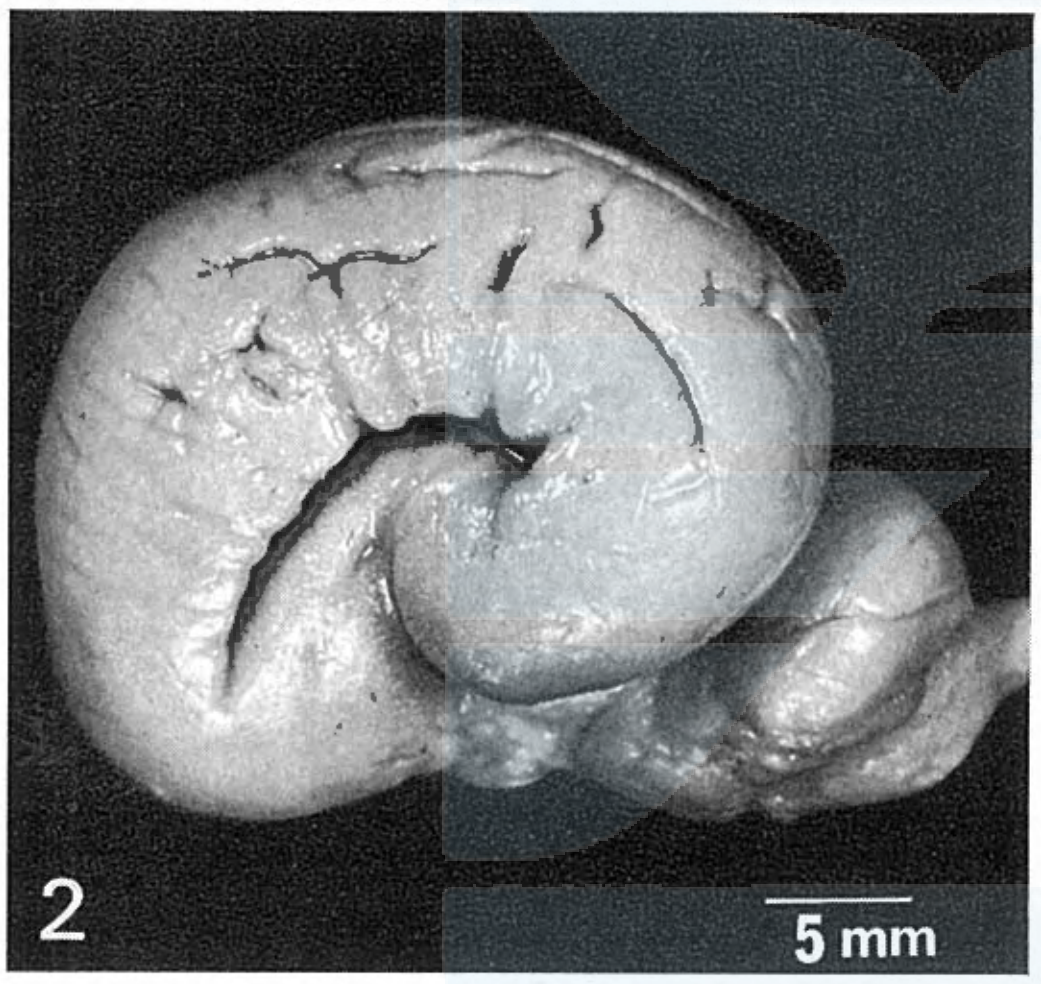
2
5 mm

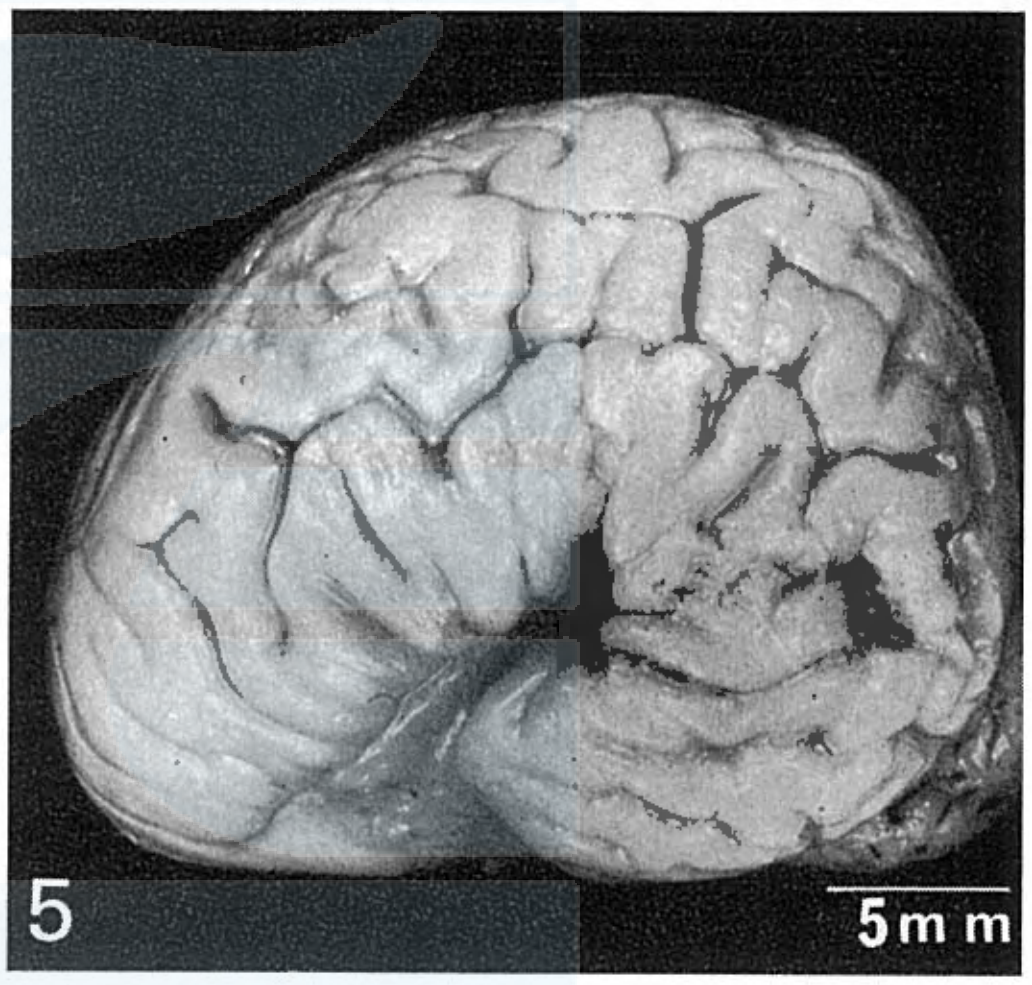
5
5 mm

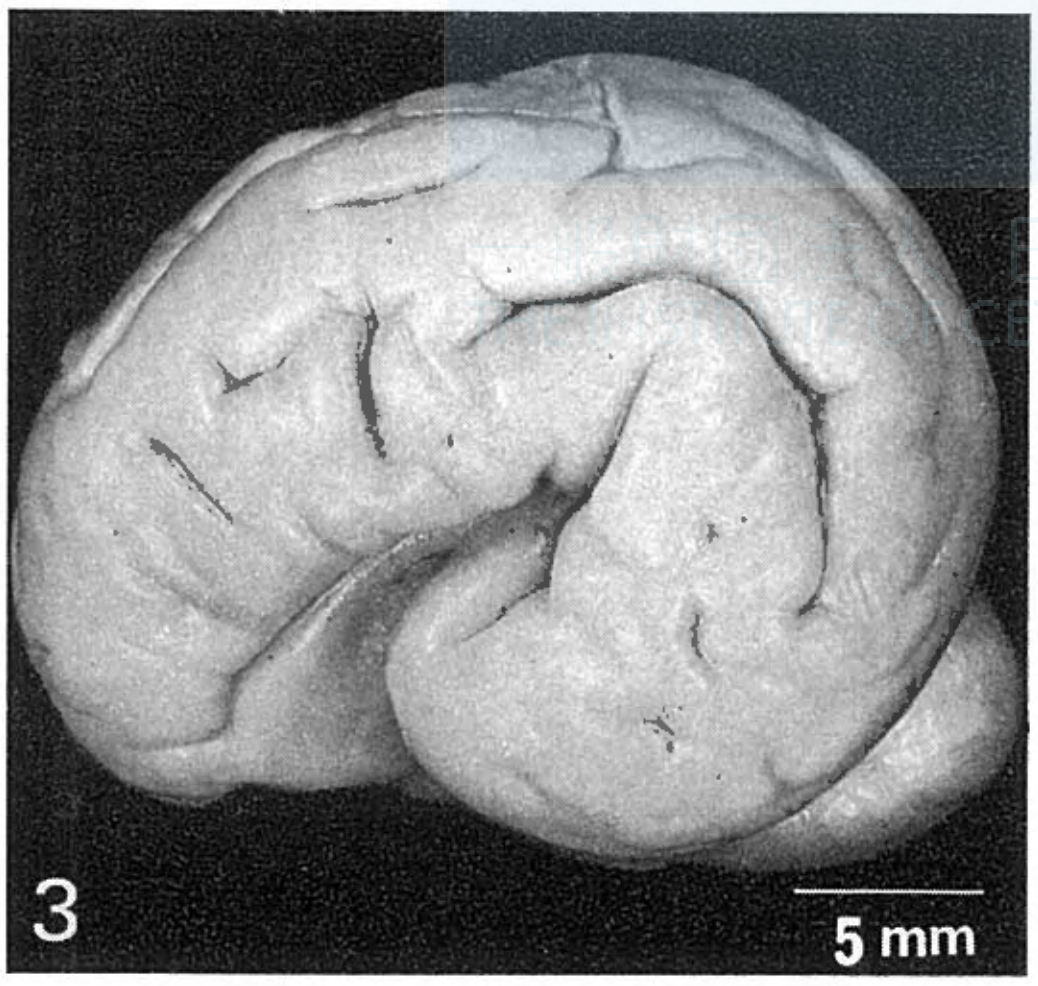
3
5 mm

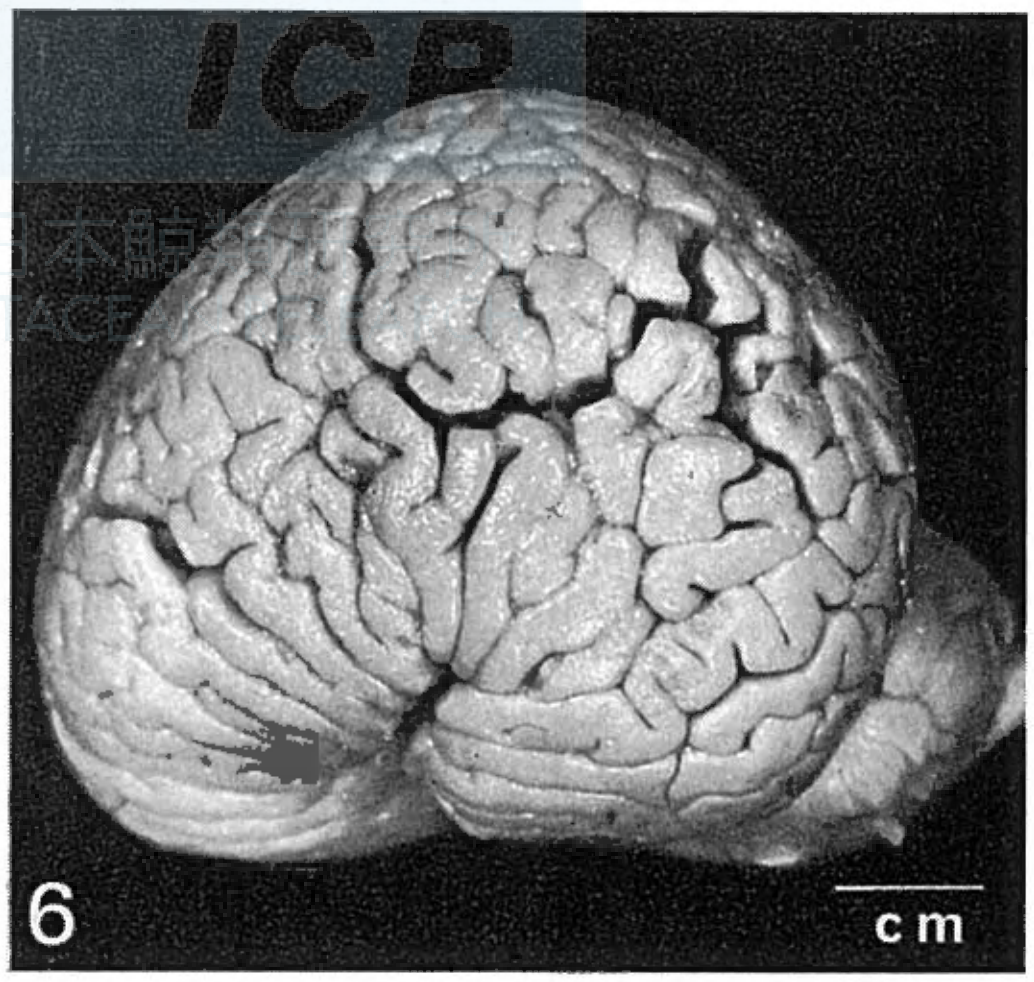
6
cm

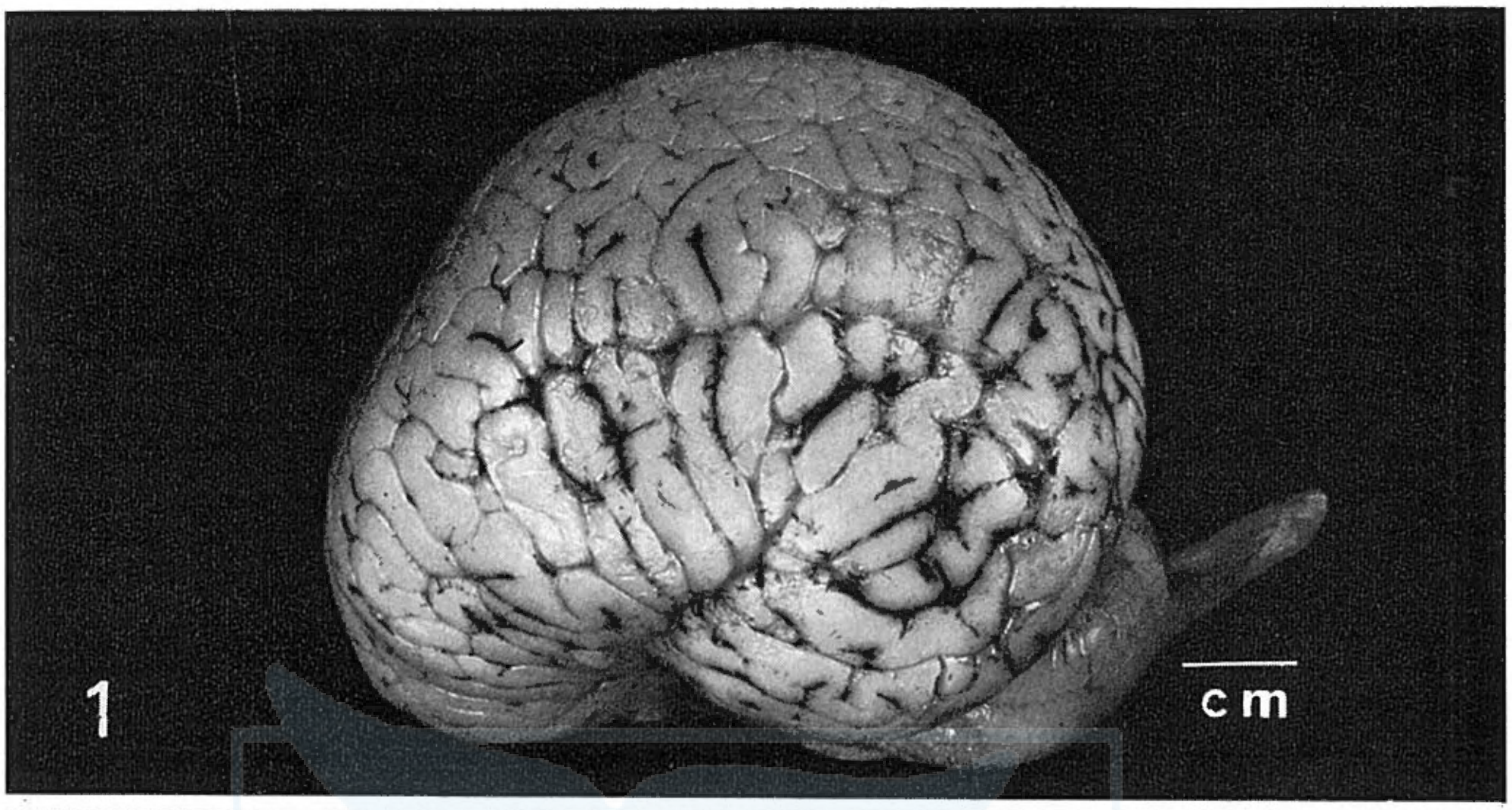
1
cm


2
cm

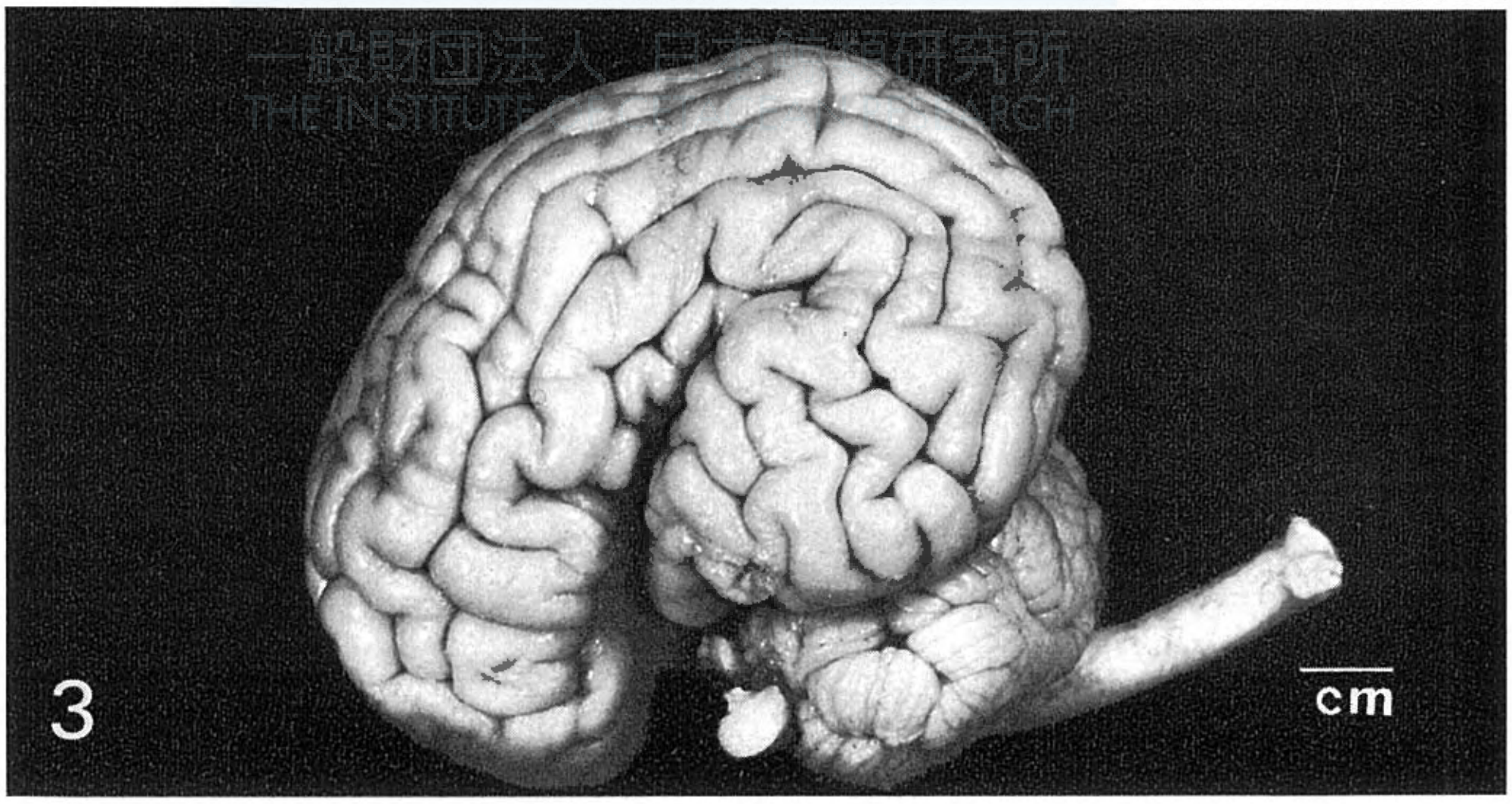
3
cm

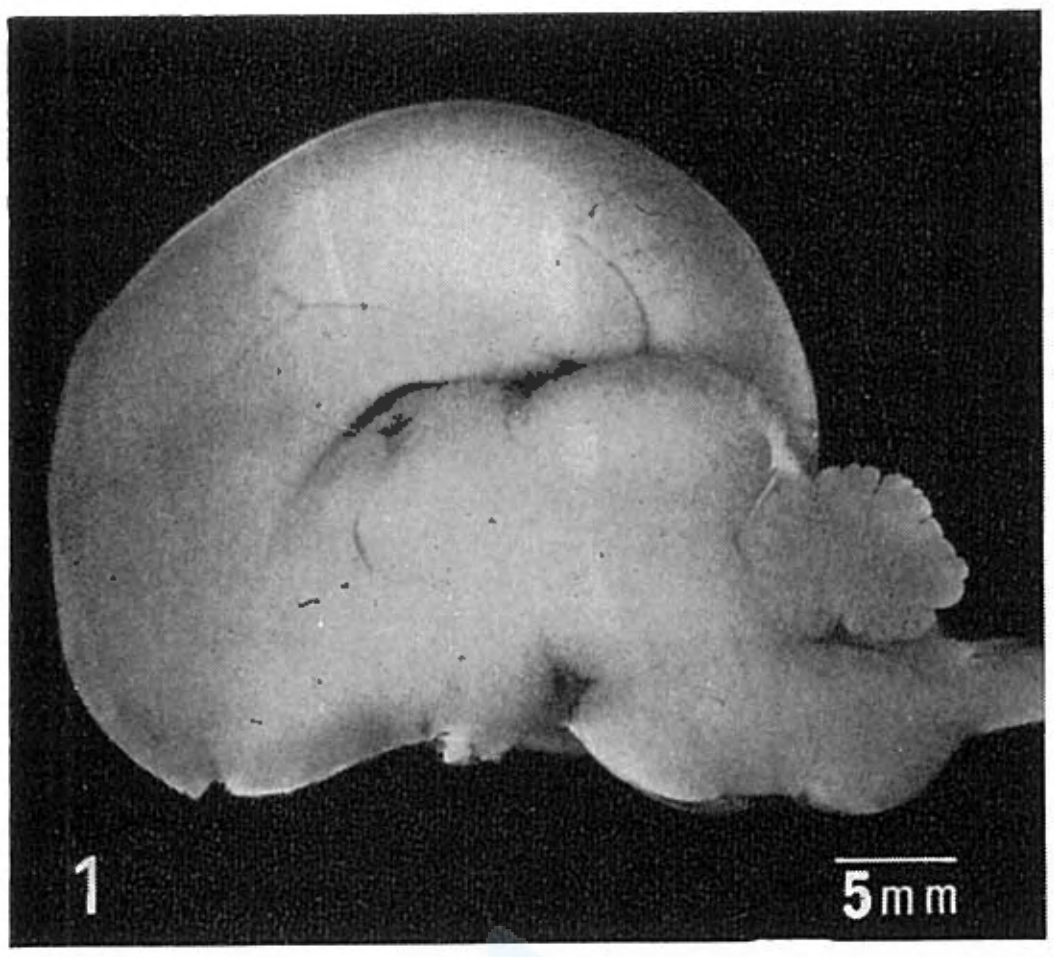
1
5mm

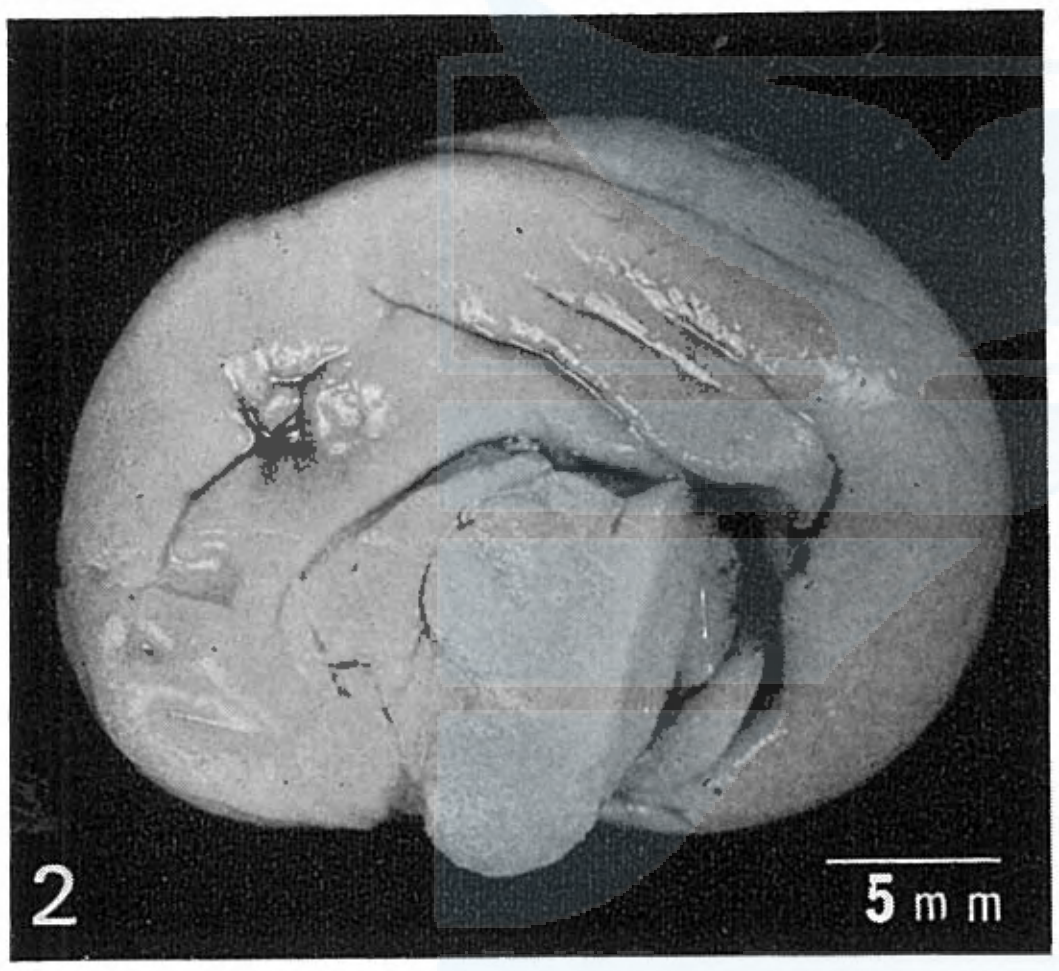
2
5 mm

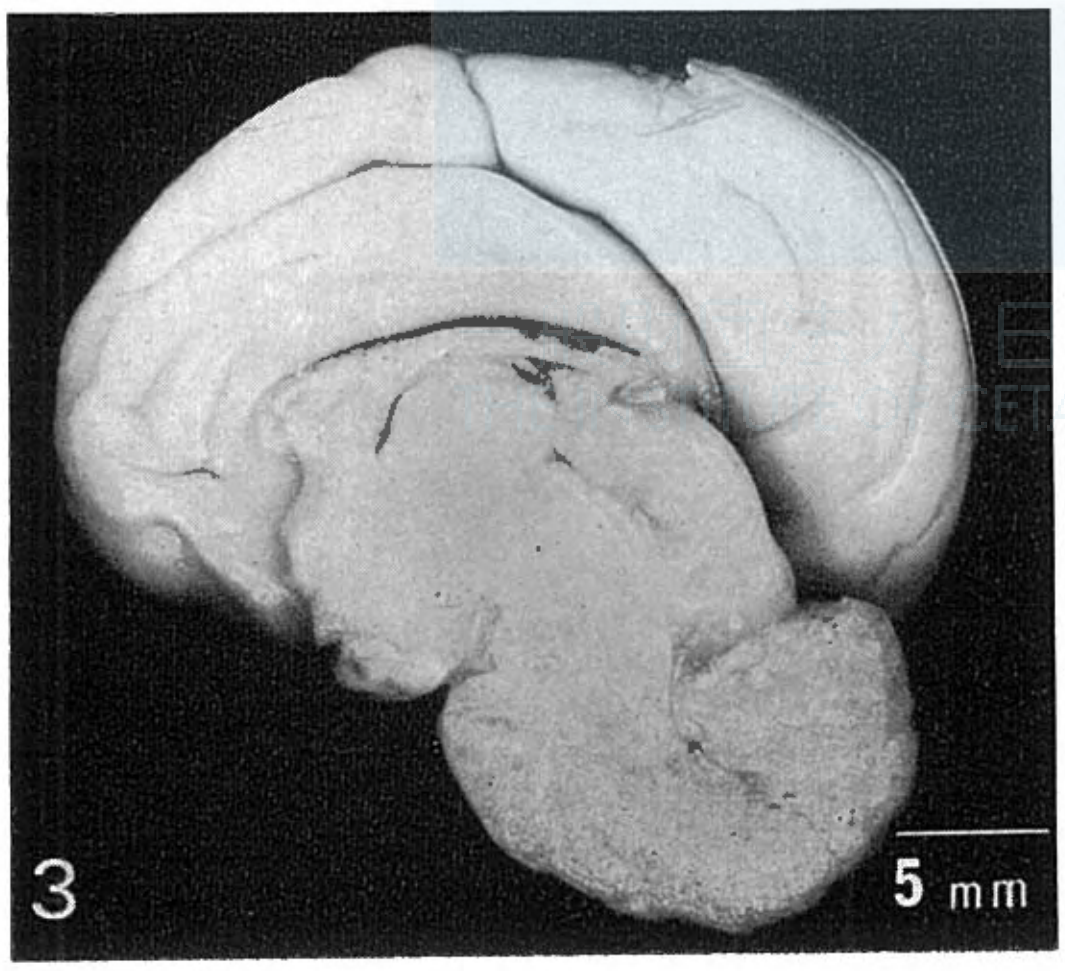
3
5 mm

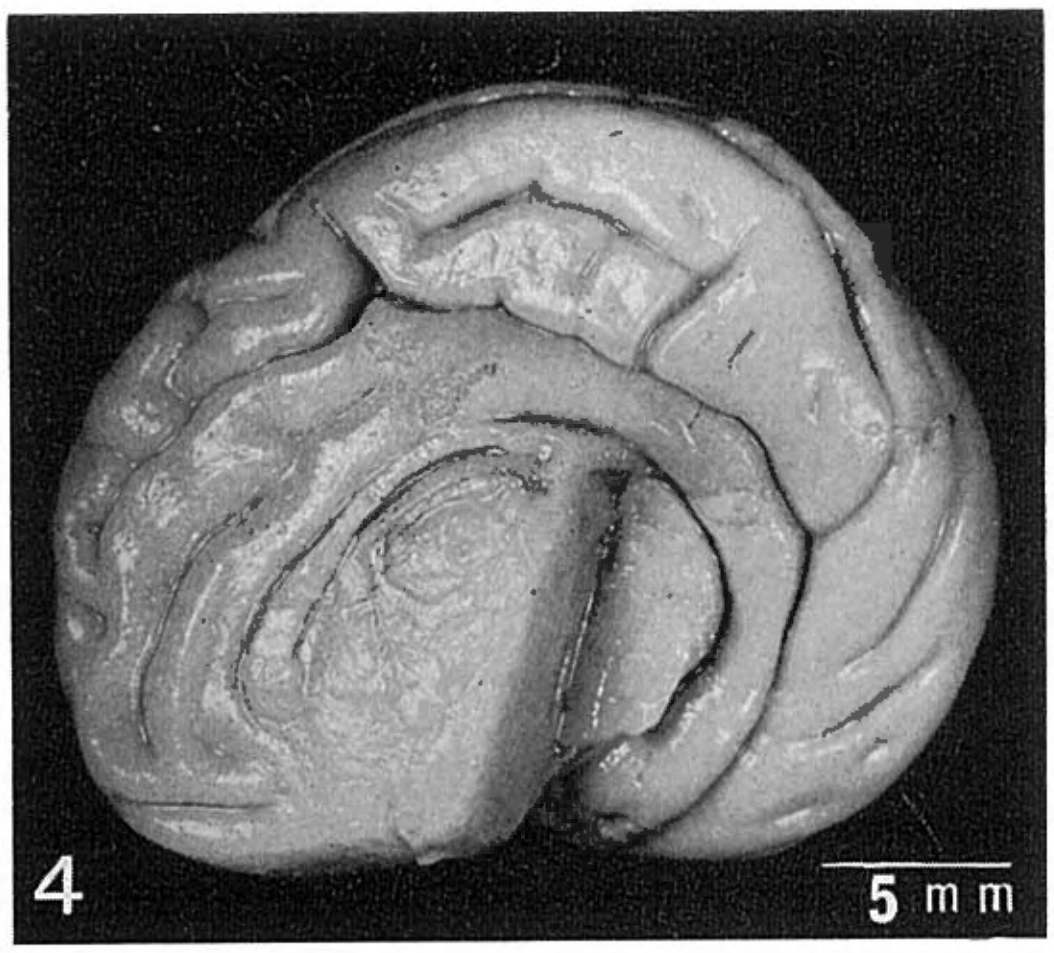
4
5 mm

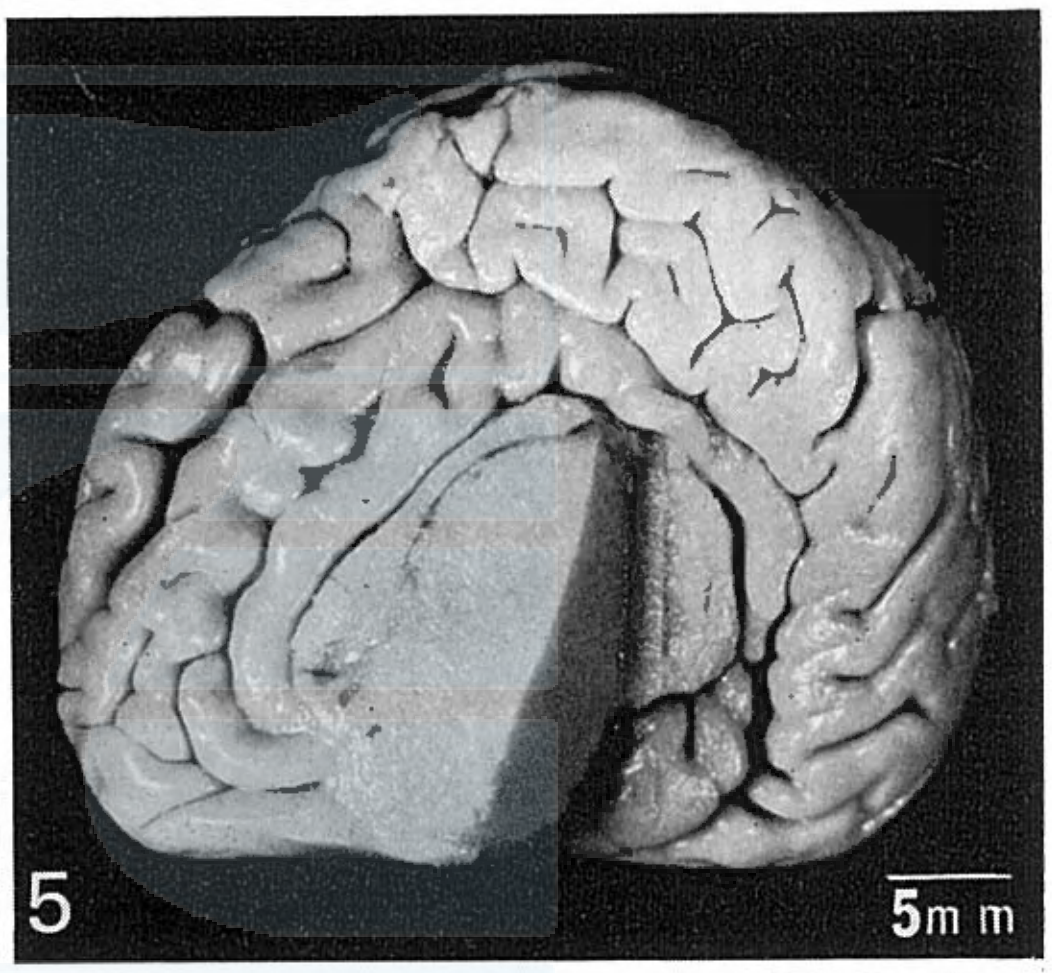
5
5mm

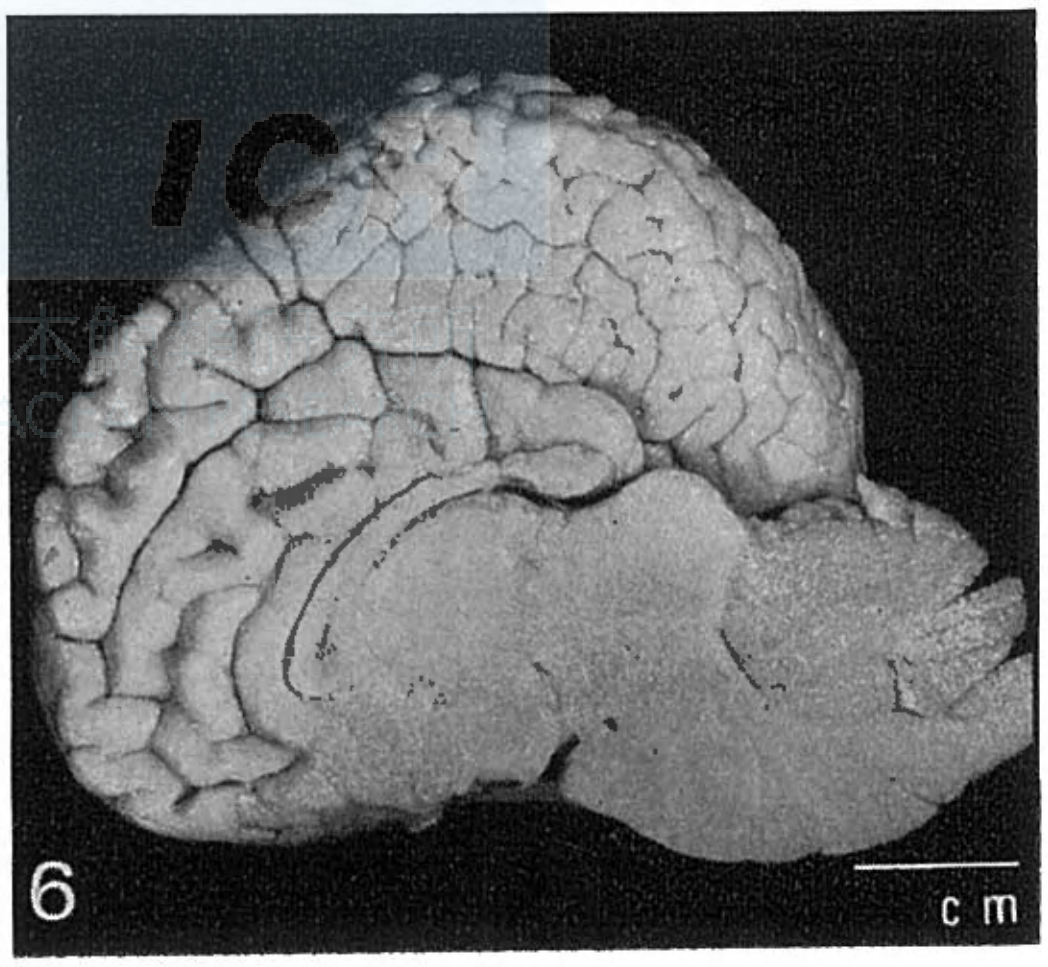
6
cm

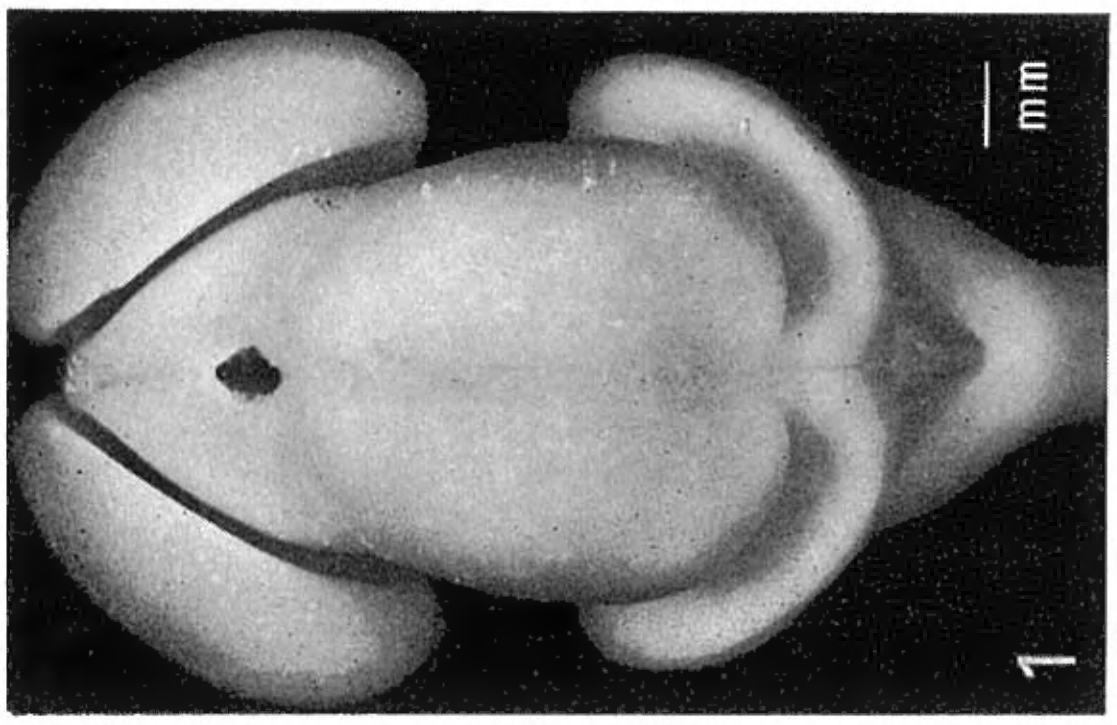
1

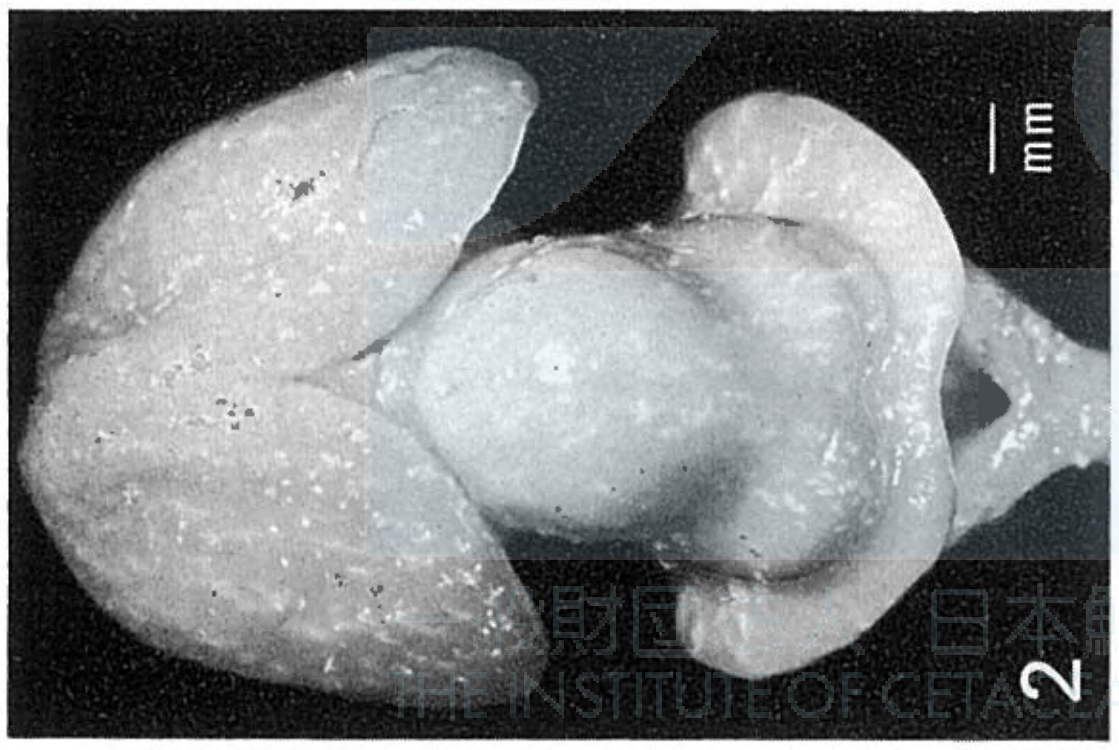
2

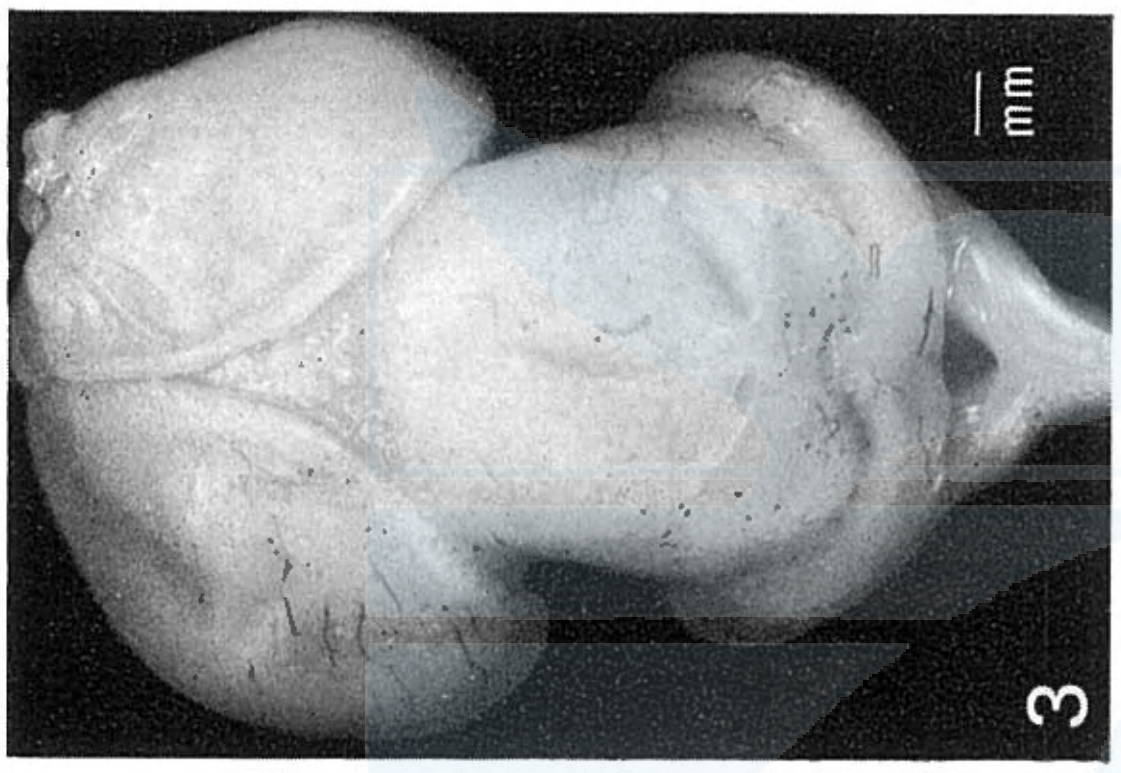
3

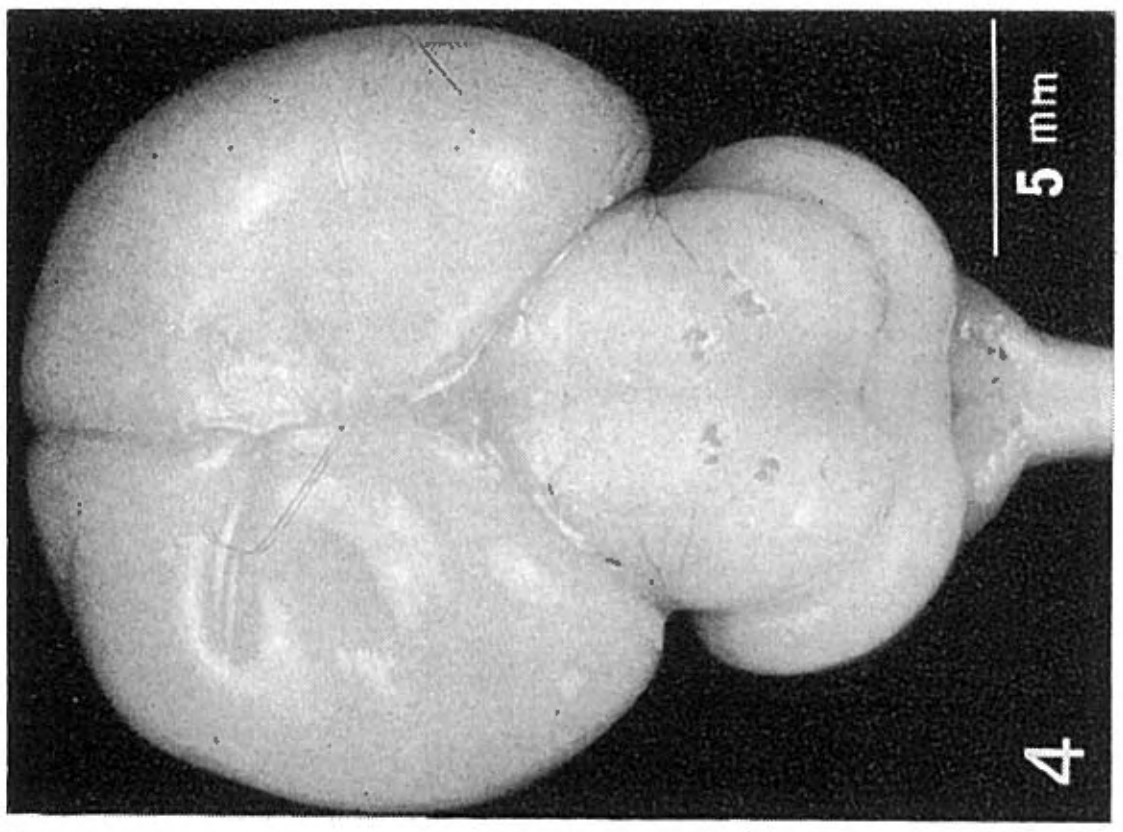
4


5

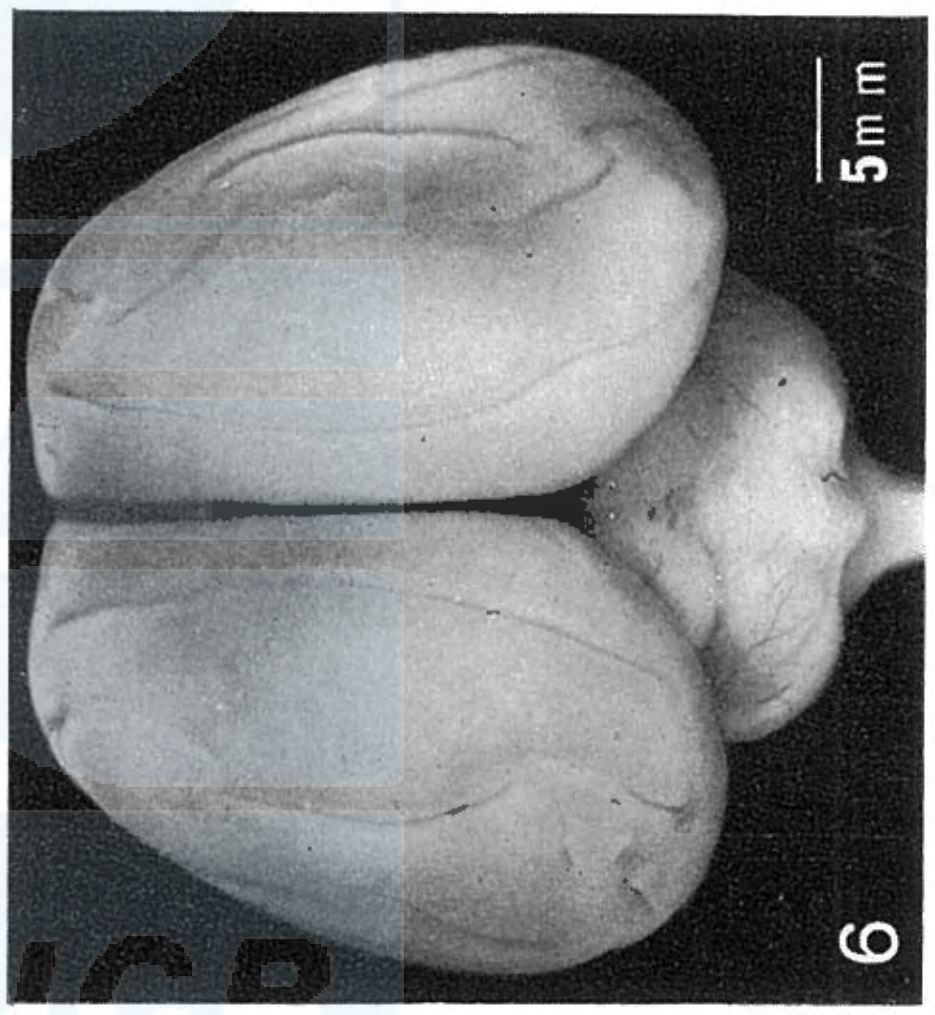
6


7

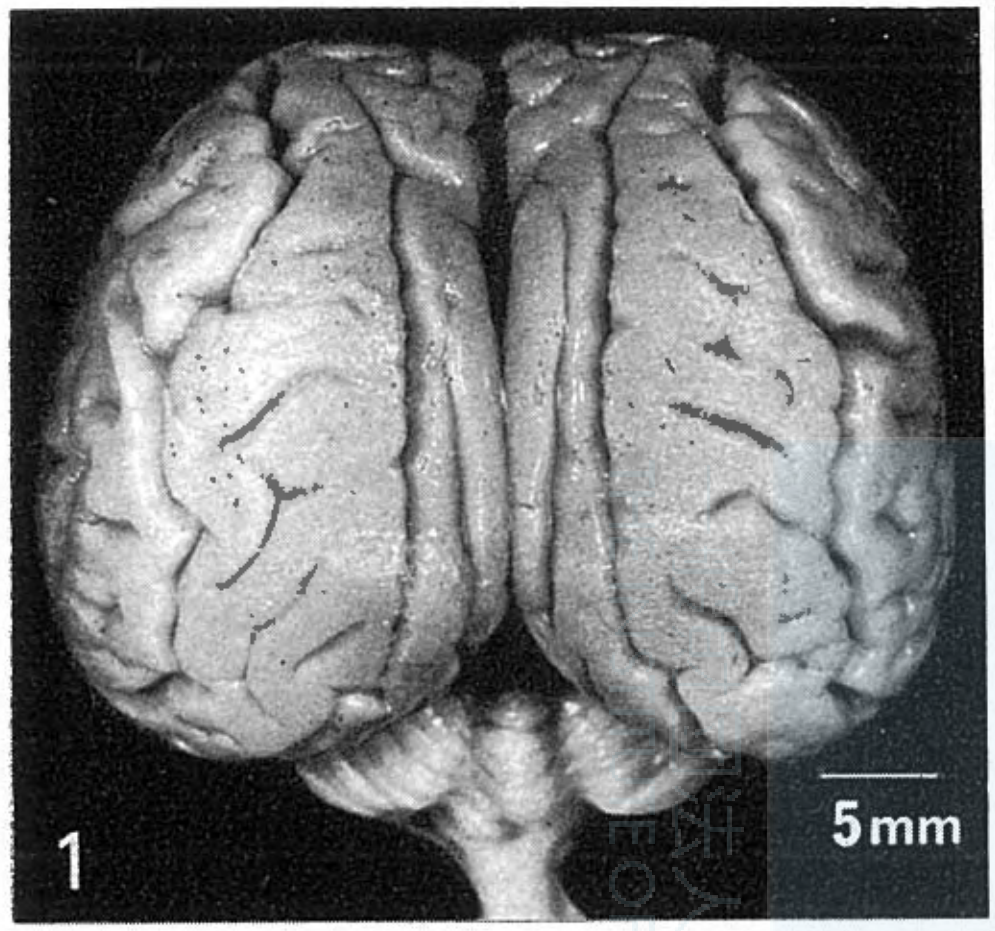
1

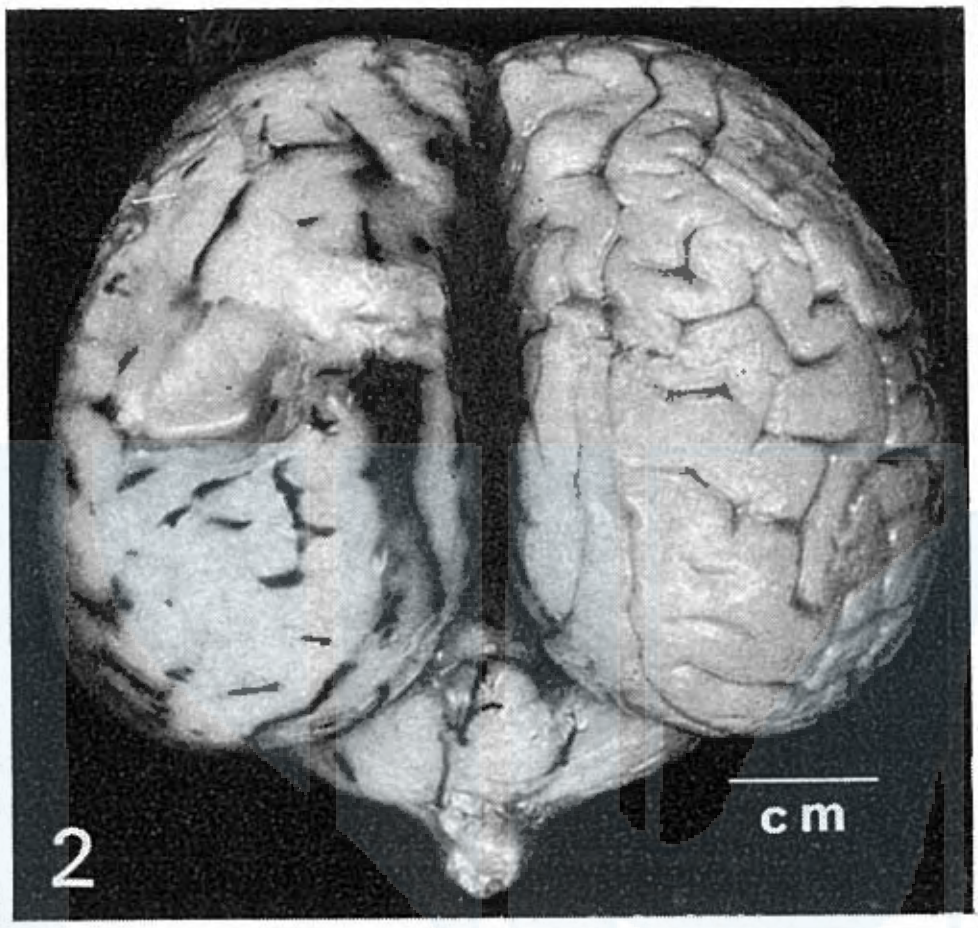
2

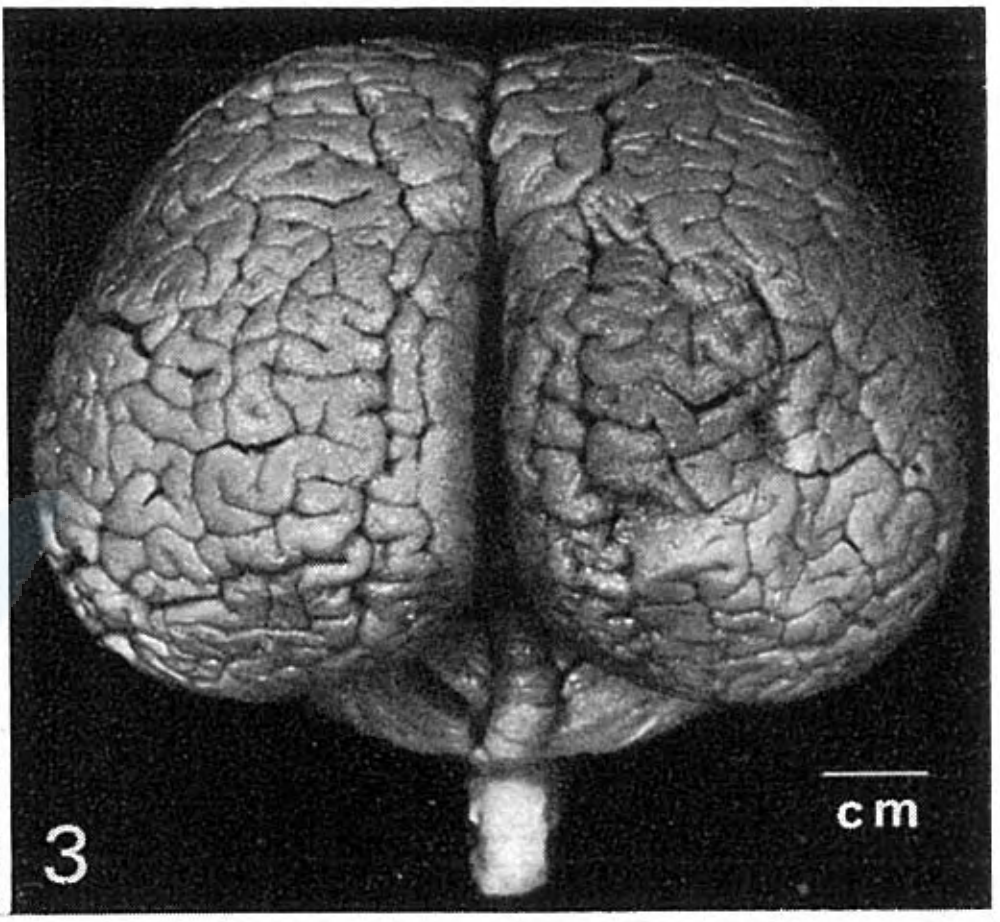
3

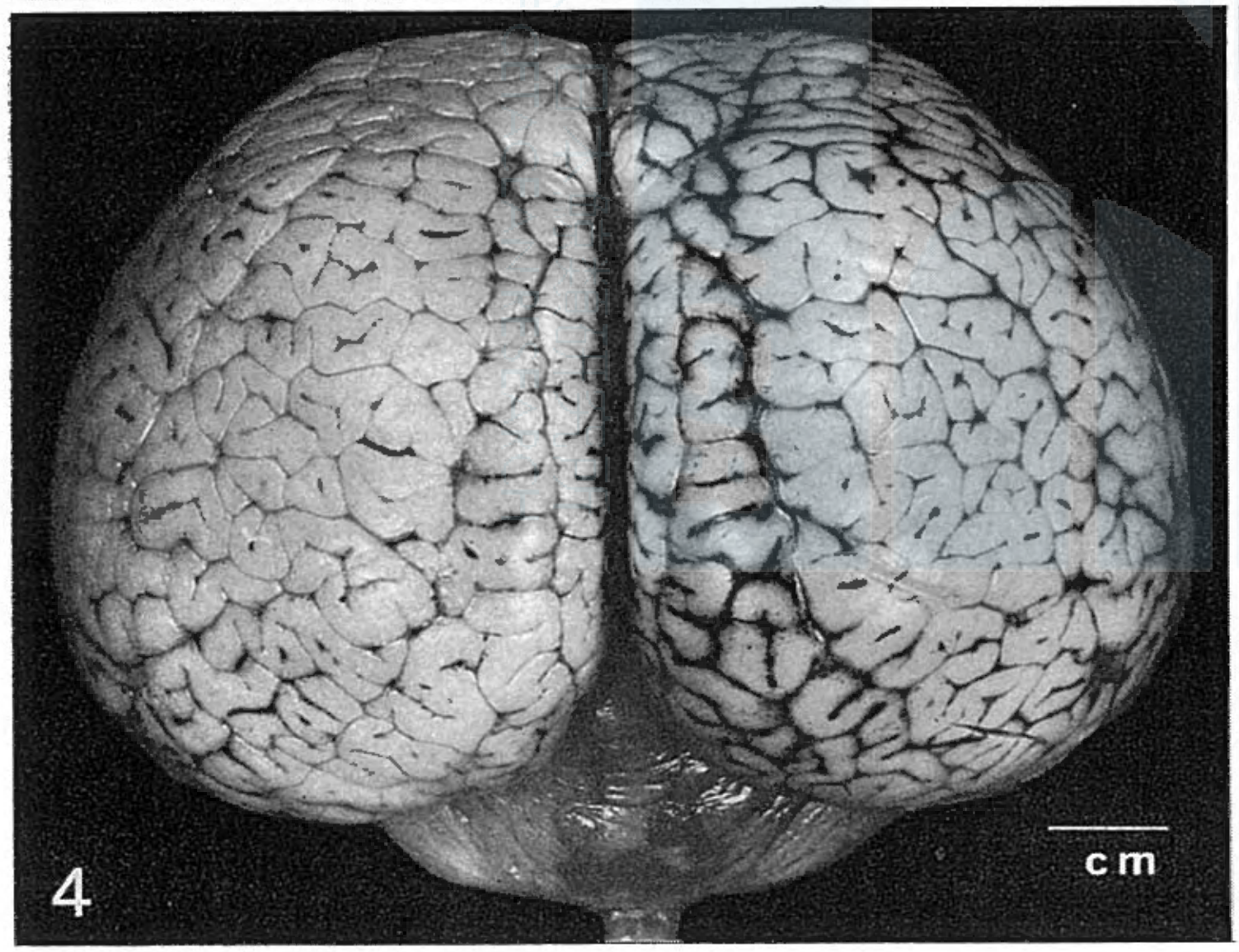
4

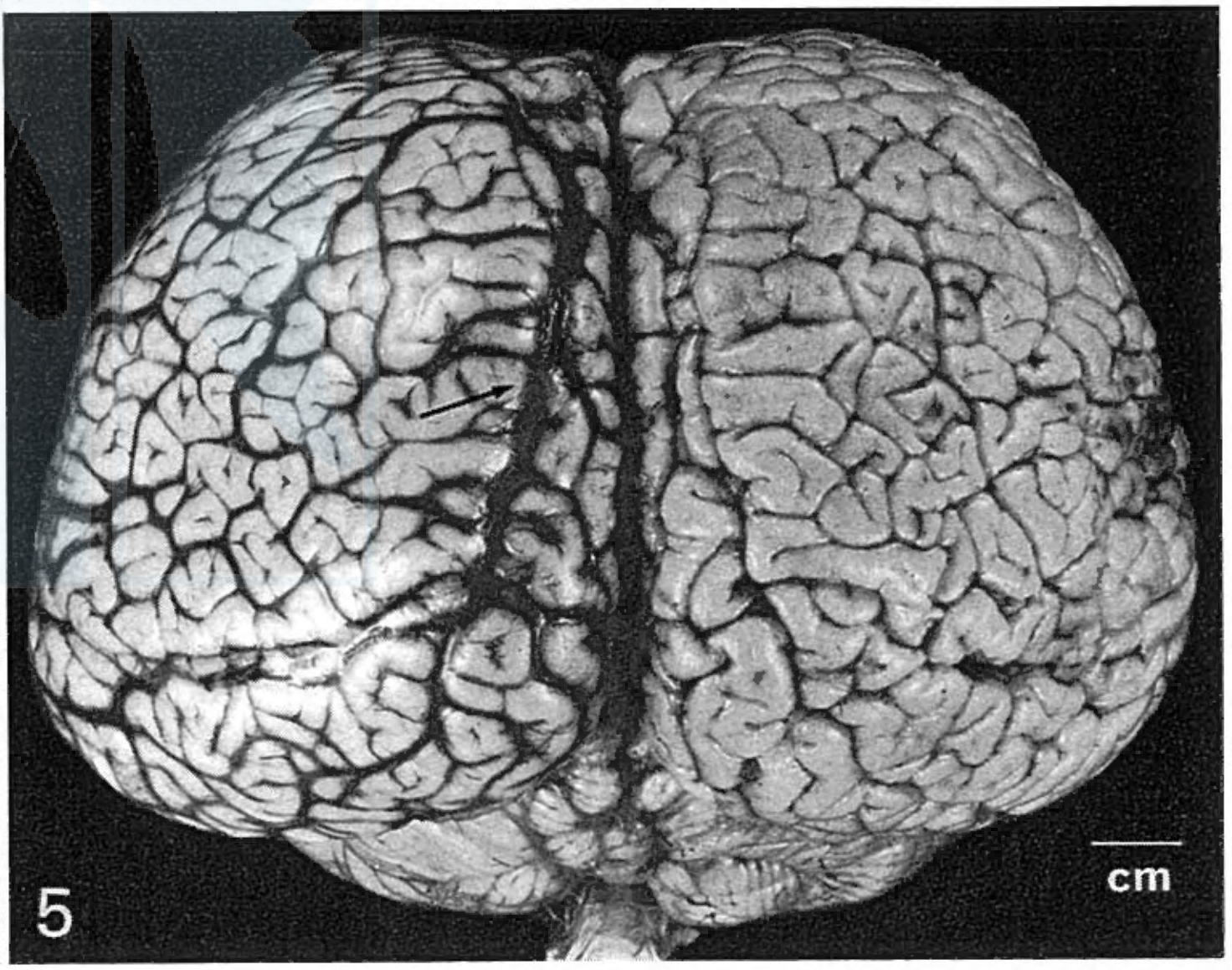
5

1

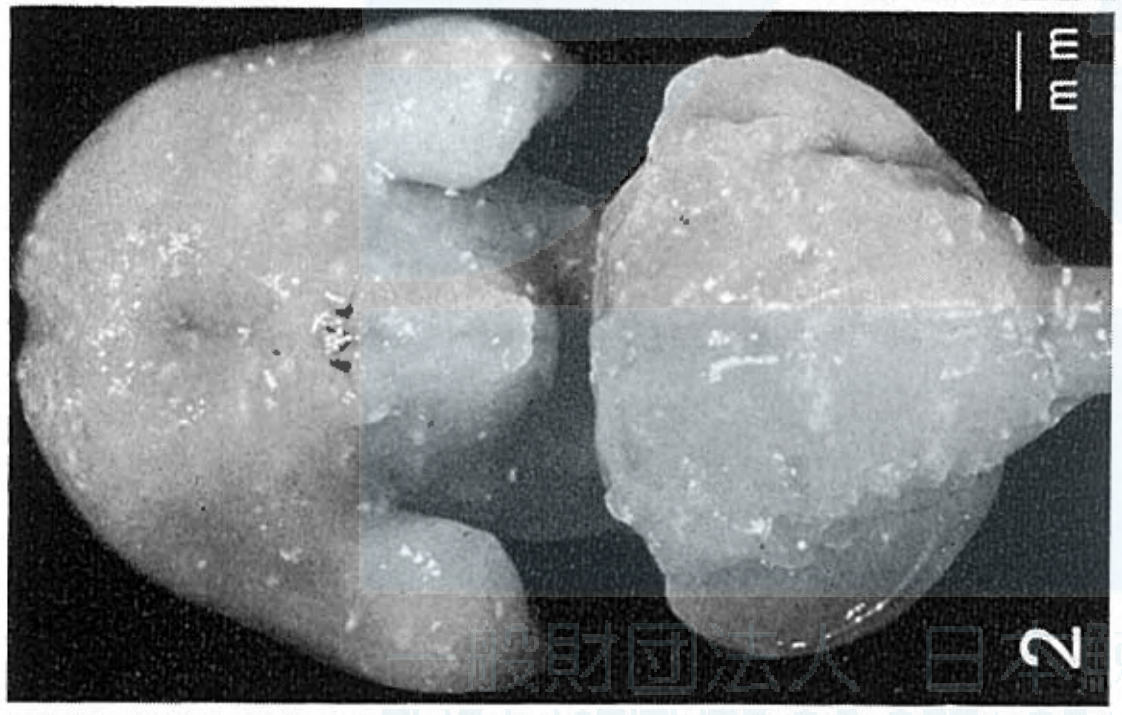

2

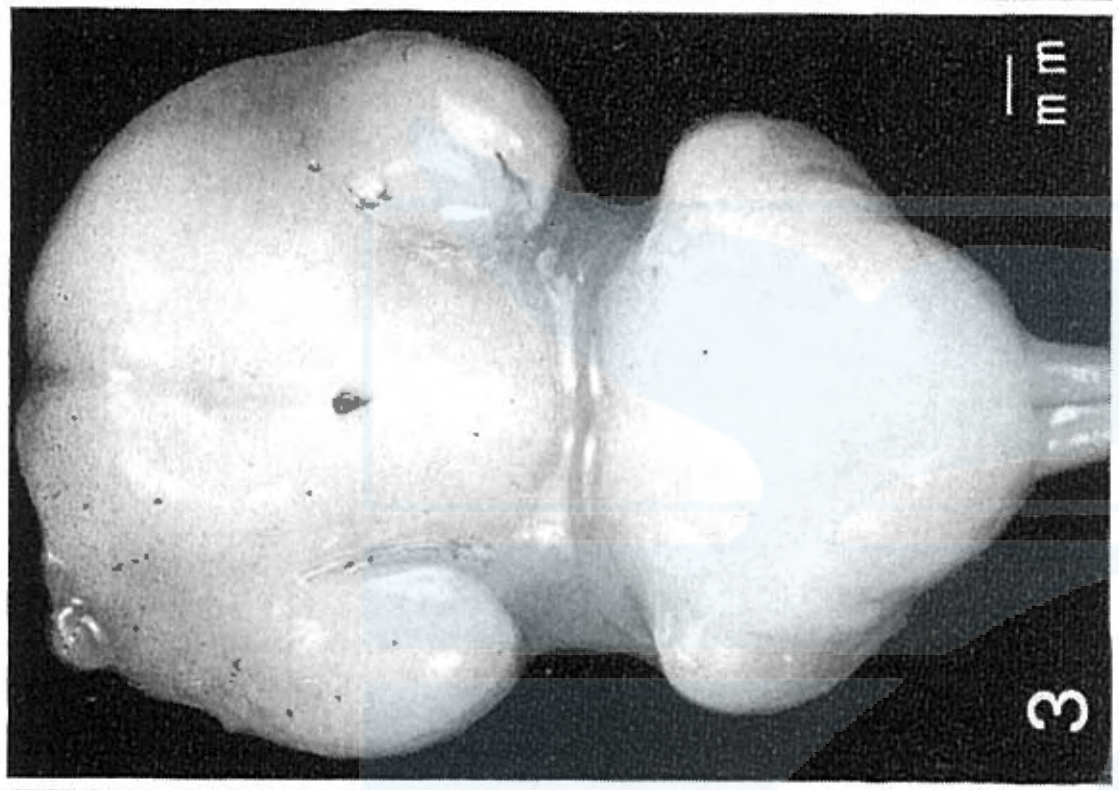

3

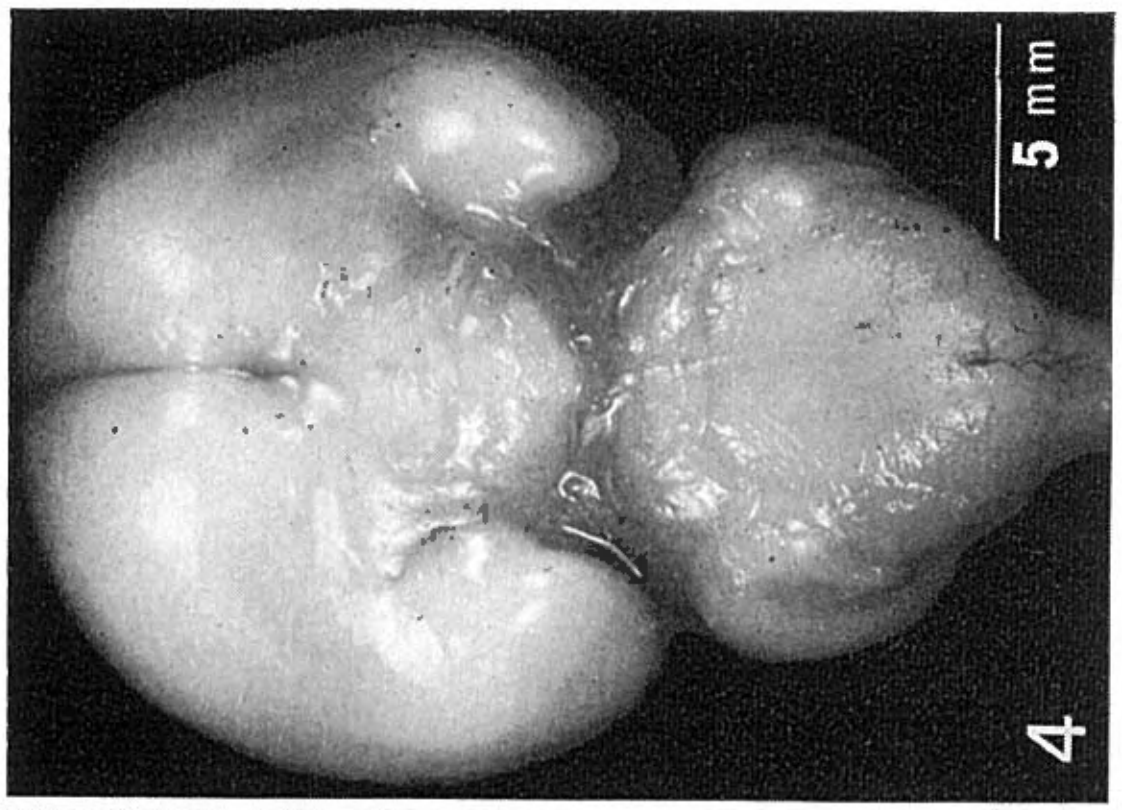

4

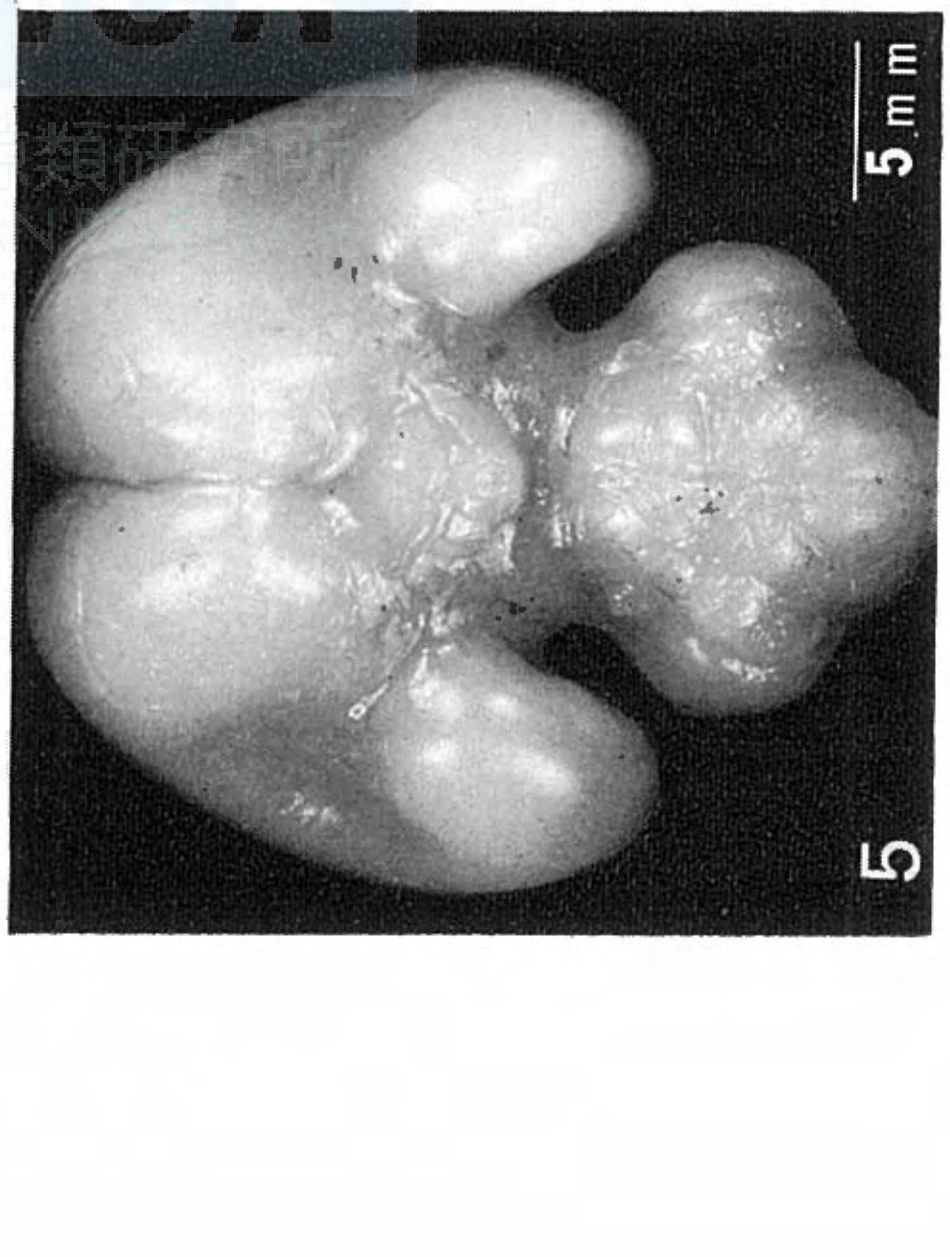

5

6

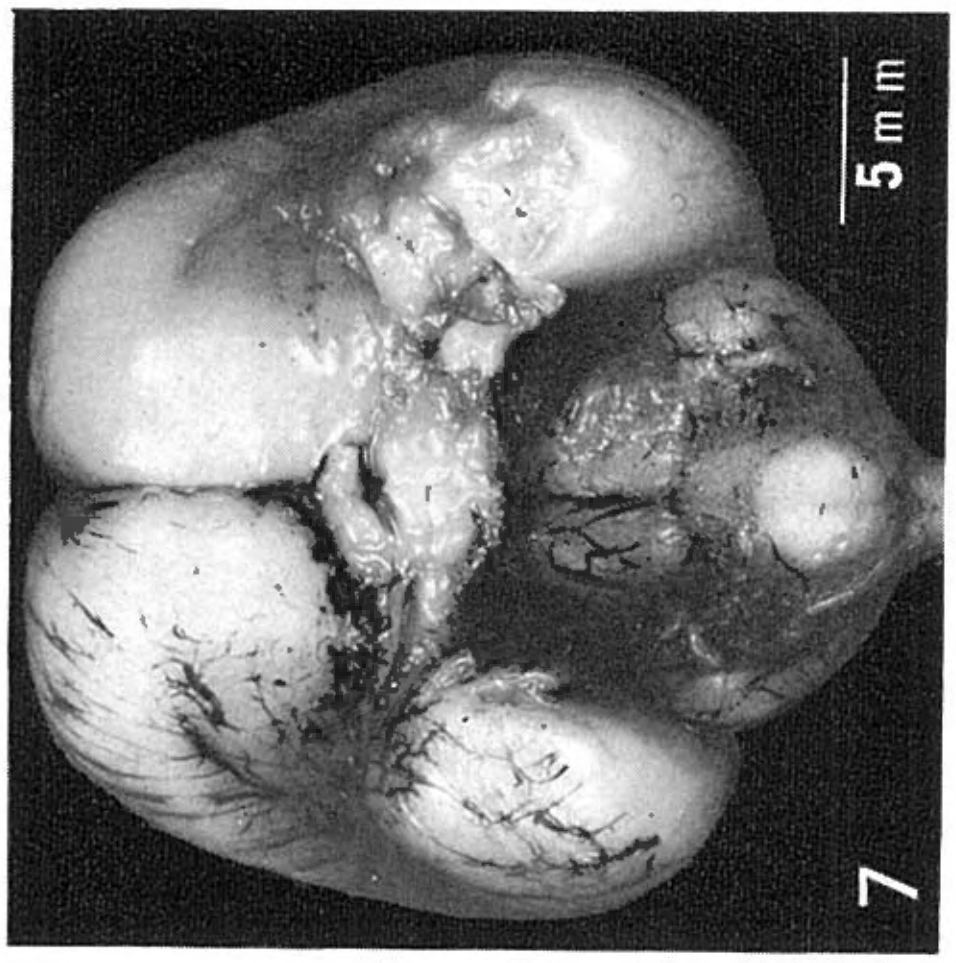

7

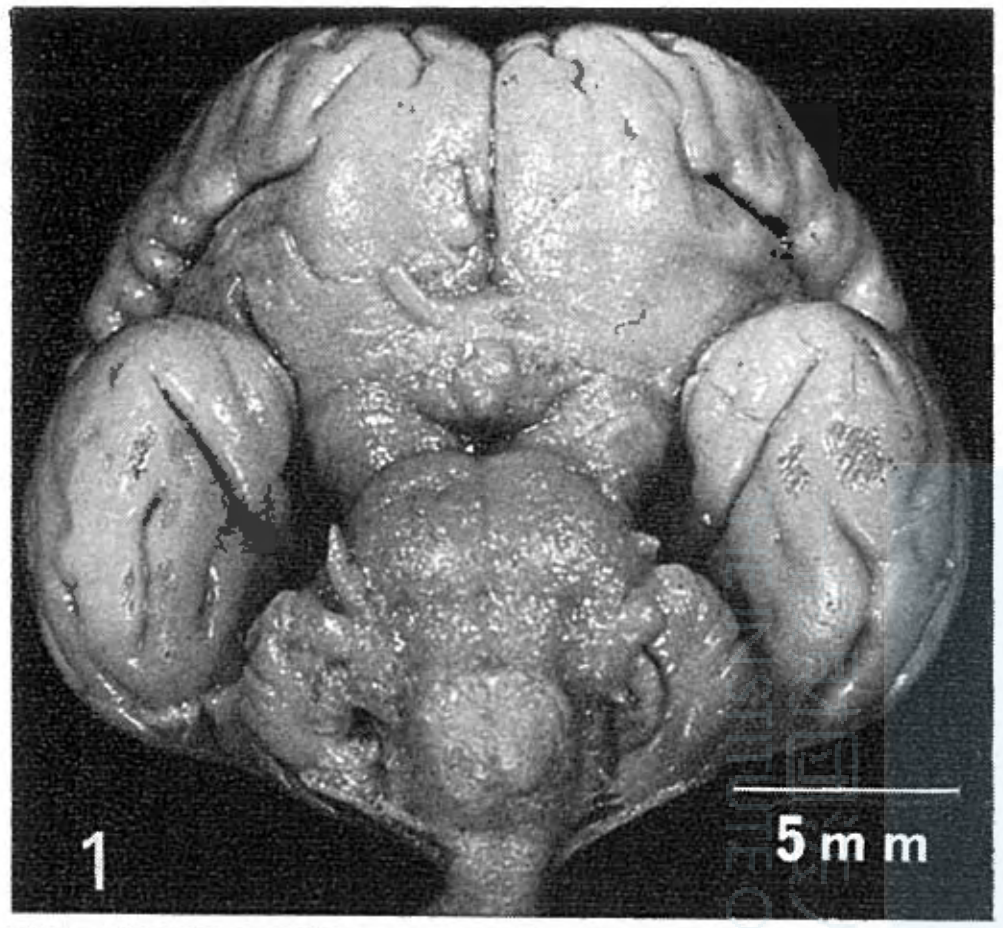

1

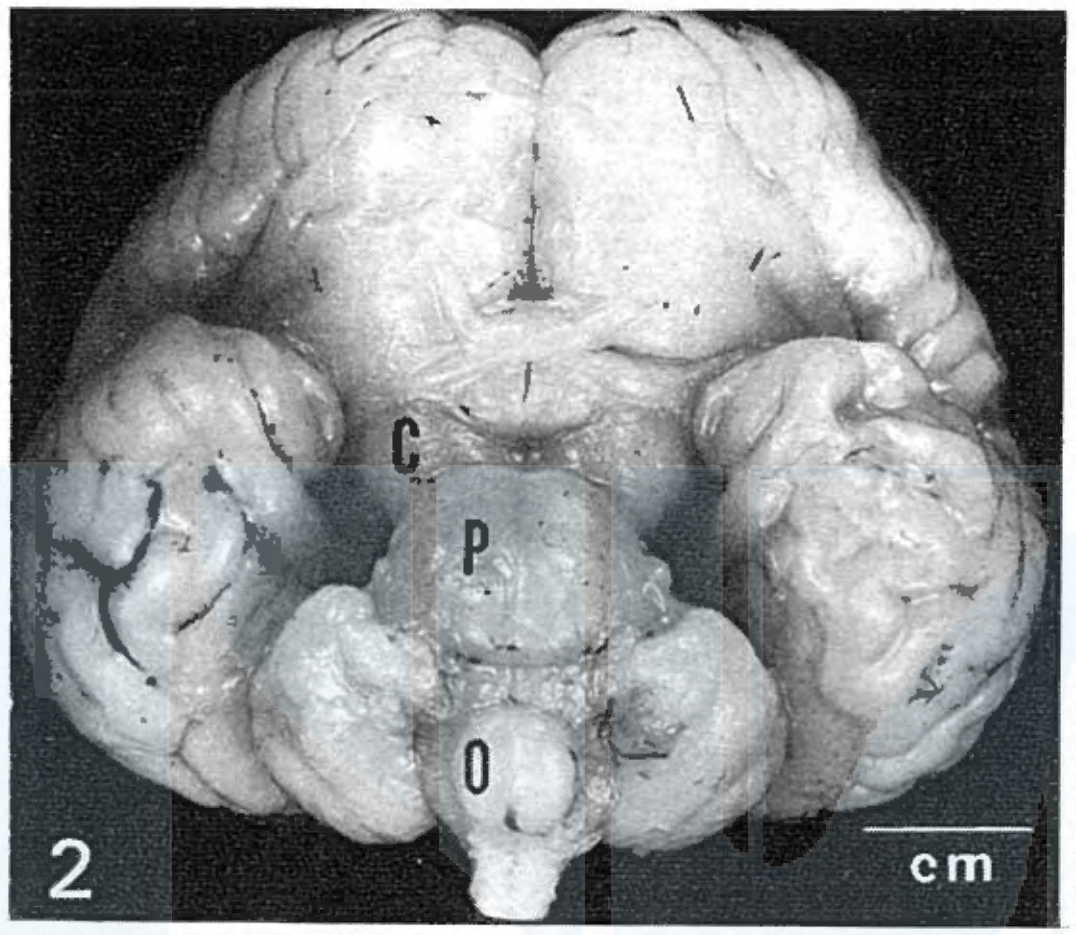

2

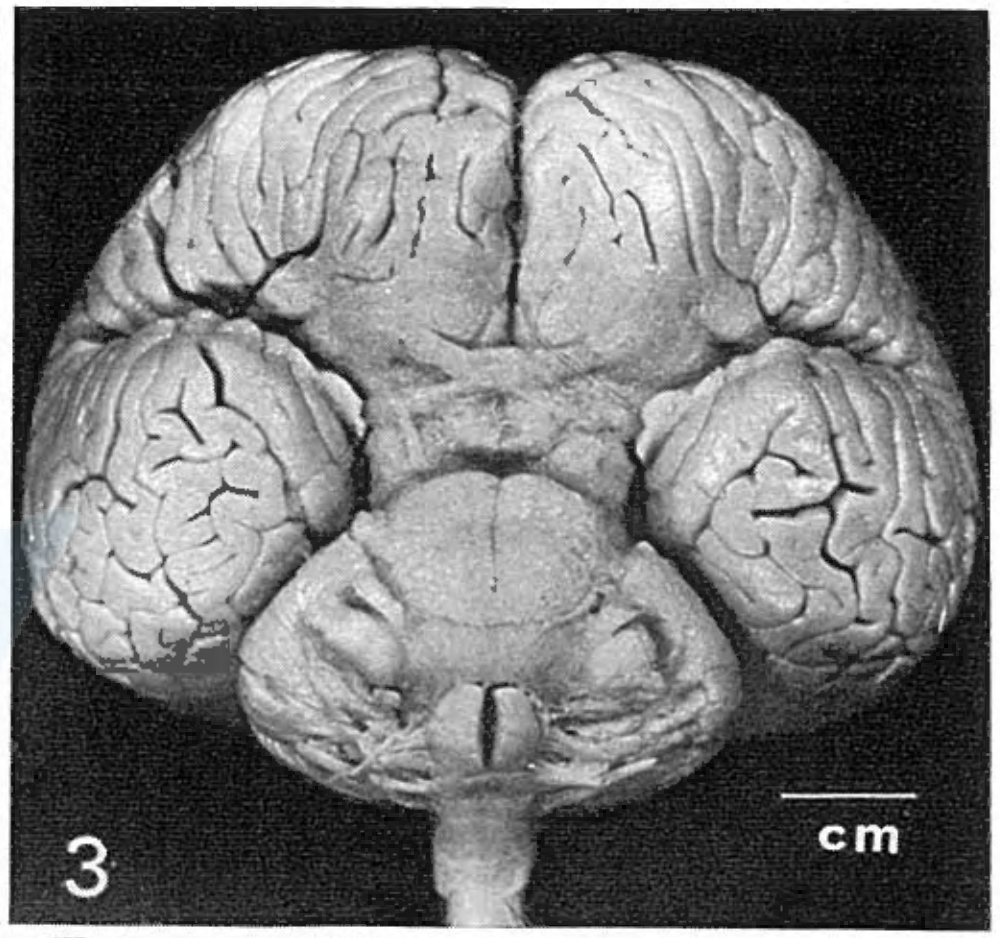

3

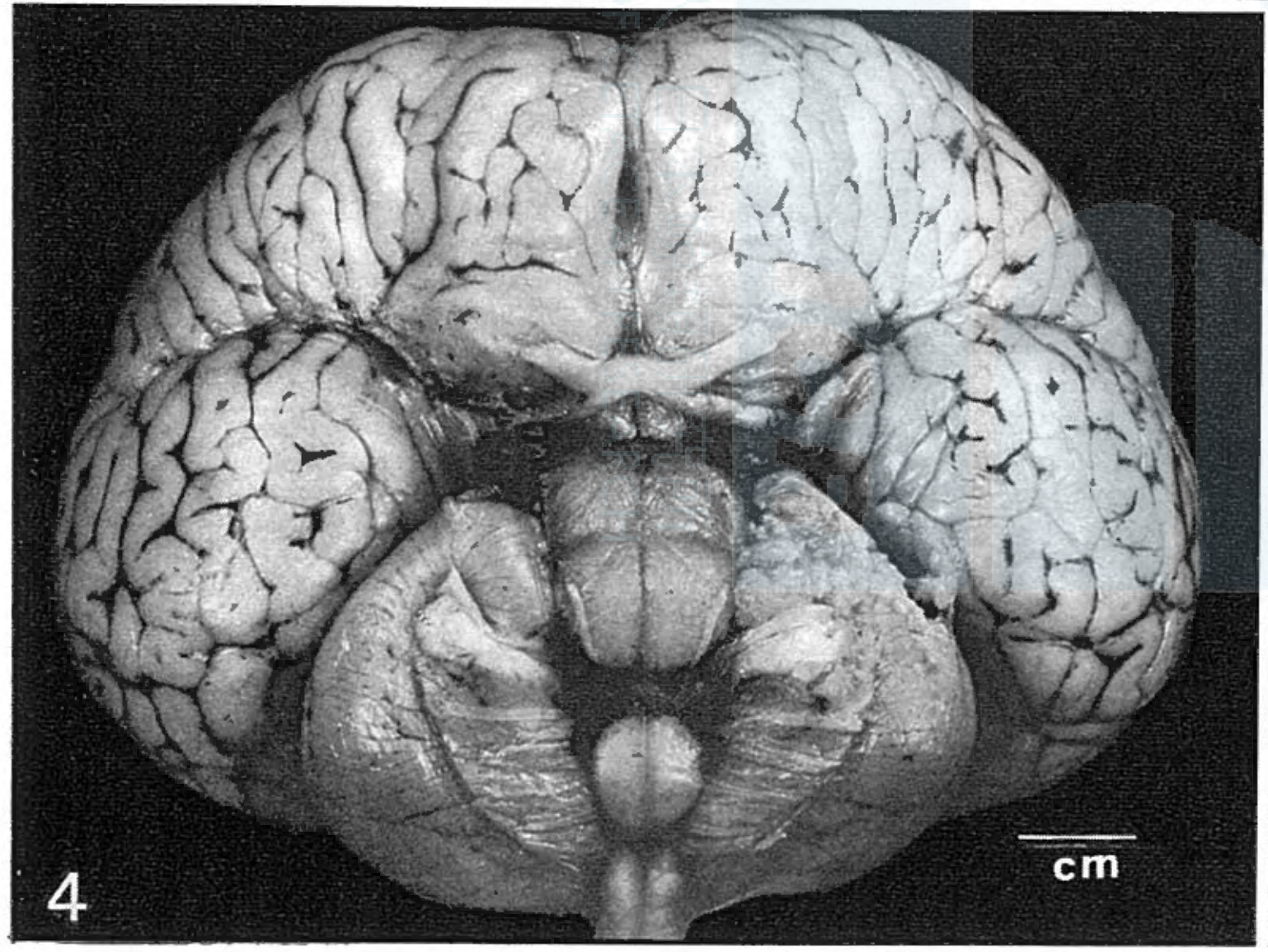

4

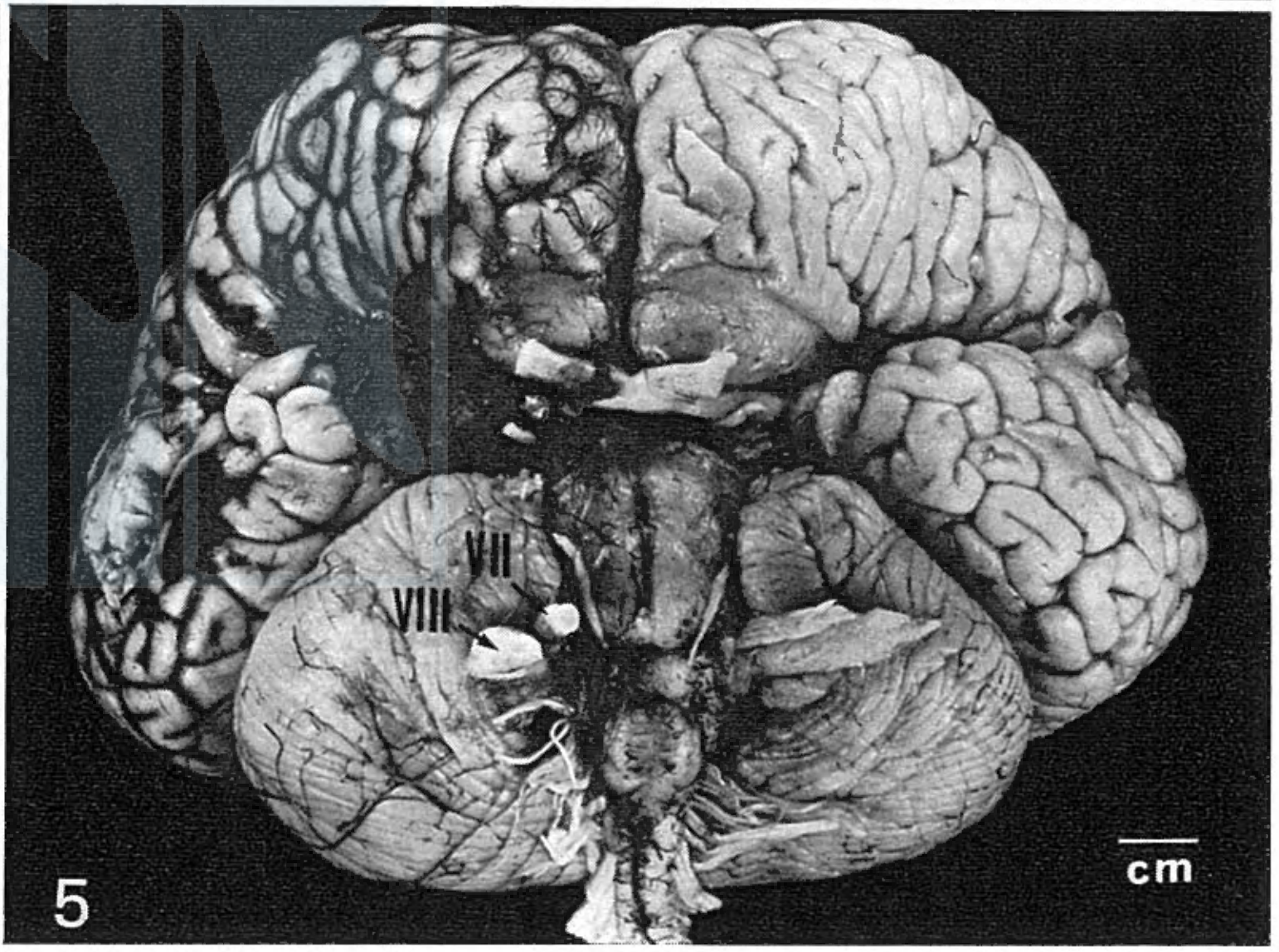

5

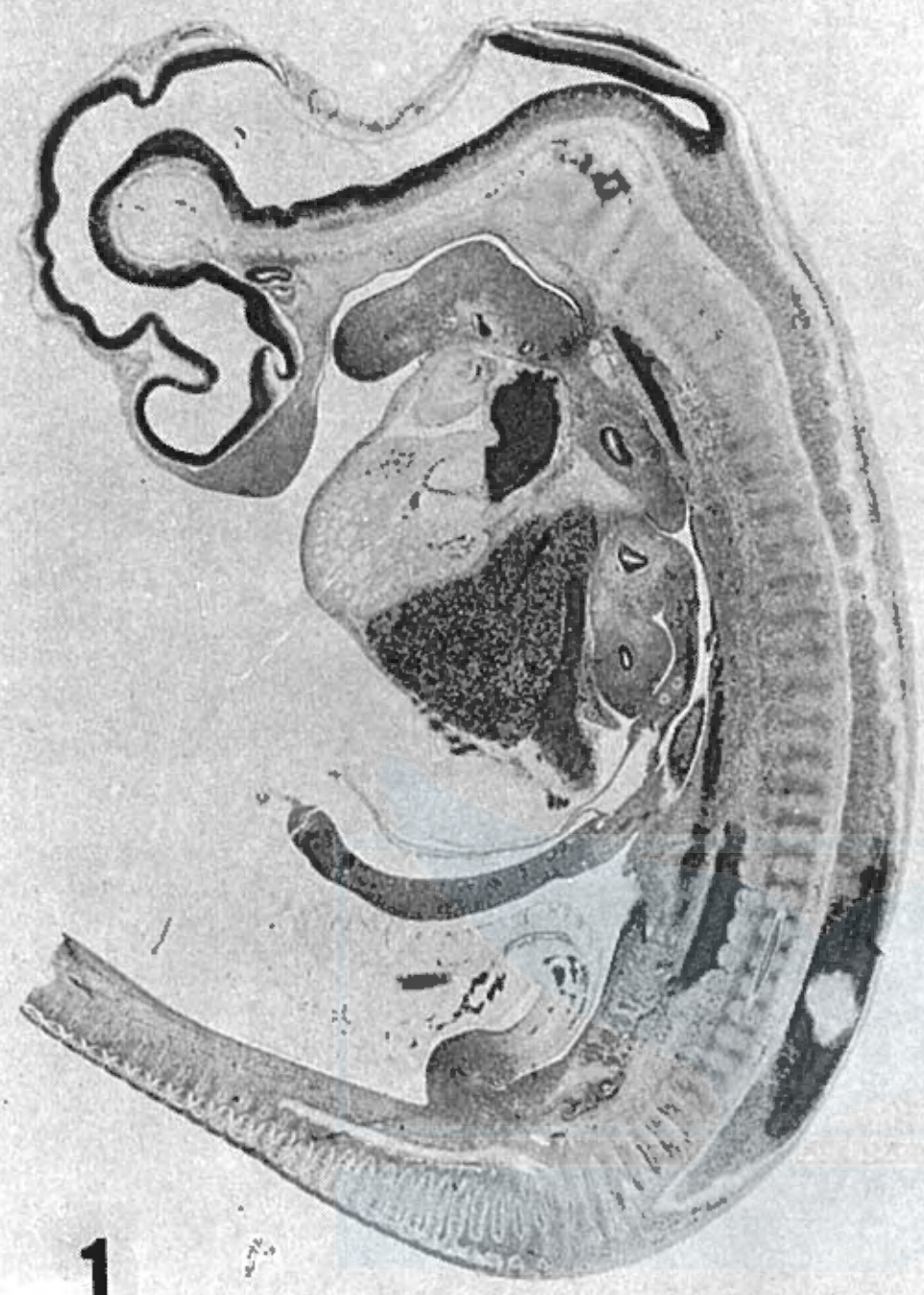

1

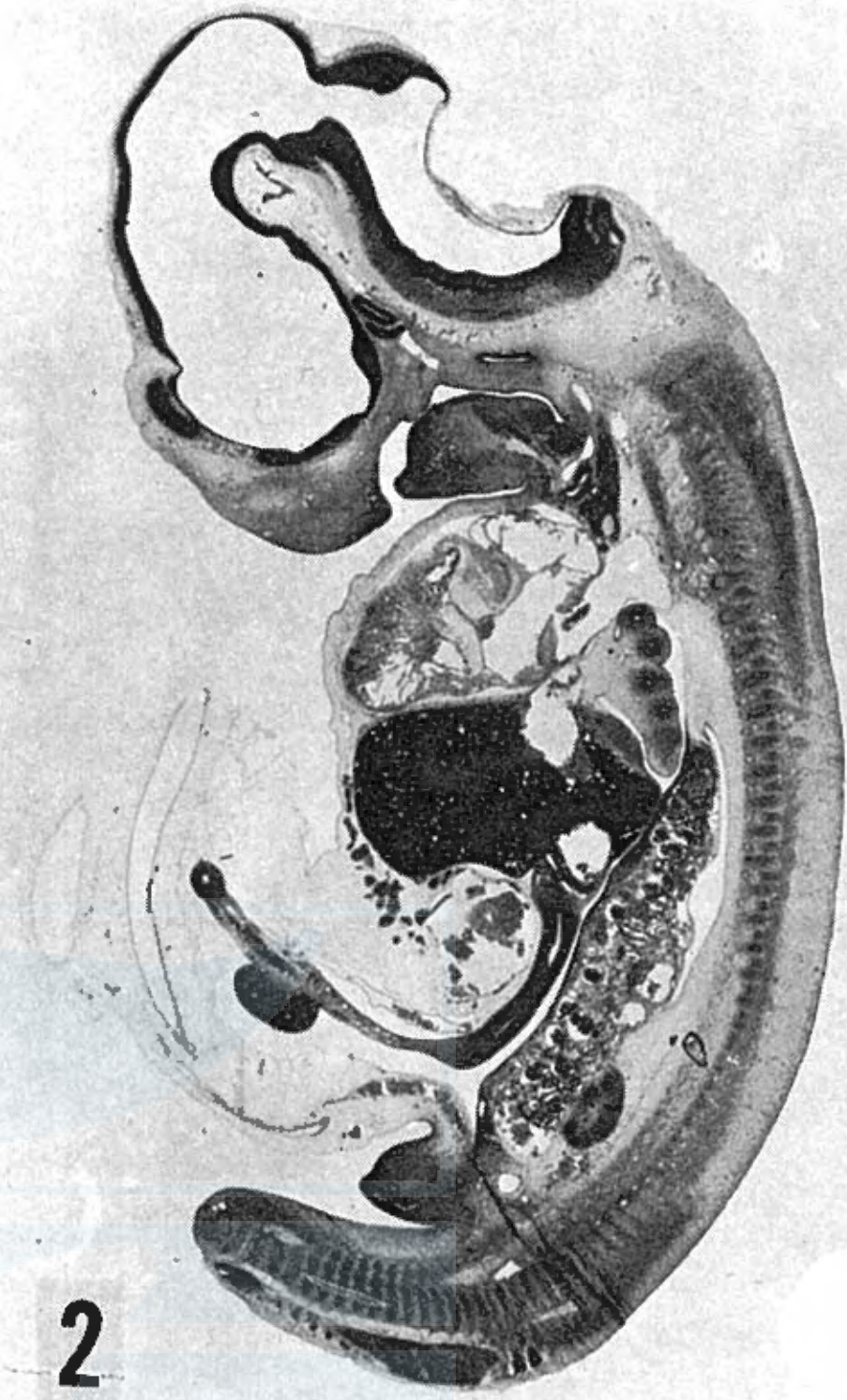

2

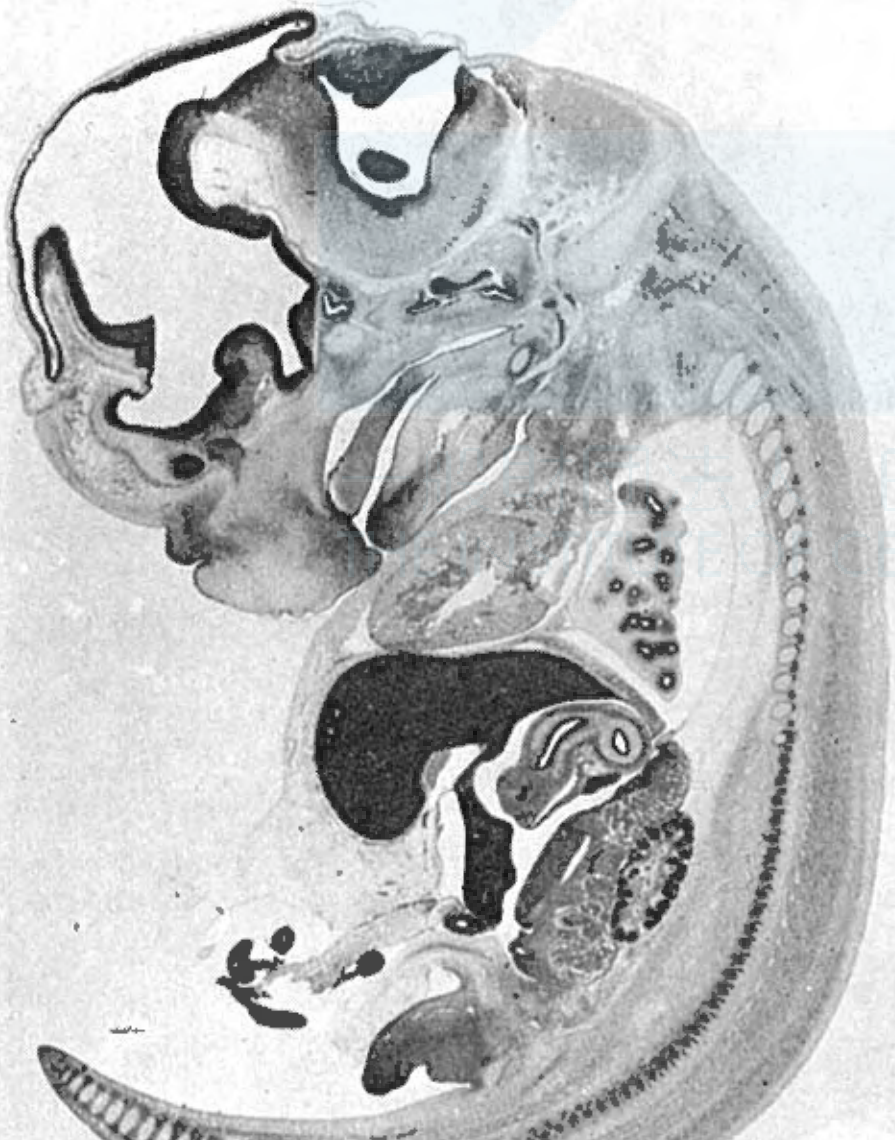

3

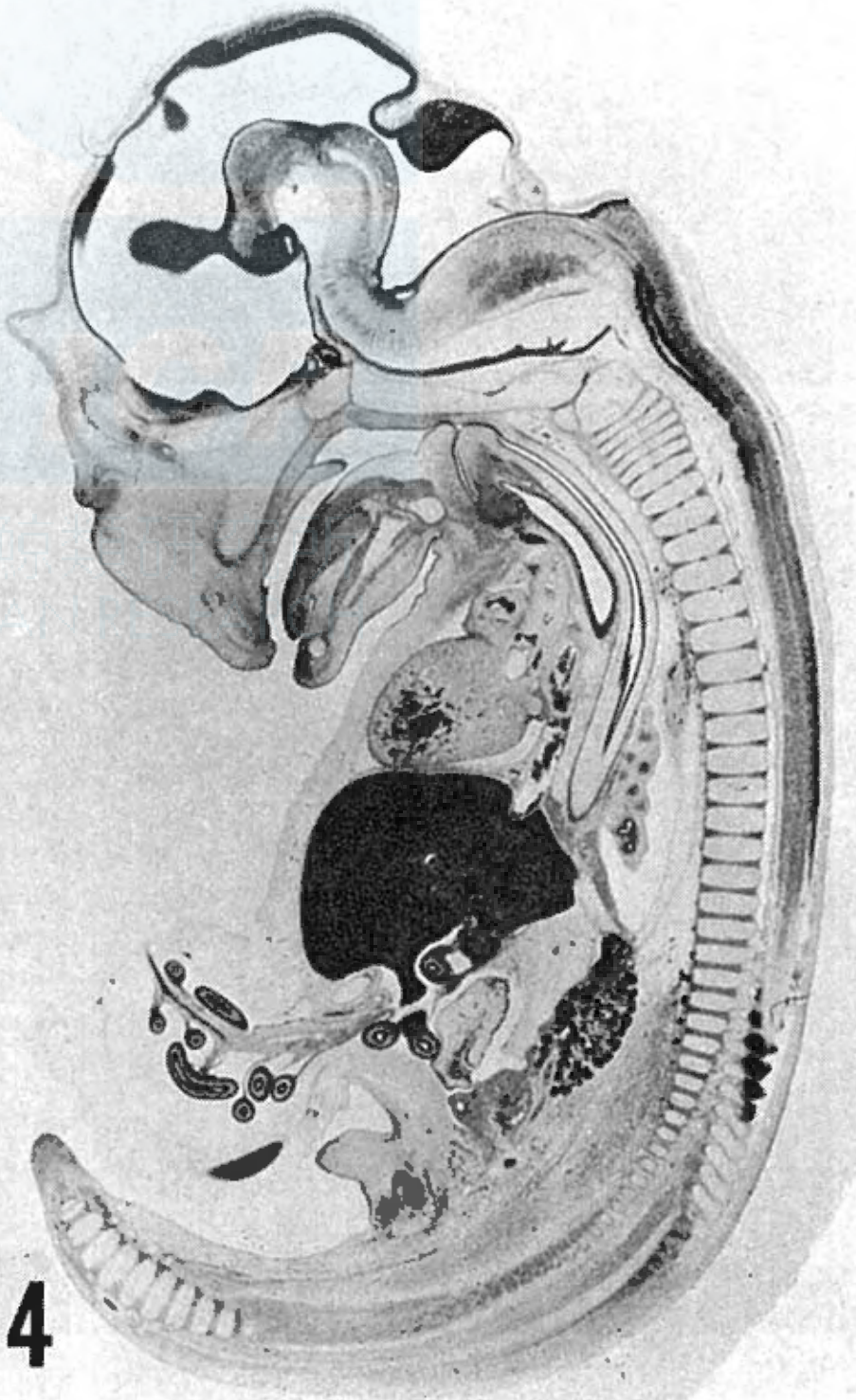

4