

# BODY SCARRING ON CETACEA-ODONTOCETES

CHARLES McCANN

8 Kiwi Street, Heretaunga, H. V., New Zealand

## ABSTRACT

An attempt is made to give some interpretation to the numerous and various scars found on the exterior of Odontocetes. Some of the scars are the result of male contests; firstly, in *play*, establishing superiority, *inter se*, between young males, and secondly, in the more serious combats to establish final *mastery* in anticipation of the breeding season for possession of an *harem*. Other causes of scarring are also discussed.

## INTRODUCTION

Opinions vary in attempts to explain the cause or causes of scars frequently visible on the body of the various species of Odontocetes. The scars may be ascribed to multiple factors, such as: parasites, epizoans, predators (other cetaceans, sharks and perhaps seals) and most of all to play and combat *inter se*. Dealing with the last mentioned factors first, it is important to consider the behaviour pattern of each species and the differences between the sexes and the type of armament (teeth) in each species. A consideration of the play and battle scars is a good indication of the extent of pugnacity exerted by the males of the species.

Most of the Odontocetes live in small or large schools. The size of the school varies largely with the annual cycles of breeding, feeding, and migration. Similar patterns are observable among land animals, as, Bovidae and other gregarious mammals; even among the primates (monkeys).

Bulls (males) engage in much combat *inter se*: at first the young in *play*, without inflicting much serious bodily harm, but with advancing age and eventual sexual maturity, the play turns to greater violence and increase of scarring—it is no longer sparring. It is in the young male schools that the future master bulls establish their superiority over all other bulls and finally become the prospective masters to challenge the ruling masters and fight to the finish or the vanquished breaks off the fight, perhaps, if not too badly wounded, to return to the fray at some distant future or perish on the waves. In the case of an old master, once he is defeated he may survive for a while and lead a solitary existence, or succumb to his wounds.

The form of the scars varies with the violence of the attacks and the extent of contact of the teeth made at the time of impact. Many of the scars appear to have been ugly wounds originally. Frequently, the wounds appear to be restricted to the depth of the blubber alone, but deeper wounds result in fractured ribs and damaged internal organs. Sometimes multiple fractures appear on the same rib

when skeletonised. The fractures not being of the same age show the endurance of the animals.

In considering the various forms of scars it is essential to refer to the dental characters, food and enemy cycles. Few Odontocetes can open the mouth widely, hence the size of the food is restricted or of soft consistency. This observation appears to have some bearing on the form of the battle scars, as we shall have occasion to note.

All illustrations showing body scarring were drawn by me.

*PHYSETERIDAE*: (Figs. 1 and 2)

Both the genera in the *Physeteridae* have markedly undershot jaws containing grasping teeth in the mandibles alone: when corresponding teeth are developed in the maxillae, they are invariably abortive and functionless. The food consists almost entirely of cephalopods—animals with a slimy gelatinous texture. The sharp teeth in the mandibles form a most efficient set of grasping teeth against the

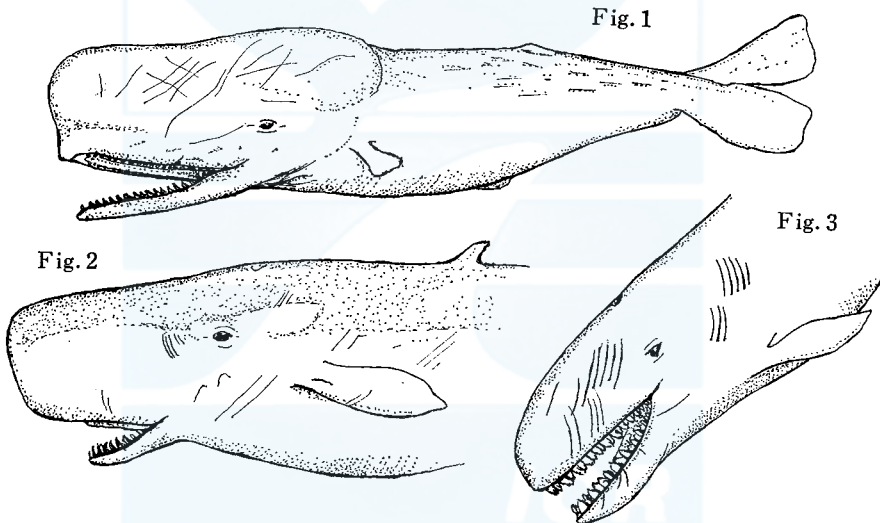


Fig. 1. *Physeter catodon* Linn. Fig. 2. *Kogia breviceps* Blainville. Fig. 3. *Pseudorca crassidens* Owen.

corresponding sockets in the maxillae left by the 'absent' teeth. The tongue is relatively short. Another remarkable feature of the family is the greatly enlarged head with its enormous 'sac' of *spermaceti*, particularly in the Sperm Whale, *Physeter catodon* Linn.

*Physeter catodon* Linn. (Fig. 1)

The enormous head of the Sperm Whale occupies almost one third of the total length of the animal. It is provided with the cushion of *spermaceti*, a waxy looking substance already referred to. To speculate, this 'cushion' functions as

a shock-absorber when the animal uses its head as a battering ram in offence and defence. In addition, the array of large teeth serve as weapons of defence and offence, and their function as grasping organs in dealing with the large slithery cephalopods (particularly, the Giant Squid) which form a large proportion of the food of Sperm Whales.

In dealing with some of the larger cephalopods, there seems to be a suspicion that the Sperm uses its head to pummel the squids after grasping them with its jaws (the fleeing squid, going backwards as is its wont, would be grasped by its tentacles). Evidence of battles with large cephalopods is impressed on the facial region of the Sperms. The use of the head as a battering ram is well authenticated in literature.

The use of the teeth in sparring and more serious battles *inter se* is exhibited by the linear scars on the head and body of opponents.

#### *Kogia breviceps* Blainville (Fig. 2)

The Pigmy Sperm Whale is similar in some respects to the true Sperm Whale, but it lacks the greatly exaggerated head. However, it possesses a small sac of spermaceti which very likely serves a similar function to that met with in the larger Sperm Whale. Its food consists largely of cephalopods. The sharp teeth in the lower mandibles only play role of grasping organs and of weapons of offence and defence. Dental scars appear on both the head and body of the combatants. The jaws appear to be used 'pigwise', the scarring depending on the number of teeth making contact at the time of impact.

#### DELPHINIDAE: (Figs. 3-10)

The Delphinidae are all provided with large or small teeth in both jaws, in both sexes: the number and size vary according to the species. In some species the anterior- and posterior-most 1-4 teeth are frequently unerupted. This peculiarity may lead to a variation in the field count. The form of teeth is a fair indication of the food—mainly fish and cephalopods; the larger species, such as the Killer and False Killer *Orcinus* (Pl. I) and *Pseudorca* supplementing their diet with larger animals—seals, oceanic birds and chunks torn out of other whales.

Delphinids cannot open the mouth very widely hence true biting is limited when faced with large objects (*i.e.* biting dog-fashion). However, dental scars, of no great depth, are frequently visible, inflicted by an opponent's teeth in 'play' or combat. These scars represent the dentition of one side of the lower jaw (mandible) only, they vary in number according to the number of teeth that made contact at the time of the impact. The movement of the jaw is somewhat like that of a pig when attacking an opponent. This form of scar is frequently seen on the head and body of stranded animals (males): *Tursiops*, *Grampus*, *Lagenorhynchus*, *Delphinus*, *Cephalorhynchus*, *Pseudorca*, *Globicephala*, and *Orcinus*.

It is well-known that the delphinids are far more gregarious and 'playful' than most other cetaceans; also, that many of the species are capable of high speeds,

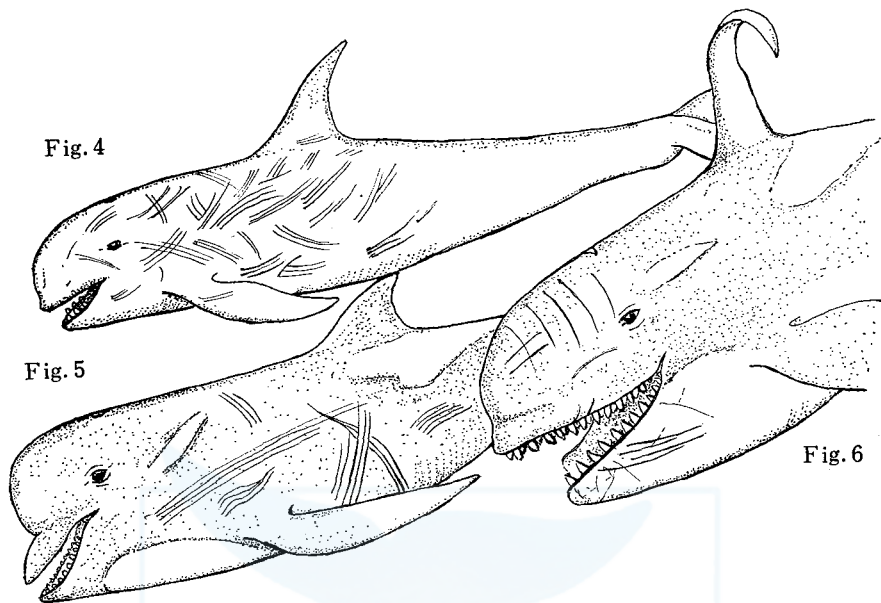


Fig. 4. *Grampus griseus* Cuvier. Fig. 5. *Globicephala melaena* (Smith). Fig. 6. *Orcinus orca* Linn.

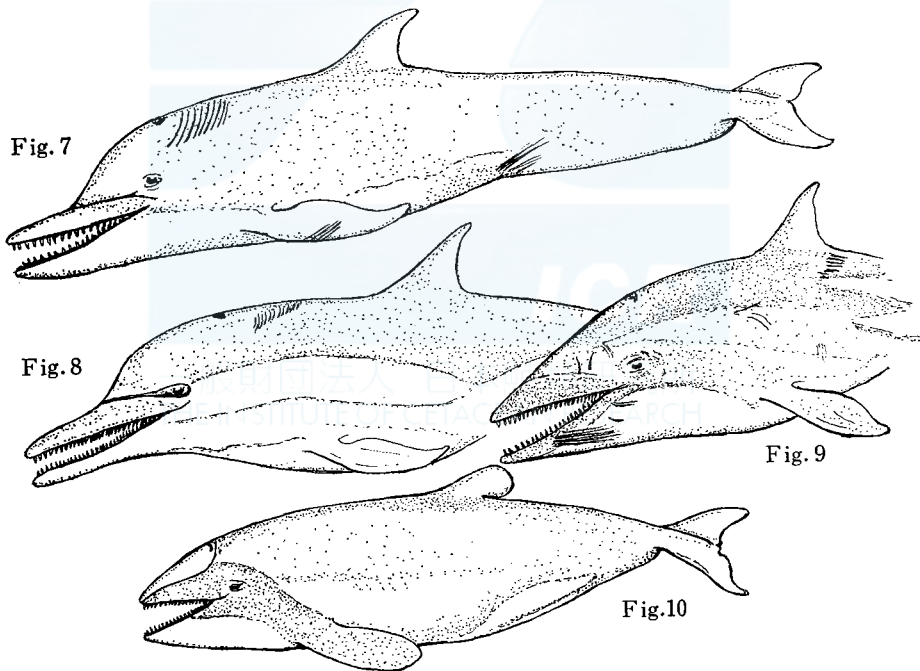


Fig. 7. *Tursiops truncatus* Montagu. Fig. 8. *Delphinus delphis* Linn. Fig. 9. *Lagenorhynchus obscurus* (Gray). Fig. 10. *Cephalorhynchus hectori* Breuden.

avoiding collision and attacks, but likewise capable of inflicting wounds on one another whether in 'play' or sexual combat. Scars arising from other causes, such as epizoans and external parasites, are not frequent with delphinids, this may be ascribed to the high speed which enables the surface of the body to remain clean.

*ZIPHIDAE*: (Figs. 11-22)

Scarring is more prevalent and pronounced among the ziphioids than the delphinids. This marked difference between the two families may be explained by the peculiarity of the dentition; smaller schools and slower speed than delphinids. Smaller schools undoubtedly give rise to a greater competition for the mastery of the harem., particularly, during the breeding period. Ziphioid males alone

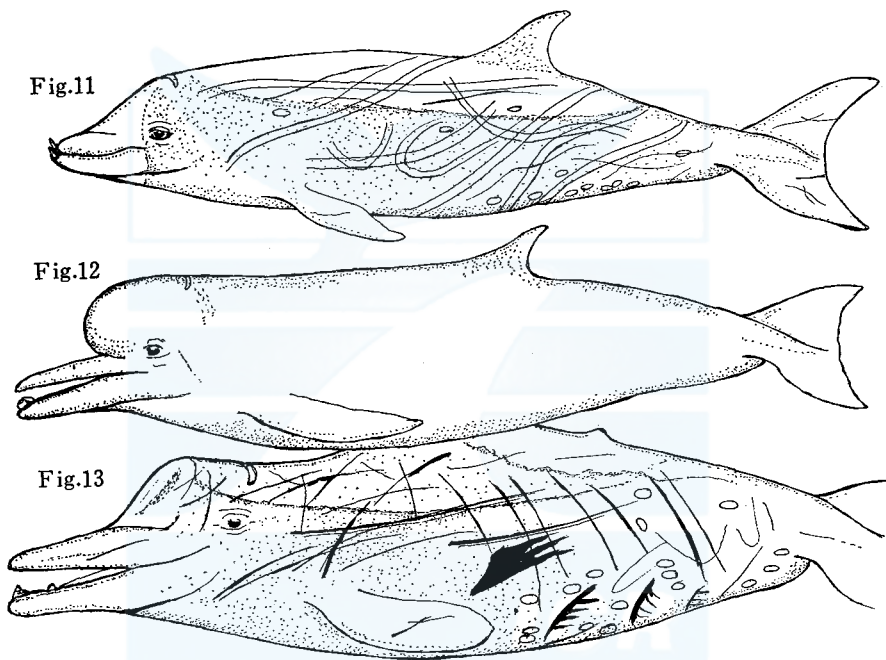


Fig. 11. *Ziphius cavirostris* Cuvier. Fig. 12. *Hyperodon planifrons* Flower. Fig. 13. *Berardius arnouxii* Duvernoy.

erupt specialized teeth for defence and offence. Teeth are found in the corresponding positions in females as those of the male but they are small- and unerupted. However, there is one exception to this general rule, *Tasmacetus*, which, in addition to the enlarged paired teeth possesses a series of smaller teeth (delphinidwise) in both maxillae and mandibles. Occasionally, one might find rudimentary teeth in the maxillae which are not embedded in the bone: example *Mesoplodon*.

In addition to the forms of linear scarring on males of *Ziphiidae* described above, ziphioids carry other forms of scarring common to both sexes. The commonest

forms of scarring being oval, elliptical or even circular. These white scars are to be seen on almost any part of the head or body, including the flukes and flippers, but they are most concentrated in the vicinity of the anal and genital regions. These scars appear to be inflicted by prolonged attachment of some stercophagous epizoans, such as, sucker-fish (*Remora*) or crustaceans. Some of the circular scars may be attributed to lampreys or hag-fish, however, the last mentioned I would regard as parasites. That the culprets which inflict the scars are seldom, if ever, (I have never come across them) taken still adhering to the carcasses of stranded individuals is quite understandable. (Hag-fish will be attracted to a carcass during the process of cutting it up, if in a suitable depth of water.) The relatively slower speed of ziphioids evidently permit of prolonged attachment of these creatures to the whales, sufficiently long to scar the delicate texture of the whale 'skin'. I have examined many such scars and found that there was no evidence of them having penetrated to any great depth below the skin.

To the forms of scars described above attention must be drawn to scars inflicted by the jaws of large fish (sharks) marine mammals (seals?) and some of the larger Delphinidae, such as Killer Whales (*Orcinus*).

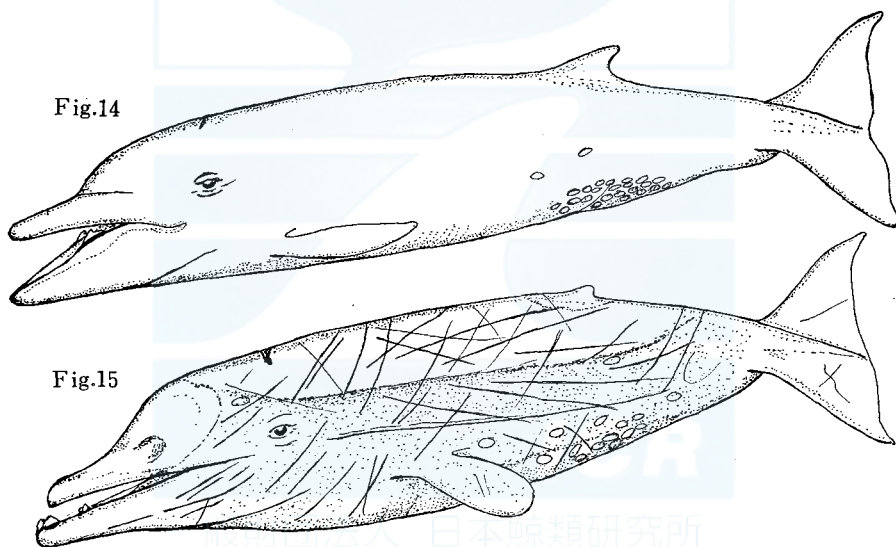


Fig. 14. *Mesoplodon ginkgodens* Nishiwaki & Kamiya (After Nishiwaki *et al.*, 1972). Fig. 15. *Berardius bairdi* Stejneger (After Omura *et al.*, 1955).

### *Ziphius cavirostris* Cuvier

This almost cosmopolitan species, like so many males in the family Ziphiidae, is virtually toothless except for a pair of defensive in the mandibles, erupted in the males alone used in sparring or battling with other males. The corresponding in the females are usually abortive and remain unerupted. The males appear to be very pugnacious *inter se* if one may draw conclusions from the numerous scars inflicted on each other by rival males. The scars appear as parallel wheals indi-

cating, in the case of *Ziphius*, that both teeth make contact together normally. The wheals are often of considerable length Pl. VI, fig. 2 and Pl. VII, fig. 1.

The food consists largely of squids. The tongue and palate are sufficiently roughened with small papillate projections to secure the soft, slithery textures, such as cephalopod's.

*MESOPLONDON*: (Pl. VI, fig. 2 and Pl. VII, fig. 1)

Excepting *M. mirus*, which has its defensive teeth at the extremity of the mandibles, like *Ziphius*, all the other species have the defensive teeth at the side of the mandibles. Accordingly, I presume that *M. mirus* alone of the *Mesoplodon* would inflict parallel scars on its opponent. Unfortunately, the only good photograph I have does not show any scarring. The other member of the genus: *Mesoplodon gervaisi*, *grayi*, *layardi*, *stejnegeri*, *densirostris* and *ginkgodens* inflict single linear scars at a time on their opponents.




Fig. 16. *Mesoplodon gervaisi* (Deslongchamps). Fig. 17. *Mesoplodon mirus* True.  
 Fig. 18. *Mesoplodon grayi* Haast. Fig. 19. *Mesoplodon layardi* Gray. Fig. 20.  
*Mesoplodon densirostris* Blainville. Fig. 21. *Mesoplodon stejnegeri* True.

#### *HYPERODON*:

There are two known species in the genus. The males of the species possess a single tooth at the extremity of the mandible, in some respects it resembles that of *Ziphius*, but may be distinguished from it by its larger size and somewhat different shape. Under the circumstances, I would expect similar parallel scarring but I

have not seen either of the animal in the flesh nor have I seen suitable photographs showing the scars. However, I presume there would be a greater distance between the lines in *Hyperodon* than in *Ziphius*.

As the female ziphioids seldom carry 'battle scars' it may be concluded that the males alone do all the fighting and in the melée may, perhaps, scar a female accidentally, which happened to be in the way.

The position of the 'battle-teeth' in the mandibles and their shape varies from species to species: the teeth may be at or near the extremity of the mandibles: between the extremity of the mandibles and the symphysis, or, yet again, nearer the angle of the gape. The wheals made by the 'battle-teeth' are almost characteristic of the species. The species with the 'battle-teeth' at the extremity of the mandibles produce long or short single or double parallel scars equal to the distance between the teeth, as in the case of *Ziphius cavirostris*, *Mesoplodon mirus* and *Hyperodon* spp. Species with single teeth in each mandible at, or posterior to the symphysis inflict deep snort or long linear scars; parallel scars may occasionally appear by accident—*Mesoplodon grayi*, *M. layardi* and others produce linear scars.

Then there is *Berardius* with two teeth in each mandible, one large anterior one and a smaller one a few centimeters behind. Close examination of the carcass of *B. arnouxii* and illustrations of the Japanese, *B. bairdi* resulted in the observation that parallel scars do not appear to be inflicted by the two anterior teeth as in the case of *Ziphius*, however, parallel scars appear which are made by both the teeth of the same mandible, with this difference: the anterior tooth makes a larger and deeper rip than the smaller: the parallel distance between the scars being much less than the distance between the two anterior teeth alone. This indicates that *Berardius* fights in much the same manner as do the side-toothed *Mesoplodon*.

Finally, there is *Tasmacetus*. I have already drawn attention to its peculiar dentition. It is a rare species and no suitable specimens nor photographs have come my way to make suitable observations on the scarring met with in this species.

#### *BERARDIUS*: (Fig. 15, Pls. IV and V)

There are two known species of *Berardius*. The males of *Berardius* unlike the males of other ziphioids possess two defensive teeth in each mandible: one large tooth followed by a smaller one, a short distance to the rear of the leading tooth. Reading the scars as they appear on the males of the individuals, three different patterns of scarring are made: a) parallel rips made by the two leading teeth alone, similar to those observed in the case of *Ziphius*: b) parallel scars, one more pronounced than the other, and closer together than those made by the leading teeth. This second form of parallel scarring is produced by the two teeth of the one mandible raking the body of the opponent at the same time, independently of the second mandible—"pigwise". In addition to these parallel scars, single linear scars may be seen gouged out by the leading tooth of one mandible alone. Further, scars similar to the segment of a wheel with short spokes, appear above and below along the ventral and dorsal margins of the caudal region. These scars appear to be inflicted large sharks or Killer Whales.



*TASMACETUS*: (Fig. 22)

This curious ziphioid is rare and little is known of it. Unlike any other ziphioid *Tasmacetus* possesses functional teeth in both upper and lower jaws in addition to the defensive teeth usually present in the mandibles alone. Oliver (1937) records 19 teeth in each maxilla and 26 (27) teeth in each mandible plus one large defensive tooth bringing the total number of teeth up to 93. (*Mesoplodon grayi* has been known to produce rudimentary teeth in the maxillae occasionally. Such teeth have no sockets but are merely imbedded in the 'gums'.)

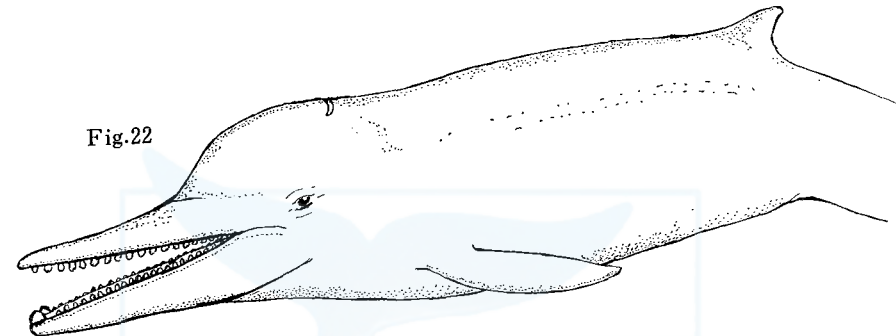


Fig. 22. *Tasmacetus shepherdi* Oliver.

Under the circumstances I would suspect that the defensive teeth at the extremity of the mandibles produce similar parallel scars as do other ziphioids with similarly positioned defensive teeth. In addition, I would suspect that following teeth would produce smaller scars, perhaps similar to some of those made by some delphinids. At the moment the subject must remain speculative.

*PLATANISTIAE*: (Fig. 23)

This small but curious family of cetaceans embraces three genera, the distribution of which is no less curious: *Inia* (Amazons), *Pantaporia* (River Plate) and *Platanista* (largest rivers of India, including Pakistan: Indus, Ganges and Brahamputra). In all cases the animals inhabit the muddy estuaries. In response to the opacity of the muddy environment, the members of the family have little or no vision. Many other adaptations have been evolved but their discussion here is beyond the scope of this paper. I will restrict my comments to the Indian species, because of the recent work done on the species by Japanese workers and my personal knowledge of some of the terrain of the species. However, I must confess that I have only seen skulls but not an animal in the flesh.

*PLATANISTA*:

A characteristic of *Platanista* is its prolonged maxillae and mandibles provided with numerous grasping teeth, like *Delphinus*. These sharp teeth, like those of *Delphinus* and *Lagenorhynchus*, leave scars similar to the series visible on the head

and body of the two species mentioned above whether made in 'play' or more serious combat. Such scars are clearly visible in the illustrations by Kasuya (1972), Pl. III. In addition to the normal form of scars inflicted on one another, other scars and wounds appear on the snout and 'face', some as though they had been inflicted by true (dog-like) biting action, others, as scars inflicted during the process of capturing prey; such as fish armed with protective spines or teeth(?).

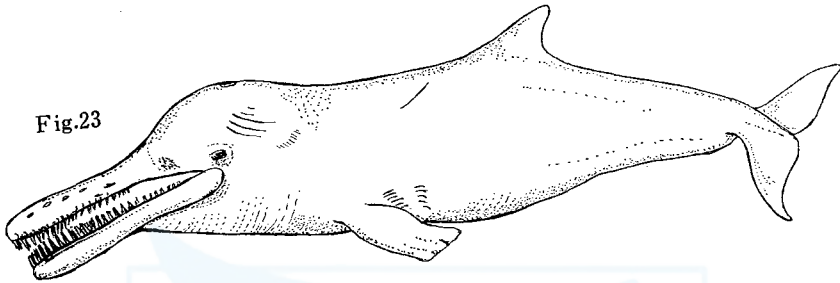


Fig. 23. *Platanista gangetica* (Lebeck).

#### REFERENCES

- KASUYA, T., 1972. Some informations on the growth of the Ganges dolphin with a comment on the Indus dolphin. *Sci. Rep. Whales Res. Inst.*, 24: 87-108.
- NISHIWAKI, M., KASUYA, T., KUREHA, K. and OGURO, N., 1972. Further comments of *Mesoplodon ginkgodens*. *Sci. Rep. Whales Res. Inst.*, 24: 43-56.
- OLIVER, W. R. B., 1937. *Tasmacetus shepherdi*: A new genus and species of beaked whale from New Zealand. *Proc. Zool. Soc. Lond.* 107, Ser. B, 371-381.
- OMURA, H., FUJINO, K. and KIMURA, S., 1955. Beaked whale *Barardius baidi* of Japan, with notes of *Ziphius cavirostris*. *Sci. Rep. Whales Res. Inst.*, 10: 89-132.

## EXPLANATION OF PLATES

## PLATE I

*Orcinus orca* Linn.

Fig. 1. Scars faintly seen on the dorsum.

Fig. 2. Scars more clearly visible about the head and jaws.

## PLATE II

*Delphinus delphis* Linn.

Series of teeth marks on the dark area of the dorsum.

## PLATE III

*Lagenorhynchus obscurus* (Gray)

Fig. 1. Scars clearly visible about the mandible and around the eyes.

Fig. 2. Scars seen about the region below the dorsal fin.

## PLATE IV

*Berardius arnouxii* Duvernory

Fig. 1. Head on view showing dorsal and lateral scarring.

Fig. 2. Lateral view showing scars, old and new: at the lower edge, note scar possibly inflicted by 'Killer' Whale.

## PLATE V

*Berardius arnouxii* Duvernory

Fig. 1. Caudal region, note the several attempts of 'Killers' or perhaps sharks.

Fig. 2. Note the various types of scarring below the dorsal fin.

## PLATE VI

*Ziphius cavirostris* Cuvier

Fig. 1. Dorsal view.

Fig. 2. Closeup of dorsum showing dorsal fin and scars, single parallel and elliptical scars.

## PLATE VII

*Ziphius cavirostris* Cuvier

Fig. 1. Ventral aspect showing vent and genital apertures together with the associated scars.

*Mesoplodon grayi* Haast.

Fig. 2. Ventral aspect showing vent and genital openings with the types of scarring.

## PLATE VIII

*Globicephala melaena* (Smith)

Dorsal aspect showing the numerous series of scars inflicted by the teeth of the opponent.




Fig. 1.





Fig. 2.



一般財団法人 日本鯨類研究所  
THE INSTITUTE OF CETACEAN RESEARCH




Fig. 1.




Fig. 2.




Fig. 1.



Fig. 2.



Fig. 1.

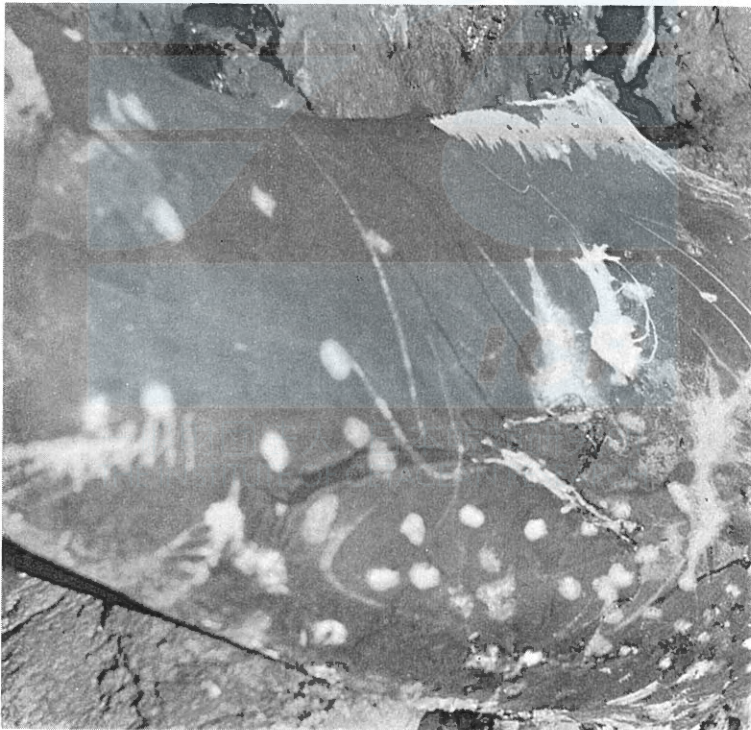


Fig. 2.





Fig. 1.




Fig. 2.

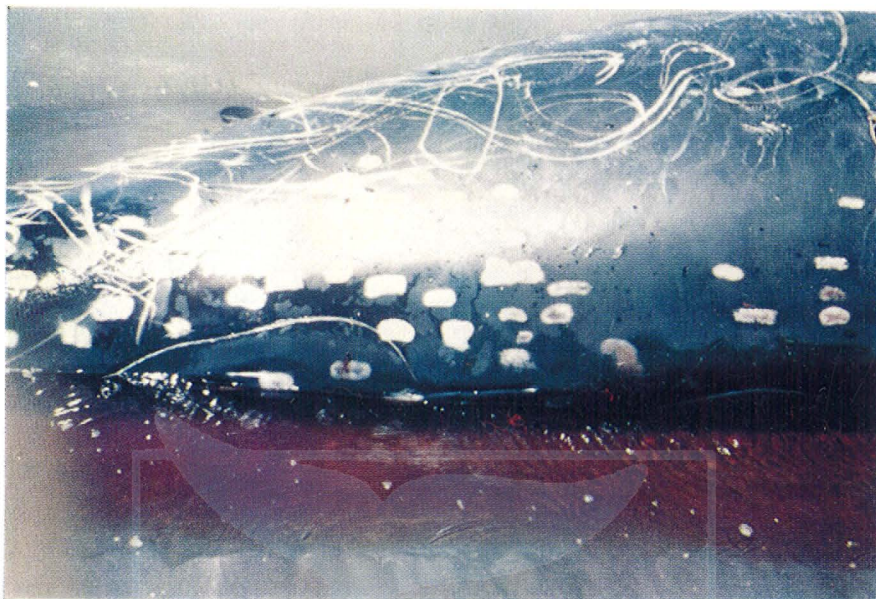


Fig. 1.



Fig. 2.



一般財団法人 日本鯨類研究所  
THE INSTITUTE OF CETACEAN RESEARCH