

FORMATION MECHANISM OF EAR PLUG IN BALEEN WHALES IN RELATION TO GLOVE-FINGER

TADAYOSHI ICHIHARA

INTRODUCTION

Since the important paper of the ear plug in the Mysticeti was contributed by Purves (1955), the relations between the ear plug lamination and the other valuable age characters have been researched in several papers, Laws & Purves (1956), Nishiwaki (1957), Symons & Weston (1958), Nishiwaki, Ichihara & Ohsumi (1958) and Purves & Mountford (1959). In particular the valuable suggestions are given in the last two papers which are described based on a great numbers of ear plug from the fin whale. The comparisons of the biological information from the lamination counting with that from the baleen plate reading in the young stage and with that from the corpora counting in the ovary of female whale have confirmed the validity of lamination numbers of ear plug for the age determination as seen in the papers mentioned above.

However, the accurate rate of annual increment of laminae is necessary to advance the whale biology and it finally should be checked by the marking experiment and so on to avoid the interpretation favoured by individual scientists.

As another approaching method to know the increment rate, it remains the fascinating problem when the alternation of the dark and light band occurs in the plug core in response to the internal physiological rhythm of whale body. In the course of study on this subject, it was necessary that the glove-finger and the ear plug were examined in detail morphologically and histologically. In this paper the several supplemental informations for the previous works are obtained from the external observation of the glove-finger and the ear plug. With regard to the formation mechanism of ear plug, new findings are given from the histological study. Any conclusive comment is not given in this paper to the reason why the alternation of bands occurs in the ear plug. Such a reason should be explained in the future research.

I am indebted to Dr. Hideo Omura, the Director of our Institute, for his encouragement throughout this work. My sincere thanks are due to Dr. Hiroshi Hosokawa and Mr. Toshitomo Shida, the Department of Anatomy, Faculty of Medicine, University of Tokyo, for their kind helps and valuable suggestions in the histological study. I am also indebted to

the inspectors and the staffs of the whaling companies, too numerous to name here, who collected many materials for the Whales Research Institute.

MATERIAL AND METHOD

Numerous ear plugs have been collected on the deck of the Japanese floating factory ships in the Antarctic Ocean and the northern part of the North Pacific since 1956. Fin whale plugs occupied the most part of these specimens which were preserved in 10% formalin solution soon after collection. The ear plugs from the blue, humpback and sei whale were preserved in the similar way. The humpback whale plugs off Okinawa Island were collected from January to April in 1959. A few specimen from the Bryde's whale and the minke whale also have obtained from the Japanese coastal land stations, with the fin whale plugs from the East China Sea.

Although the laminations of all plugs were counted, the morphological study in this paper mainly dues to 662 fin whale plugs from the northern part of the North Pacific in 1957 and 1958. Under the imperative necessity of explanation, the numbers were complemented by the plugs from the fin whale in the other waters and from the other species.

With these ear plugs, the glove-fingers were collected from the various whales of different localities but they are in less numbers than the ear plugs. 165 glove-fingers were used for the present purpose. In the present histological study, the blocks of specimens from the various species were embedded in paraffin in the first trial, however, this method was not suitable for the preparation of section. Therefore, the blocks of specimens were prepared in the celloidin and frozen section in the second step. Finally the celloidin section suited for the hard materials like the glove-finger and the frozen section did for the soft materials like the ear plug. In such ways, the various parts from the specimens were sectioned in the thickness from 10 to 15 μ .

After sectioning the specimens, the several staining methods were tried; haematoxylin eosin, Heidenhain's iron haematoxylin, AZAN, SUDAN III etc. In particular, haematoxylin eosin and SUDAN III staining were applied for the study on the formation mechanism of ear plug. Photomicrographs were taken from the numerous sections and some of them are illustrated in plates.

SIZE AND TYPE OF GLOVE-FINGER

Penetrating the thick blubber, the external auditory meatus of the

baleen whales goes along the squamosal region of the skull, ending at the glove-finger structure connecting the tympanic bulla with the triangular ligament. Glove-finger had been believed by many whale biologists as the tympanic membrane until Fraser & Purves (1954) have suggested that in the course of study on the conductivity of sound, the triangular ligament mentioned above corresponds to the tympanic membrane. In baleen whales, the glove-finger projects outwards into the external auditory meatus, having the slightly flattened shape in vertical direction and the elongated, hollow conical structure in general. At its outer convex end it is capped by the ear plug. Its position and its relation to the ear plug were illustrated concretely in text-figure 1 in Purves' paper (1955). Since the glove-finger is closely associated with the formation of ear plug in the auditory meatus, it is necessary to note glove-finger first of all remarks on the shape of ear plug.

In the course of taking the ear plug from the whale head, it is often detached from the outer surface of glove-finger. This detachment, being usually seen more frequently in the young whale than in the old one, sometimes depends on the plug shape coating the curved, extremity of glove-finger and sometimes to the shape of papillary layer existing in the corium of glove-finger. The numerous papillaries often project from the outer surface of glove-finger to enter the column of tissue of the ear plug. Detailed description on this connection appears later in this paper. The thick membrane-like glove-finger shows usually the white, yellowish white colour and sometimes the slightly smoke-stained white colour. In the longitudinally bisected specimen many capillaries are seen embossed on the internal surface of the glove-finger. This observation implies presumably the abundant blood vessels exist in the glove-finger.

On the size of glove-finger several descriptions have seen until now. Kellogg (1928) has stated that the glove-finger of humpback whale is $3\frac{1}{2}$ inches long and it is flexible in the fresh material. It has been described by Hinoura (1938, '41, '43) that the thickness and size of the membrane-like glove-finger is a little different from species to species, however, it is from 2.0 mm to 5.0 mm thick in the various baleen whales. He has furthermore concluded comparing the sizes of glove-fingers from 5 species in baleen whales that the minke whale and sei whale possess the glove-finger of about the same size, 5.0 cm in length, and the fin and blue whale have a little more large ones and at any rate the humpback whale possesses the most large one of 8.0 cm in length and 3.0 cm in the greatest breadth. Yamada (1948) has shown the glove-finger projects outwards about 6 cm into the external auditory meatus in the Antarctic fin whale. In Burne's cetacean dissection (1952) it has

been suggested the glove-finger in large baleen whale some $2\frac{1}{2}$ -3 inches long in the protruding part.

Fig. 1 indicates a close relationship between the length of projected glove-finger from the tympanic bulla and its greatest breadth. Most of examined specimens consist of 53 fin whales from various localities and their mean values are indicated in the left side, suggesting the linear relationship is suitable in two kinds of measurements. Records from one northern blue whale, one humpback whale from Okinawa waters and one Bryde's whale from the coast of Japan also are plotted, being situated near the straight line. Furthermore to the right side

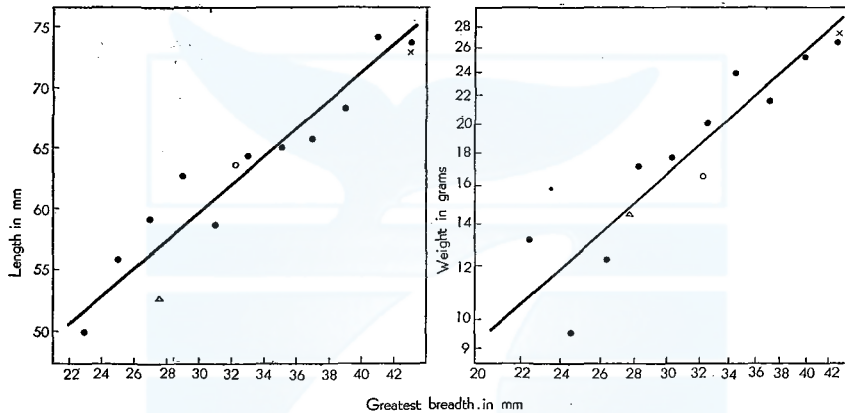


Fig. 1. Relation of length and weight to greatest breadth of glove-finger. Length indicates the projected part from the tympanic bulla. Fin whale, mean values; other species, single records. ● Fin whale, × Blue whale, ○ Humpback whale, △ Bryde's whale.

in Fig. 1 mean glove-finger weights at different greatest breadth are plotted on a double logarithmic scale for the fin whale. Records from blue, humpback and Bryde's whale are added near the assumed straight line. Although the small numbers of records give a great variation in the lower range, the linear relationship between the weight of glove-finger and its greatest breadth is assumed. In the examined specimen, the maximum length of glove-finger is 84.8 mm and its minimum length is 51.0 mm. The range of weight covers 31.4 gr from 7.5 gr, four times increase as compared with a less than twice increase in the greatest breadth (22.4 mm to 42.4 mm). The mean thickness of membraneous glove-finger is 3.17 mm for 21 fin whales, being 3.16 mm for 5 blue whales and it is 3.50 mm for 8 humpback whales, however, these values do not seem to be so accurate since the measurement is difficult in the

specimens of markedly projected papillae. The thickness varies from one specimen to another and its range is from 2.0 mm to 5.0 mm.

In general my finding for the size of glove-finger is compatible with the previous works mentioned above, however, it must be emphasized that all findings in the previous paper are due to the small numbers of glove-finger. Hinoura is the first person who has compared the sizes of glove-finger from various baleen whales as far as I know. His finding should be corrected in respect of the ranking of size. I disagree with his interpretation on the minke whale examined, judging from the external character of that whale.

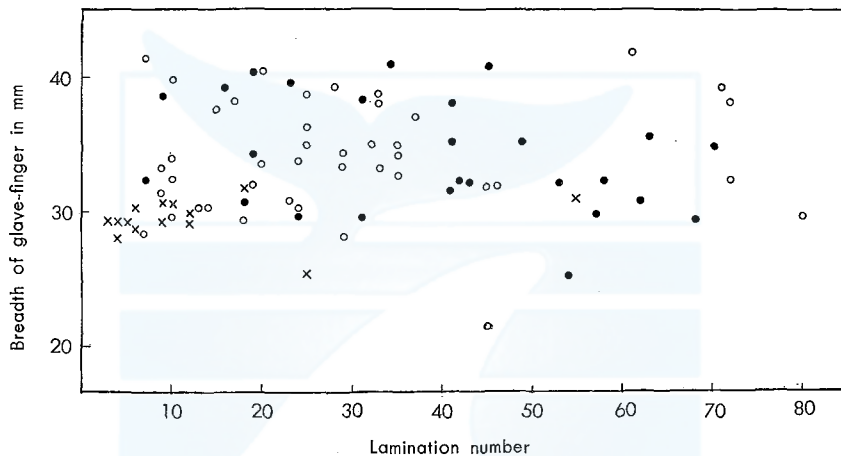


Fig. 2. Relation between greatest breadth of glove-finger and age of fin whale in three localities. × East China Sea, ○ Northern Pacific, ● Antarctic.

In relation to the life-history of whale, Purves (1955) has suggested that in view of its association with the tympanic annulus and its importance in regulating the tension of the tympanic ligament, it may be assumed that the glove-finger also remains constant in size throughout the life of the animal. Certainly Purves' suggestion must be taken up here and confirmed, because there is a close association between the size of outer part of the glove-finger and the size of core of the ear plug. In this connection, the study is started from whether the size of glove-finger changes or not at the increasing age of whale. Since the glove-finger shows the curious form, it is so difficult to express its size as dimensions. So far as the breadth of core of ear plug concerns, the greatest breadth of glove-finger becomes the best expression in dimensions. With regard to the age of whale, there is no justification to reject the lamination number seen in the plug core is an excellent age character according to Nishiwaki, Ichihara & Ohsumi

(1958), Purves & Mountford (1959), even if no method has yet been standardised on the annual increment of lamination as Chittleborough & Godfrey (1957) and Symons & Weston (1958) have pointed out.

In Fig. 2 the greatest breadth of glove-finger is plotted against the lamination number. The specimens used here are collected from the fin whales in three localities—the East China Sea in 1958, the northern part of the North Pacific in 1957 and the Antarctic Ocean between 1956 and 1958. In the range from 3 to 80 of lamination, the greatest breadth

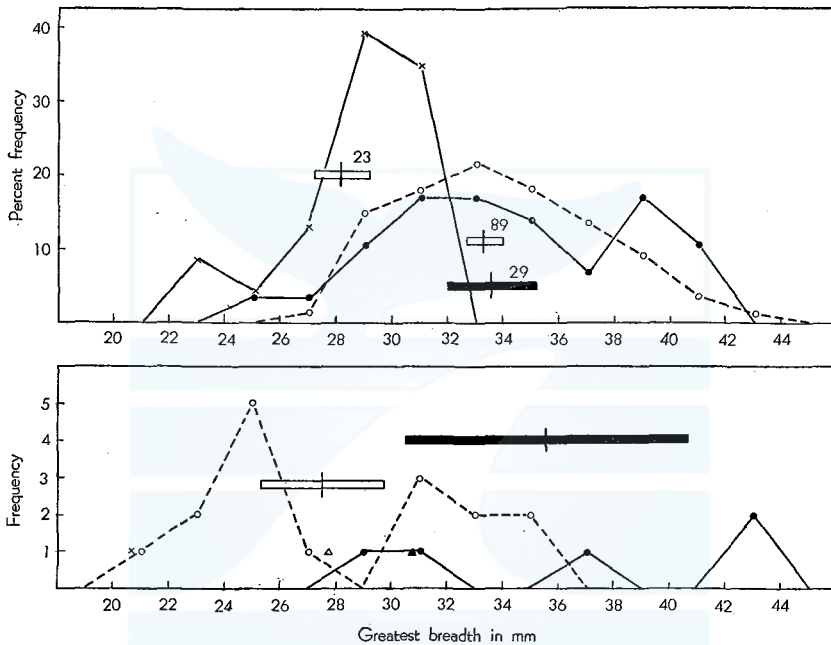


Fig. 3. Frequency distribution of greatest breadth of glove-finger. The means and two standard errors are indicated. Above: On the fin whale in three localities, \times — \times East China Sea, \circ --- \circ Northern Pacific, \bullet — \bullet Antarctic. Below: On the other baleen whales, \circ --- \circ Okinawa humpback whale, \bullet — \bullet Northern Pacific blue whale, \blacktriangle Northern Pacific sei whale, \triangle Bryde's whale, \times Minke whale.

of glove-finger does not show the increasing character with age, varying from one specimen to another. This fact implies the glove-finger remains constant for one species from the birth to the end of whale life, confirming Purves' suggestion. It is of interest to note the fin whale of the East China Sea possesses smaller glove-finger than those of the North Pacific and the Antarctic. It is interesting incidentally that the breadth of glove-finger does not show the significant difference between the male and the female fin whale in one locality, and it is found conclusively in the other baleen whales.

Since a morphological character of constant size, in no relation to the increasing age, often becomes a clue to the study of subpopulation, I collected the glove-finger from the various baleen whales to measure its greatest breadth. The frequency distributions of the greatest breadth are found in Fig. 3 in which the means and two standard errors are indicated for each group of whale. Since the data contain the glove-finger from of which ear plug is detached and missed, the numbers of specimens become a little larger as shown in Fig. 3 than in Fig. 2. On the fin whales as explained in the figure, the breadth from the North Pacific group is in almost the same range as that from the Antarctic group. In this group the breadth is 33.7 ± 1.54 mm (means and two standard errors) and in that group it is 33.3 ± 0.74 mm. It is evident no significant difference is found between both group. While, in the East China Sea group the breadth is as small as seen in the figure and 28.2 ± 0.99 mm, being different significantly from the other two groups. It has been pointed out by Mizue (1956) that the fin whale of the East China Sea matures sexually at the smaller size than that of the northern part of the North Pacific by about 2 feet. Besides Mizue & Fujino (1957) have suggested the shape of baleen plate is different between both areas. Furthermore Ichihara (1957) have concluded that the external shapes of the whales from both areas are significantly different and suggested that the fin whales are divided from the external proportion into two areas with mathematical foundation. Occurrence of smaller glove-finger in the East China Sea may be taken as the other explanation on the locality of the fin whales there in addition to findings mentioned above, and on this subject further studies of subpopulation are needed as pointed out by Omura, Fujino, Ichihara, Kimura (1958).

Since the collections of glove-fingers from the other baleen whale are not so large, their distributions are seen as the frequency number in the lower part of Fig. 3, in which the means and two standard errors are indicated for the northern Pacific blue whale and for the humpback whales near Okinawa Island where the whaling has been operated in the winter season since 1958. In the group from 5 blue whales, the greatest breadth of glove-finger is 35.6 ± 5.12 mm and in the group from 16 humpback whales it is 27.5 ± 2.24 mm. It is suggestible from these means and two standard errors that the breadth differs significantly between these two groups, although the indicated specimen is small in number and the overlapping area is seen between two frequency distributions. Kawakami & Ichihara (1958) has made clear from the evidence of whale marking that the humpback whales off Okinawa Island migrate as far as Alaskan waters in the north-eastern part of

North Pacific. Accepting this clearness the glove-finger of the humpback whale living in the northern part of the North Pacific is inferred to be the same in its greatest breadth as that of the Okinawa humpback whale.

The frequency distribution of glove-finger of the humpback whale shows seemingly the bimodal curve, which is based on the small numbers of materials collected. As regards the sei whale and Bryde's whale, the only one glove-finger is obtained from the adjacent waters to Japan and its breadth is as medium as 30.7 and 27.7 mm respectively. One specimen from the minke whale captured in the Okhotsk Sea is as small as 20.9 mm in its breadth. The glove-finger of blue whale seems to be a little larger than that of the fin whale.

In relation to the shapes of laminae seen in the ear plug, the type of glove-finger must be noticed. The present type of glove-finger is dependent upon the shape of papillae seen in its corium. In the course of study on the glove-finger of blue whale, the great numbers of papillae are observed in naked eyes to project remarkably outerwards from its surface. All examined specimens from the blue whales have the protruding papillae of which parts are as long as about 5 mm and marked at the curved extremity of glove-finger. These papillae go into the tissue of ear plug covering them, therefore, the ear plug being compacted between one papilla and the neighbouring one. It was described previously in this paper the detachment of ear plug from the glove-finger partly depended on the shape of papillae layer. This statement are supported here by the fact that the collected glove-fingers sticking to the ear plugs usually make the papillae projecting into the plug.

With regards to the glove-finger of fin whale, its type may be divided into three groups. In the first group, the papillae project conspicuously outerwards from the surface of glove-finger like the blue whale. In the second, they project moderately and are not so many in numbers as in the first group. In the third group, they are not so protrudent that the surface of glove-finger looks smooth. These three types of glove-fingers from the fin whales are shown in Plate I, Fig. 1 with the glove-finger from the other baleen whale. The curvature of the distal end of glove-finger effects on that of the laminae of ear plug, varying from one specimen to another, however, it is effectless on the type of glove-finger. According to the grouping method into three types the percentage of the first group is as low as 13.4 and that of the second group is as medium as 32.8, that of the third group being as high as 53.8, in 89 glove-fingers from the northern Pacific fin whales. These percentages show the papillae of the fin whale glove-finger usually are not so protrudent as those of the blue whale. This finding

may be supported from the view of the proximal end of ear plug as indicated in Fig. 4.

In the most case of ear plug collection, ear plugs detach from the outer surfaces of glove-fingers but the borders between both materials are kept well in the formalin preservation. From the detailed observation it is confirmed that the epithelium of glove-finger remains at the proximal end of ear plug, where the type of papillae of glove-finger are observed indirectly. Supplying the small numbers of the glove-fingers, 662 ear plugs from the North Pacific expeditions in 1957 and 1958 are used for this survey and the percentage frequencies of three types are plotted against the lamination numbers in Fig. 4. The second

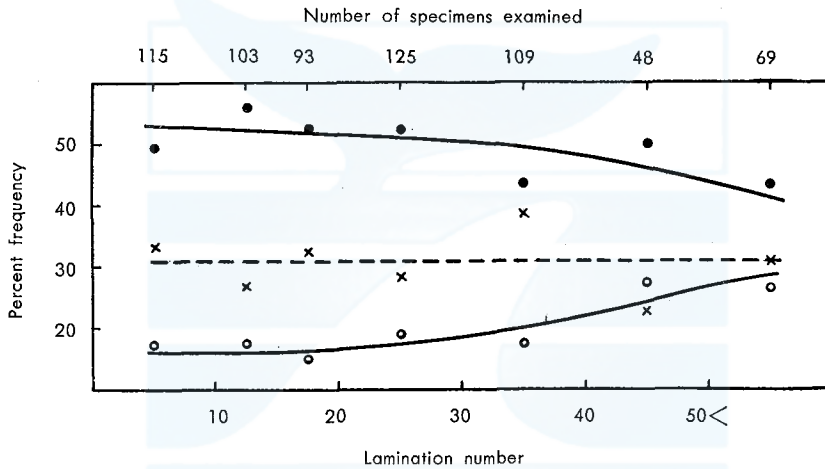


Fig. 4. Percentage frequency of three types of fin whale glove-finger observed indirectly from ear plug, at increasing lamination number. ●—● papillae not projected, ×---× medium type, ○—○ papillae projected markedly.

type occupies about 30 percentages in all specimens and the comparatively constant level from the young to the old. While the first type of the remarkably projected papillae shows the percentage below 20 in the young and characteristically indicates increasing percentage from the young to the old. With regard to the third type, its percentage falls with the increasing age to the contrary of the increasing percentage in the first group. Over 50 laminations, the first and third group approach to the second group in their percentage. This interesting finding suggests the projection of papillae of glove-finger grows higher and higher from the young to the old and finally three types occur in almost the same frequencies in old whales. It is supported by the shapes of laminae seen in the core of ear plug as described later, how-

ever, the occurrence of the first type in the very young whale should be noted.

In the one specimen from the sei, Bryde's and minke whale respectively, the papillae are not protrudent, belonging to the third group. Three types appear in the glove-fingers of humpback whale like those of the fin whales. In all specimens examined from the blue whale, the fin whale and the humpback whale, the occurrences of papillary types are almost similar in the two sexes.

RELATIONSHIP BETWEEN CORE LENGTH AND SKULL WIDTH

It has been suggested by Purves (1955) "the characteristically great lateral growth of the posterior region of the skull in the Mysticeti is apparently almost wholly associated with the lateral extension of the zygomatic process of the squamosal, the paroccipital process and the mastoid process of the tympano-periotic and during the lateral extension of these bones which are concerned in the formation of the bony external meatus, the wax plug would tend to be drawn away from its contact with the glove-finger." Later Laws & Purves (1956) have explained "the dark band found in the fin whale plug marks an abrupt interruption which implies almost complete cessation in the growth of the entire skull and presumably in that of the skeleton and such an interruption, therefore, would have occurred during the migratory period when the excessive physiological demands of active swimming were coincident with complete absence of food." Apart from whether the dark band of core is formed or not coincidentally with the migratory period, between these two suggestions mentioned above it is a common maintenance that the formation of ear plug is dependent on the various stages of the lateral growth of skull. If so, these important suggestions must be confirmed through the relation between the core length and the skull width.

In the northern Pacific expedition of 1957, I measured the several parts of skull of the fin whale and simultaneously collected the ear plug from the measured whale. Two purposes have lain in these skull measurements, in which one purpose is to contribute through the craniometry to the study on subpopulations of fin whales and the other is to confirm the relationship between the formation of ear plug and the lateral growth of skull. For the latter purpose two dimensions of skull took place before sawing the bone. One dimension is the greatest width of skull and the other is the distance between both postglenoid processes of squamosal. The greatest width of skull means the distance between both zygomatic process of squamosal which is situated in the adult fin

whale at a little anterior part than the tympanic bulla and the external auditory meatus. The external auditory meatus proximally lies in a deep groove between squamosal and paroccipital process and therefore the distance between both postglenoid processes of squamosal will become better expression of the width of skull near the external auditory meatus.

With regard to the relationship between the lamination number and the core length of fin whale plug, Nishiwaki, Ichihara & Ohsumi (1958) have concluded that the total length of the core per one lamination varies very greatly from one specimen to another. This conclusion was also affirmed later by Purves & Mountford (1959) using many ear plugs from the Antarctic fin whales. If this great individual variation of the

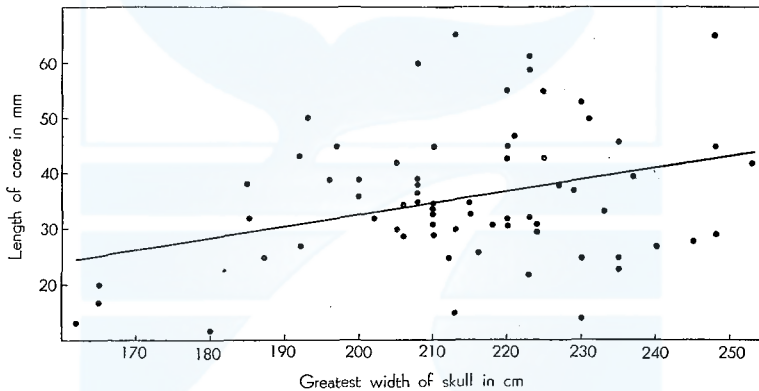


Fig. 5. Relation of length of plug core to greatest width of the skull in female fin whale. Individual value is indicated.

total length of core is depend on the ratio of lateral growth of individual skull, the close relation should be found between the total length of core and the width of skull. To confirm this relationship two parts from 69 skulls of female fin whales are plotted corresponding to the total length of core in Figs. 5 and 6, in which the total length of core per the skull width varies greatly from one specimen to another, however, the hypothesis of a linear relationship between the total length of core and the skull width provides a fit to the data in the range of skull width indicated. The linear regression of the total length of core to the greatest width of skull is

$$Y=0.21-9.67X$$

and to another width of skull it is

$$Y=0.29-15.10X$$

where Y and X are the total length of core in mm and each skull width

in cm respectively. From this result it can not be emphasized that there is a close association between the increasing total length of core and that of the skull width. The similar result is obtained when the correlation coefficients are considered for 51 measured male fin whales reserved from Figs. 5 and 6. In male fin whales, the greatest width of skull ranges from 170 to 230 cm and another width of skull ranges from 130 to 190 cm respectively.

The correlation coefficient between the total length of core and the greatest skull width is as little as 0.43 and that between the total length of core and another skull width is as little as 0.40 in male fin whales. Then the coefficients are as little as 0.33 and 0.36 for each skull width of the female fin whale. Using *t*-test, these correlation co-

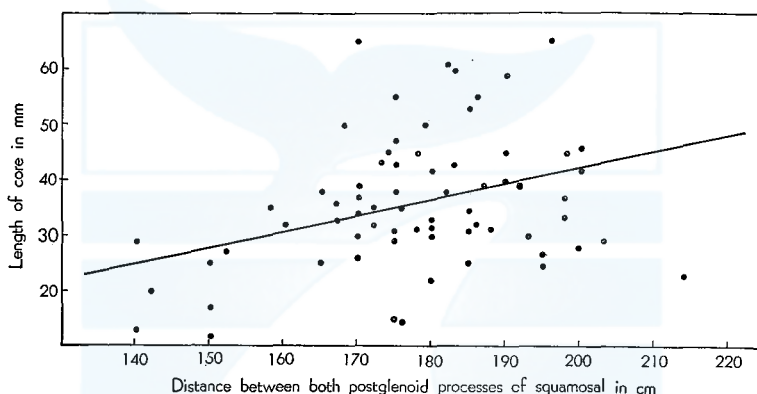


Fig. 6. Relation of length of plug core to distance between both postglenoid process of squamosal of the skull in female fin whale. Individual value is indicated.

efficients are significant at the level between 1% and 0.1% respectively, however, it will be beside the mark to emphasize the close correlation between the increasing total length of core and the growing skull width. Because these significancies derived from the mathematical treatment do not become justifiable reasons to conclude that there is a close causality between two variates although the interrelationship should not be neglected.

Recently Purves & Mountford (1959) have inferred that the total length of ear plug has no close relationship to the skull length. It is assumed that their inference does not come from the direct research for the relation between the plug length and the skull width but it is based on the combination of the next two findings: firstly, there is a close linear relationship between the body length of whale body and the skull width, secondly, between the body length and the core length is

there a relationship which is perceived between the lines in their paper. That is, my finding may be taken as a definite illustration of their inference. The increasing length of core should be positively based on the internal progressing metabolism of whale body as stated by Purves & Mountford (1959), and this finding will be explained later in this paper.

It is of incidental interest to note that the increasing rates of the total length of core on two parts of skull width for female and male fin whales are not significantly different. Furthermore the distance between both postglenoid processes of squamosal is not deemed to effect more positively on the increasing length of core than the greatest width of skull.

GENERAL NOTE ON PLUG CORE

Since the laminae in the conical ear plug are deposited from the epithelium of glove-finger in the progressive stage of the life of baleen whale, the total length of core seems to be stretched regularly from the young to the old age. Purves (1955) has indicated the thickness of the laminations decreases exponentially over the greater part of the series, although there is a certain degree of irregularity. With regard to this irregularity Laws & Purves (1956) have suggested in their preliminary report the alternation in the thickness of the fin whale lamina may be thought to cast some doubt on the validity of assessing a regular six monthly period for the formation of each lamination and the inter lamina areas of the ear plug would occur at six monthly intervals in the blue whale and approximately four and eight monthly periods in the fin whale, considering the migration periods exist regularly in the blue whale and irregularly in the fin whale. However, it must be emphasized that the alternation in the thickness of lamina often occurs irregularly in the blue whale ear plugs I examined.

It is of interest to note the finding in their paper the first lamination, being always a small, conical, unstratified body rich in calcium, is deemed to be that part of the plug which is present in the ear before birth. The prenatal lamina is always present in all ear plugs I examined, its structure and thickness varying from one specimen to another. In the young ear plug its presence is confirmed more easily than in the old one. This phenomenon is explained from the fact that the epithelium of glove-finger is fully keratinized in the distal end of the old ear plug and the conical form of the first lamination is compressed between the growing core and the interfering outer covering derived from the external auditory meatus. The presence of core before birth is suggested by the evidence that a full grown foetus of the humpback whale

caught off Okinawa Island in the winter season of 1959 has the thin ear plug in the outer surface of the glove-finger. This male foetus is 12 feet and 10 inches long, it being considered to be near the length of parturition (Nishiwaki, 1959). In this connection it is interesting to draw attention to the occurrence of the ceruminous glands in the human foetus. Iwata (1933) have reported the ceruminous glands of human foetus in 6 months of pregnancy begin to secrete as the apocrine glands,

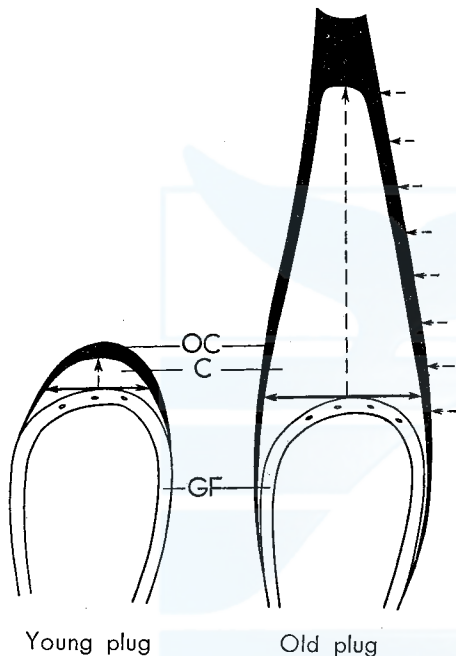


Fig. 7. Diagram showing the increasing length and breadth of ear plug core from the young to the old age with the directions of pressures. OC: outer covering of the ear plug, C: core of ear plug, GF: glove-finger, Solid arrows show the breadth of core and pressure in its part. Broken arrows show the longitudinal and lateral pressures.

finger and it is shown in two diagrams of Fig. 7. Although the all ear plugs cover the distal part of the curved glove-finger, the young plug characteristically caps the curved extremity of the glove-finger, while the old plug usually covers the almost all curvature of glove-finger. The first lamina of the humpback whale foetus mentioned above caps only the curved extremity of its glove-finger. The fringe of old ear plug existing along the lateral side of glove-finger is really composed of both

however, there are controversies on the embryological studies of the ceruminous glands according to Nagashima (1934), Hirota (1939), Nagasawa (1941) and Ito (1942, '49). Purves (1955) has proposed that the many ceruminous glands exist in the curved extremity of glove-finger, but, for reasons stated later in the histological study of ear plug, I disagree with this interpretation. Apart from the presence of ceruminous glands in the glove-finger of the baleen whale, the embryological study of ear plug remains a further important one.

There has been no description with regard to the breadth of core of the ear plug in relation to the constant size of glove-finger throughout the life span of whale. In the course of the ear plug study, I noticed the young plug was different in its shape from the old plug. The difference is more evident in the specimen of which ear plug sticks on the glove

the core part and the outer covering part.

The breadths of large numbers of ear plugs from the North Pacific fin whale are measured in such a right-angled direction to the length of core as indicated in Fig. 7. These breadths of cores are plotted against the lamination numbers in Fig. 8 in which each plot shows the mean breadth per 2 laminations. For this purpose, 437 specimens from the fin whale are used and the numbers of specimens per 10 lamination numbers are described in Fig. 8. The breadth of core varies from one specimen to another, growing from the young to the old, however, over about 40 laminations it does not grow more. It is of interest that the mean breadth of core is remarkably similar in the two sexes, consequently the specimens from both sexes are applied in Fig. 8. Nishiwaki,

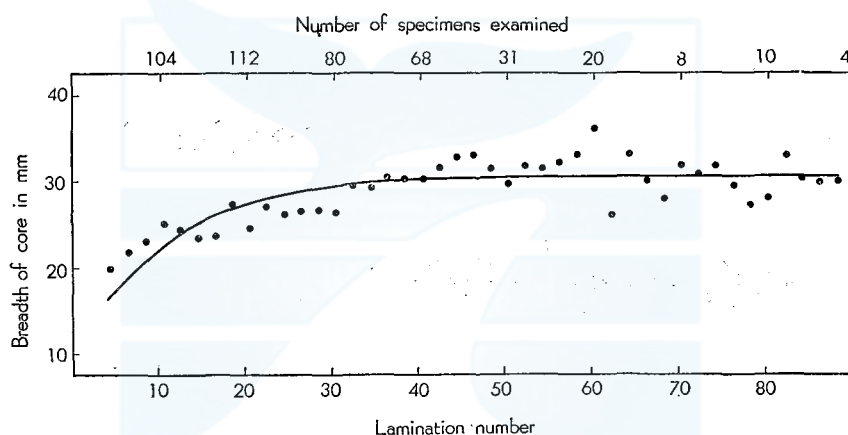


Fig. 8. Change in the breadth of plug core at increasing lamination numbers in the northern Pacific fin whale.

Ichihara & Ohsumi (1958) and Purves & Mountford (1959) have concluded the increasing rate of the core length is not different between the male and female fin whale. The size of core finally is resemble in the two sexes of the fin whale and this finding presumable is extended to all baleen whales.

The presence of longitudinal light bands running in the core are the most evident macroscopically in its centre portion and the distance between one longitudinal light band and the neighbouring is the most wide there in all areas of core. It should be noticed further more that the breadth between two bands spread a little and the numbers of longitudinal light bands are increasing little by little from the distal to the proximal end of plug core. The latter finding suggests in the old individual the ear plug are not only formed from the curved extremity but also from the lateral side of glove-finger. It is suggested that the

outer covering derived from the lining of the meatus presses little by little the lateral side of the growing plug core from the young to the old.

After all, the conical form of the plug core is deemed to be dependent upon the balance of the next three pressures, which are indicated in Fig. 7. The two pressures of them are due to the keratinized epithelium of the glove-finger, in which the most effective one on the conical form of core operates in the outward direction from the glove-finger, the other being in the laterally outward direction from it. The last pressure is due to the compacted keratinized epithelium of the meatus and operates in the laterally inward direction from it. The various conical form of the ear plug results from the three pressures mentioned above, which operate in different intensities from individual to individual. Among the baleen whale I examined, the longitudinal pressure is more intensive in the plugs of the blue, fin and humpback whales than in that of the sei whale. In the sei whale the distance between two laminations regarded as the age character is usually narrower. Plate I, Fig. 2 indicates the bisected ear plugs from the different 5 baleen whales.

It has been concluded by Nishiwaki, Ichihara & Ohsumi (1958) that the colour of the plug core in the young fin whale is discriminated from that in the old fin whale, and that the colour of core from the sexually immature whale is rather whitish yellow while that from the old whale changes from a dull ochre to blackish brown. This finding in the fin whale is extended to the plug core of the other baleen whale and it is supplemented by the next explanation. The change of colour appears even in one specimen. The dark band of core is rather lighter in the proximal end than in the distal end, and this suggests that the keratinizing progresses further more in the distal end of core than in the proximal end, following the period elapsed since the epithelium is detached from the glove-finger. It must be noted that in the parts of core surrounded by the outer covering the darker colour appears macroscopically than in the center of core. Lastly in the supplemental note on the core colour, it is necessary to describe the abnormal ear plug appears in very few frequency. In this abnormality there are various cases to be studied further as seen in Plate II, Fig. 1. In the extremely abnormal ear plug, which looks like a black coal, the lamination number is not counted. In the other case, the alternate occurrences of the dark and light band are interrupted abruptly in the series by the blackish brown substances and successively appear the normal laminae. In some cases the alternate laminae are not seen until the core is sectioned longitudinally.

HISTOLOGY

Morphological characters on the glove-finger and on the ear plug have been described and suggestive to some extent on the mechanism of ear plug formation, which should be explained in the histological study. In this connection the glove-finger is examined firstly since it plays a important part in the formation of ear plug.

Glove-finger. Specimens have been preserved in 10% formalin solution shortly after they are collected on the factory ships and from the land station. Most of all specimens examined are composed of the glove-fingers from the fin whale and blue whale and small numbers of them are occupied by the glove-fingers of the other baleen whales. The specimens for the histological preparation are obtained in the rectangular block of about $5 \times 5 \times 10$ mm from the curved extremity of the glove-finger, partially from its lateral side. These blocks are embedded in the celloidin solutions and sectioned in the thickness of 10μ after the interval from two to three months, and followed by haematoxylin eosin, Heidenhain's iron haematoxylin and AZAN staining. In relation to the formation of ear plug, the epithelial and connective tissues of the glove-finger are studies for the present problem.

The epidermis covering the most outward part of the glove-finger is the stratified flattened epithelium, which the germinal and horny layer constitute. The germinal layer is composed of the many cells in which the basal cylindrical cell layer shows especially the aspect of progressive cell division. Between the germinal layer and the horny layer there are not the confirmatory aspects of the granular layer or clear layer as seen usually in the thick epidermis. In the corium below the epidermis, there are characteristically many papillary layers, of which shapes effect on the shapes of the laminae seen in the ear plug. The sectioned specimen, Plate II, Fig. 2, suggests the collagen fibers occupy the most part of the connective tissue and the elastic fibers exist between them. The papillary layer project many papillae into the epidermis and the projection is remarkably in the papillae of the blue whale. Plate I, Fig. 1, shows the papillae of the blue whale and the different types of those of the fin whale. The papillae are about 5 mm so long in the projected extremity in the blue whale, that they can be observed macroscopically. These papillae are not arranged regularly and it is observed microscopically that there are many small papillae both two large papillae. In the corium of the blue whale the small papillae characteristically distribute irregularly and they show the something like a hive in the section as seen in Plate III, Fig. 2. This suggests the intervening papillae are laterally pressed so intensively between two

developed long papillae that they form the curious constructure as if the basal layer of the germinal layer subsides deeply into the corium.

In a papilla and below the papillary layer, there are many blood vessels composed of blood capillaries, arterioles and venules. Although the contents of the capillaries are often dissolved out in the section, they are sometimes occupied by the red blood corpuscles as shown in Plate III, Figs. 1 & 2 and Plate IV, Fig. 1 in which the distal end of papilla of the blue whale and the papillary layer of the fin whale are indicated. Any excretory ducts opening on the surface of epidermis are observed nowhere in the specimens examined in which the cavities exist a little apart from the basal layer of germinal layer. I disagree with the presence of the ceruminous glands in the glove-finger, for the reason which Purves (1955) has interpreted. In Plate XVII, Fig. 3 of his paper, the abundant blood-capillaries are indicated as the ceruminous glands, however, that section shows the presence of erythrocytes in the cavities which the endothelial cells surround, even if it is obtain from the old specimen.

With relation to the formation of laminae seen in the core of ear plug, the shapes of papillae should be noticed. The structures like bands are divided into three parts macroscopically. One of them is the light yellowish band arranged as fairly regular structures of concentric circles from the proximal to the distal end of core, and the band of the similar light yellowish colour runs longitudinally in the core. Lastly it is be noted that the dark coloured band exists between two light concentric circles. These light concentric and longitudinal bands are stained well by SUDAN III and looks the yellowish red or red colours in the sections. In the microscopically examination, the macroscopical concentric light bands are really curved along the shapes of the projected papillae. With regard to this finding Plate V, Figs. 1 & 2 are referred in which the proximal part of core of the blue whale and fin whale plug are indicated. Especially in the proximal end of the blue whale specimen, a part of germinal layer remains and enables us to know relation between the shapes of papillae and those of the light curved bands. Since the papillae project irregularly into the ear plug and a large papilla sometimes is more protrudent than another small papilla, the lamination numbers are different from one column of tissue to another within the constant range from the outside curvature of glove-finger. Here, the colume of tissue is defined as the tissue between two longitudinal light bands in the plug core.

In this connection, the lamination counting must be noticed particularly in the ear plug with the remarkably projected papillae in its glove-finger. It is furthermore desirable that the laminations are counted

along the one longitudinal light band which is present in the middle part of core. On the contrary the light curved bands become to distribute concentrically in the ear plug without so much projected papillae in its glove-finger. It has been stated previously about a half of the glove-finger of the fin whale has no markedly protrudent papillae and so its surface is fairly smooth.

The germinal layer of the epidermis of glove-finger remains usually in the most proximal end of the ear plug collected. Since the germinal layer covers the papillary layer of corium, the most proximal end of the ear plug collected sinks corresponding in position which the papillae project. It is of interest to note that Malpighi's Ret is apparently present there.

In the course of the study on the mechanism of ear plug formation, the histological examinations are practised in the next two parts of core; the first part of them concerns the curved light yellow band and the dark band between two light yellow bands. These bands are important for the age determination of the baleen whale. The second part involves the longitudinal light yellow band.

Concentrically curved light and dark bands. Specimens preserved in 10% formalin solution shortly after they are collected from the whale body are partially embedded in the celloidin solutions, however, most of them are prepared in the effectual frozen section since the paraffin embedding is not available for such a deposited material as the ear plug. Numerous specimens sectioned in thickness from 10 to 15 μ are stained by haematoxylin eosin and SUDAN III.

Before the sectioned materials are produced, I measured the distance between two curved light yellowish bands under a dissecting microscope. Nextly, the ear plugs of the frozen section were observed under the dissecting microscope to measure the distance between two light bands. After these preliminary processes, the position of the light band were presumed from the distance between two bands in the section stained by SUDAN III. Although the various fatty substances are observed to distribute in the whole area of the stained section, the curved light yellow band is confirmed as the parts stained darkly by SUDAN III. These shapes of darkly stained bands, of course, are different from one species to another, corresponding to the shapes of laminae. The stained sections are shown in Plate V, Figs. 1 & 2. The curved dark band between the two light yellowish bands is not stained well by SUDAN III but by eosin. In the course of the examination on the numerous sections from the proximal end of well fixed ear plugs, it has been fortunate the light band and dark band are found under the formation, and it facilitates to explain the process of formation.

In the stratified flattened epithelium, the cells of germinal layer are generally elevated outerwards according to the increasing numbers of cells in the basal layer. The epidermis of glove-finger belong to the same category, however, the cells of germinal layer characteristically remain the degenerated forms in the ear plug throughout the life span of whale. Plate VI, Figs. 1 & 2 indicate the various transforming cells of the germinal layer according to their distances from the basal layer. These two photomicrographs are obtained from the fin whale plug sticking to the outer surface of glove-finger. Plate VI, Fig. 2 shows the various kinds of cell forms near the basal layer and Plate VI, Fig. 1 indicates the transformation of cell in the more distal part. It is indicated in this plate that the size of cell becomes not only larger and larger but also its shape is deformed by and by soon after it is apart from the basal layer. Lastly, it is flattened and becomes a fusiform cell of which cytoplasm is stained well by eosin. Since the primitive stage of keratinized epithelium appears in these two figures, it must be illustrated subsequently how to already keratinized epithelium is deposited in the core of ear plug. In Plate VII, Fig. 1 and enlarged Plate VII, Fig. 2, there are many layers of accumulated keratinized epithelium. The fusiform cells are destroyed in response to the passing of time, therefore, they disappear in the distal end of the section from the old whale, forming the developed keratinized uniform tissue stained by eosin. The germinal layer of epidermis of glove-finger remains in the lower parts of these two figures and many nuclei are stained by haematoxylin.

It may be, therefore, safely said that the appearance of fusiform cell corresponds to the beginning of conification, that is, to the first stage of the formation of curved dark band in the ear plug. In the course of the keratinized degeneration of the germinal cell of glove-finger, the nuclei are deformed in the various stages. The deformation of nuclei appear even in the cells near the basal layer of epidermis and the forms of nuclei vary greatly from one cell to another, for example, from the ellipse to the circle, indicating sometimes the curious projection and notch, as shown in Plate IV, Fig. 2 and Plate VI. The complicated forms of nuclei may suggest the degenerated epithelial cells function abnormally. These nuclei disappear soon after the fusiform cells occur.

Another case in which the light yellowish band is occurring is different greatly from the case of forming dark band mentioned above. From the frozen section from other specimens of fin whale, I can obtain the Plate VIII, Figs. 1 & 2, one of which is enlarged from the other figure to facilitate the explanation. The germinal layer in epidermis of glove-finger remains in the lower part of Plate VIII, Fig. 1, besides the band stained darkly by SUDAN III appears in the middle and the

keratinized fusiform cells are present in the upper part. This figure indicates the light yellowish band has been just formed. In this connection see the enlarged photomicrograph, Plate VIII, Fig. 2 in which the fatty degeneration of the cells in the germinal layer is illustrated.

In the first stage the fatty granules begin to appear sporadically in the cystplasms of degenerated cells and they occupy the most part of the cystplasm in the second stage when the nuclei remain yet in the compressed deformation. In the last stage, the fatty granules flow out destroying the cell of developed degeneration and they form the band filled with the various fatty substances. The nuclei remain in the last stage as compressed forms among the fatty substances and stained by haematoxylin, however, they disappear after all. In this connection it is interesting to draw attention the sebaceous gland in which the degenerated cells filled with the fatty substances send out simultaneously the involving fatty substance when they are destroyed. If the presence of the gland must be stated persistently in the glove-finger, such glands do not belong to the category of the eccrine and apocrine gland but to that of the holocrine gland. As far as the fatty degeneration concerns, the epithelial cells function rather like sebaceous glands. When the dark band is formed, the keratinized epithelial cells show the shapes like the fairly obese fusiforms, however, in the case of the fatty degeneration they form usually the shapes of a little obese rounds. In the latter case the deformed nuclei remain even when the cells filled with fatty substances are destroyed at last. These differences must be emphasized particularly in respect that the epithelial cells of glove-finger result so alternately in the fatty and the keratinized degeneration that the light yellowish band and the dark band appear macroscopically in the regular concentric circles in the plug core.

In Plate VII, the fatty substances are observed to encircle the keratinized fusiform cells. This is explained from the next two findings. Firstly in the course of keratinized degeneration, most of all epithelial cells grow into fusiforms and they are stained well by eosin, however, a few of them remains rather roundly degenerated cells and the fatty substances appear in their cystplasms. Secondly, into some parts of the layer of keratinized epithelium, especially into the neighbouring parts to the longitudinal light band, the fatty substances flow from the longitudinal light band through spaces of stratified fusiform cells. The structure of the encircling fatty substances is compared to the sewing the pieces of keratinized fusiforms cells together with the fatty substances and it may not keep the ear plug a very fragile material. The keratinized fusiform cells appear sometimes in few frequencies in the

course of the fatty degenerations. The intervention of these substances of different character brings forth the difficulty in case of the lamination counting. Abnormal ear plug showing coarse and fine laminations which is indicated in Plate 6 by Purves & Mountford (1959) seems to be an example of such a case. With regard to the second findings mentioned above, the longitudinal light bands are described in the next part.

Longitudinal light band. The longitudinal bands are observed as the light yellowish structure homologous to the concentric light band in all ear plugs from the various baleen whales and their positions are illustrated in Plates V & IX. It is noticed that the projections of papillae

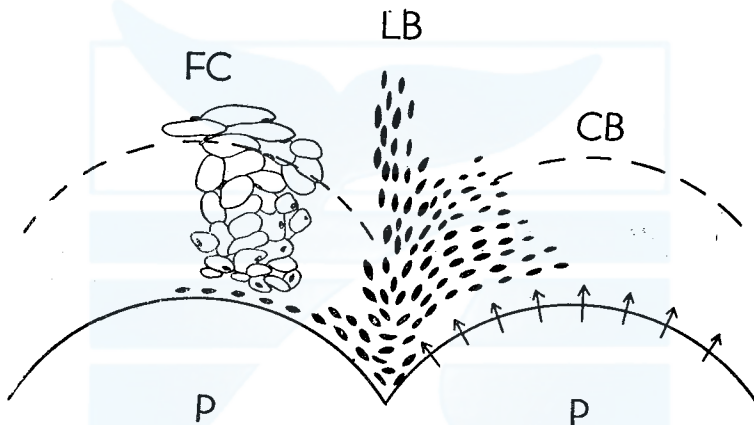


Fig. 9. Diagram showing the relationship between the arrangements of nuclei and the direction of pressure from the basal layer of epidermis of glove-finger. Arrows indicate the direction of pressure. LB: longitudinal band, CB: concentric band, FC: fusiform cell, P: papilla.

of glove-finger exist between two longitudinal light bands and the protrudent shapes of papillae bear closely on the formations of these bands. The longitudinal yellow bands are stained by SUDAN III and shows homologous structure to the curved light bands composed of various fatty substances. The proximal end of ear plug is sectioned and stained by SUDAN III, which is illustrated in Plate IX, Fig. 1 in this connection. It should be noted firstly the shapes of degenerated cell is different from those of the other bands.

The cells are so elongated in the longitudinal direction that the extremely proximal end of the longitudinal band looks like fine roots of tree. In the sectioned materials stained by SUDAN III, the orange colour of the structure like fine roots is more apparent against the violet colour of the nuclei of the germinal cell stained by haemotoxylin. The

fatty degeneration of epithelial cell in the longitudinal band begin in the earlier stage than the curved light band. In the longitudinal band, the compressed nuclei, their shapes corresponding to the elongated epithelial cell, remain in the fatty substances which flow from the destroyed cells. It is endorsed by Plate IX, Fig. 2 of the section from the young plug that the nuclei remain for the long period in the plug core. In this section stained by haemotoxylin and eosin, the papillae of glove-finger are not so projected and it is shown in the lower part of that figure, however, the nuclei are not absorbed and remain in the longitudinal band. Here it is pointed out that there is the similarity of fatty degeneration between the curved and longitudinal light band,

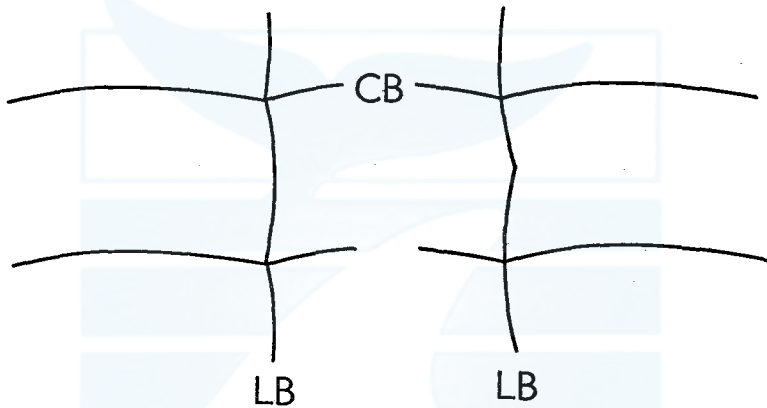


Fig. 10. Diagrams showing the relation between the direction of the curvature in longitudinal light band and that in concentric light band. LB: longitudinal light band, CB: concentric light band.

that is, the sizes of epithelial cells are not so enlarged in the fatty degeneration as in the keratinized degeneration, and the deformed nuclei appear in the cells filled with the fatty substances and remain yet longer after the cell destroyed.

It is assumable that there is a close interrelationship among the deformed shapes of nuclei, the form of their arrangements and the directions of pressures dependent on the shapes of papillae. The photomicrograph is given in Plate IV, Fig. 2 to explain this relationship. This photomicrograph is taken from the section with the projected papillae and so enlarged in the germinal layer between two large papillae that the extremely proximal end of longitudinal band are surveyed. The nuclei begin to be deformed in any part of the germinal layer soon after the cells are apart from the basal layer. Characteristically between two large papillae, the nuclei are much flattened than the other part of germinal layer. This suggests the cells are flattened similarly

there. In the other part of the germinal layer the nuclei are arranged along the curvatures of projected papillae. From Fig. 9 showing the relation between the arrangements of nuclei and the directions of pressure, the reason which the cells and nuclei are compressed laterally in the longitudinal band is illustrated. The diagram indicates furthermore the projection of papilla is effective on the formation of longitudinal band and on the shape of lamina formed upon it.

The longitudinal bands seem to run spirally from the proximal end to the distal end of the plug core. It may be explained, however, from Fig. 9 that there is no close relation between the longitudinal band and the curved light yellowish band. Numerous frozen sections do not suggest me that the curved light yellowish band is in general derived from the longitudinal band as Purves (1955) has pointed out. He has stated the structure like the longitudinal light band corresponds to the ceruminous duct and the lipoids are secreted from the ceruminous gland in the corium of glove-finger in the resting period and the active formation of the squamous epithelium is seen in other period. If the curved light band dues to the lipid secretion from the ceruminous gland of glove-finger, the left diagram in Fig. 10 always should be applied to the formation process of ear plug, however, there are various relationships between the direction of the longitudinal band and that of the curved light band and the right diagram in Fig. 10 is often applied. Furthermore I can not observe always the second lamina is formed reversely in its curvature to the first lamina, on the contrary, the second lamina curves similarly to the first lamina in the most of examined specimens.

Based on the reasons referred above, I disagree with Purves' interpretation on the formation mechanism of ear plug. Yamada (1953) has suggested the plug of ear wax seems to be produced by the meatal epithelial and not the products of glands, however, he has not referred to the core part of ear wax of Mysticeti. It was endorsed before in this paper that the alternation of the dark and light band considered as the valid index of the age determination appears in the process of degeneration of the epithelial cells in glove-finger. Assuming the rhythmic growth in the passage of time, I would like to conclude that such a degeneration is practiced in response to many factors related to the metabolism of whale body. Particularly the effect of hormone and enzyme on the metabolism are regarded initially, and with the intractable problem of the inherent physiological rhythm set aside, the external environment may effect on such a periodicity. On this subject further research remains a fascinating one.

The incidental statements in the histological study are as follows.

The granules stained darkly by haematoxylin appear often in the longitudinal section of ear plug, and distribute irregularly in the degenerated tissue. In the young specimens they appear more often than in the old specimens. Their abundance in the distal end of core characteristically may indicate the metabolism of the whale body in the very young stage. It is, furthermore, of interest to note that many capillary crystals, not stained by SUDAN III, are observed in the formalin preserved specimens. They distribute frequently in the longitudinal light and concentric light band but sometimes in the layer of keratinized epithelium, concentric dark band. These crystals are indicated in Plate VIII, Fig. 1.

SUMMARY

Glove-fingers and ear plugs from baleen whales were studied morphologically and histologically. The examined numerous specimens consist of 6 species, the blue, fin, humpback, sei, Bryde's and minke whale, being collected from the Antarctic Ocean, the northern part of the North Pacific and from the adjacent waters to Japan from 1956 to 1959. My findings are summarized as follows.

1. The size of glove-finger is constant throughout the life of whale.
2. The size of glove-finger varies from one species to another and it gives a clue on the study of subpopulations located in the various areas. In the northern hemisphere, the glove-finger of fin whale from the East China Sea is significantly smaller in size than that from the northern part of the North Pacific.
3. The glove-finger are divided into three types from the shape of papillae, which is effective on the shape of laminae seen in the core of ear plug. The papillae of glove-finger from the blue whale are protrudent remarkably from the outer surface of glove-finger. Moderately projected and macroscopically not projected papillae occur in the glove-fingers of fin and humpback whale. Papillae seem to be protrudent little by little at the increasing age of whale.
4. The core of ear plug seems to be formed in the prenatal stage of the baleen whales.
5. In the longitudinally bisected specimen, the breadth of plug core grows in its the proximal end at the increasing age of whale. This finding suggests the plug core is formed from the lateral side of glove-finger in the old whale. The increases of breadth and length of core gives the ear plug the conical form. The similarity in the size of core is recognized in the two sexes.
6. There is no ceruminous gland in the corium of glove-finger. The

numerous small cavities observed in the corium are the blood capillaries. 7. The concentrically curved light band and longitudinal light band in the plug core are composed of the various fatty substances. The keratinized epithelium of glove-finger constitutes the most part of the dark band between two curved light bands. These bands are derived from the degeneration of epithelial cells of glove-finger. In particular the periodical occurrence of the fatty and the keratinized degeneration gives the ear plug the validity of age determination.

8. It is not able to emphasize there is a close relationship between the length of plug core and the lateral growth of skull. Based on the histological examination the increasing length of core is rather dependent on the internal progressing metabolism of the whale body. Since the alternation of light and dark band appear rhythmically in the plug core, the effects of hormone and enzyme on the degenerations of epithelial cells of glove-finger are regarded initially. Besides, the effect of the external environmental factors are presumed indirectly. Further studies are needed on this subject.

REFERENCES

- BURNE, R. H. (1952). *Handbook of R. H. Burne's Cetacean dissections*. Brit. Mus. (Nat. Hist.), 70 p.
- CHITTLEBOROUGH, R. G. & GODFREY, K. (1957). Review of whale marking and some trials of a modified whale mark. *Norsk Hvalfangst-Tid.*, nr. 5: 238-48.
- FRACER, F. C. & PURVES, P. E. (1954). Hearing in Cetaceans. *Bull. Brit. Mus. (Nat. Hist.), Zool.*, 11: 101-14.
- HINOURA, J. (1938). [Auditory organ of Balaenoptera acutorostrata]. *Hokuetsu Igakkai Zasshi*, 53: 835-75. (In Japanese).
- (1941). [Auditory organ of cetacea]. *Nihon Gakujitsu Kyokai Hokoku*, 15(4): 424-7. (In Japanese).
- (1943). [Anatomical study of the hearing organ of cetacea. 1. Macroscopic remarks]. *Hokuetsu Igakkai Zasshi*, 58: 21-59. (In Japanese).
- HIROTA, S. (1939). [Statistical and experimental study on bromidrosis]. *Seikai Zasshi*, 58: 530-67. (In Japanese).
- ICHIHARA, T. (1957). An application of linear discriminant function to external measurements of fin whale. *Sci. Rep. Whales Res. Inst.*, no. 12: 127-89.
- ITO, M. (1942). [Presence of apocrine glands in whole body of human embryo and their racial differences]. *Kaibogaku Zasshi*, 20: 228. (In Japanese).
- ITO, T. (1949). [Histology and cytology of sweat glands]. *Progress in Medicine*, 6: 106-221. (In Japanese).
- IWATA, T. (1933). [Embryological study on human ceruminous glands]. *Kaibogaku Zasshi*, 5: 1063. (In Japanese).
- KAWAKAMI, T. & ICHIHARA, T. (1958). Japanese whale marking in the North Pacific in 1956 and 1957. *Norsk Hvalfangst-Tid.*, nr. 6: 285-91.
- KELLOGG, R. (1928). The history of whales, their adaptation to life in the water. *Quart. Rev. Biol.*, 111: 174-208.
- LAWS, R. M. & PURVES, P. E. (1956). The ear plug of the Mysticeti as an indication of

- age with special reference to the North Atlantic fin whale (*Balaenoptera physalus* Linn.). *Norsk Hvalfangst-Tid.*, nr. 8: 413-35.
- MIZUE, K. (1956). [Report on biological investigations of the whales caught in the East China Sea in 1955]. Tokyo, Whales Research Institute, 34 p. (In Japanese).
- MIZUE, K. & FUJINO, K. (1957). [Report on biological investigations of the whales caught in the East China Sea in 1956]. Tokyo, Japan Whaling Association, 21 p. (In Japanese).
- NAGASAWA, K. (1941). [Ceruminous glands of Japanese]. *Kyoto Igakukai Zasshi*, 38: 110-23.
- NAGASHIMA, T. (1934). [Ceruminous glands of Japanese in relation to cerumen and bromidrosis]. *Hihuka Hinyokika Zasshi*, 36(6): 690. (In Japanese).
- NISHIWAKI, M. (1957). Age characteristics of ear plug of whales. *Sci. Rep. Whales Res. Inst.*, no. 12: 23-32.
- , (1959). Humpback whale in Ryukyuan waters. *Sci. Rep. Whales Res. Inst.*, no. 14: 49-87.
- , ICHIHARA, T. & OHSUMI, S. (1958). Age studies of fin whales based on ear plug. *Sci. Rep. Whales Res. Inst.*, no. 13: 155-69.
- OHSUMI, S., NISHIWAKI, M. & HIBIYA, T. (1958). Growth of fin whale in the northern Pacific. *Sci. Rep. Whales Res. Inst.*, no. 13: 97-133.
- OMURA, H., FUJINO, K., ICHIHARA, T. & KIMURA, S. (1958). [Study on the fin whale population in the North Pacific]. *Whales Res. Inst.* 30 p. (In Japanese).
- , ——, ——, NASU, K. & OSUMI, S. (1959). [Complemental study on the fin whale population in the North Pacific]. *Whales Res. Inst.* 24 p. (In Japanese).
- PURVES, P. E. (1955). The wax plug in the external auditory meatus of the Mysticeti. *Discovery Rep.*, 27: 293-302.
- PURVES, P. E. & MOUNTFORD, M. D. (1959). Ear plug laminations in relation to the age composition of a population of fin whale (*Balaenoptera physalus*). *Bull. Brit. Mus. (Nat. Hist.) Zool.*, 5(6): 125-61.
- ROMEIS, B. (1948). *Mikroskopische technik*. München, 695p.
- SCHIEFFERDECKER, P. (1922). *Hautdrüsen des Menschen und der Säugetiere*, ihre biologische und rassenanatomische Bedeutung, sowie die Muscularis sexualis, Stuttgart. 154p.
- SEKI, M. (1954). [Histology]. Tokyo, Kyorinshoin, 351 p. (In Japanese).
- SYMONS, H. W. (1956). Some observations on the ear of blue and fin whales. *Norsk Hvalfangst-Tid.*, nr. 1: 37-45.
- SYMONS, H. W. & WESTON, R. D. (1958). Studies on the humpback whale (*Megaptera nodosa*) in the Bellingshausen Sea. *Norsk Hvalfangst-Tid.*, nr. 2: 53-81.
- YAMADA, M. (1948). Auditory organ of the whalebone whale (Preliminary Report). *Sci. Rep. Whales Res. Inst.*, no. 2: 21-30.
- (1953). Contribution to the anatomy of the organ of hearing of whales. *Sci. Rep. Whales Res. Inst.*, no. 8: 1-79.

EXPLANATION OF PLATES

PLATE I

Fig. 1. Glove-fingers of the various baleen whales with indicating the three types of glove-finger from the fin whale ($\times 1/2$).

Upper: Fin whale, left to right; papillae are not projected, papillae are projected a little, papillae are projected markedly, papillae are projected at the one side on the curved extremity of glove-finger.

Lower: Left to right; minke whale, Bryde's whale, sei whale and blue whale.

Fig. 2. Bisected ear plugs of the various baleen whales with the scale in cm.

Left to right: minke whale, 9 laminations; sei whale, 40 laminations; humpback whale,

24 laminations; fin whale, 29 laminations; blue whale, 41 laminations.

PLATE II

- Fig. 1. Bisected abnormal ear plugs of the fin whale with the scale in cm.
Black substances interrupt the regular occurrence of laminae.
- Fig. 2. Longitudinal sections of the curved extremity of glove-finger, from the baleen whales, staining by haematoxylin eosin.
Left: Glove-finger of the fin whale ($\times 15$).
Right: Glove-finger of the blue whale ($\times 7$).
P: papilla, EP: ear plug, CT: connective tissue.

PLATE III

- Fig. 1. Longitudinal section of the distal end of one papilla ($\times 100$), from the glove-finger of blue whale, staining by haematoxylin eosin. This photomicrograph indicates the ear plug is formed from the distal end of papilla and red corpuscles exist in the blood capillaries of the corium.
GL: germinal layer of epidermis, BC: blood capillary.
- Fig. 2. Longitudinal section of the many small papillae which are present between the two large papillae ($\times 100$), from the glove-finger of blue whale, staining by haematoxylin eosin. This photomicrograph shows that the sectioned small papillae form the structure like a hive and that there are the blood capillaries in corium.
LP: the proximal end of large papilla, SP: small papilla, BC: blood corpuscles.

PLATE IV

- Fig. 1. Longitudinal section near the basal layer of epidermis ($\times 100$), from the glove-finger of fin whale, staining by haematoxylin eosin. In this section, the proximal end of ear plug sticks on the glove-finger. There are the blood capillaries in the corium.
EP: ear plug, BL: basal layer of epidermis, C: corium of glove-finger, V: venules.
- Fig. 2. Longitudinal section of germinal layer of epidermis ($\times 400$), from the glove-finger of fin whale, staining by haematoxylin eosin. This photomicrograph indicates the occurrence of flattened nuclei in the proximal part of longitudinal band.
LB: the space corresponding to the longitudinal band, FN: flattened nuclei, BL: basal layer of epidermis of glove-finger.

PLATE V

- Fig. 1. Longitudinal section of the proximal part of ear plug ($\times 20$), from the fin whale, staining by SUDAN III. In this photomicrograph the concentric light band and the longitudinal light band are stained darkly by SUDAN III.
CLB: concentric light band, LLB: longitudinal light band, GL: germinal layer of glove-finger.
- Fig. 2. Longitudinal section of the proximal part of ear plug ($\times 15$), from the blue whale, staining by SUDAN III. This photomicrograph indicates the shape of curved light band resembles to that of papilla.
CLB: curved light band, LLC: longitudinal light band, GL: germinal layer of glove-finger.

PLATE VI

- Fig. 1. Longitudinal section of the extremely proximal end of ear plug ($\times 400$), from the ear plug of fin whale, staining by haematoxylin eosin.
- Fig. 2. Longitudinal section of the germinal layer near the basal layer of glove-finger ($\times 400$), from the glove-finger of fin whale, staining by haematoxylin eosin.

These photomicrographs are obtained from the same specimen. They indicate the various stages in the deformations of epithelial cells and nuclei, corresponding to the distance from the basal layer of epidermis of the glove-finger. The conification of epithelial cell progresses further and it is stained more darkly by eosin in the upper part of Fig. 1 than in Fig. 2.

FC: fusiform cell, DEC: deformed epithelial cell, BL: basal layer of epidermis of glove-finger.

PLATE VII

Fig. 1. Longitudinal section of the proximal end of ear plug ($\times 75$), from the fin whale, staining by SUDAN III. The specimen is forming the concentric dark band which is not stained very by SUDAN III. The fusiform cells appear above the germinal layer of glove-finger.

Fig. 2. Longitudinal section of the proximal part in which the keratinized fusiform cells begin to be formed. ($\times 400$), from the same specimen as indicated in Fig. 1, staining by SUDAN III.

FS: fatty substances occupying the space among the fusiform cells, FC: keratinized fusiform cell, GL: cell of germinal layer under deformation.

PLATE VIII

Fig. 1. Longitudinal section of the proximal end of ear plug ($\times 75$), from the fin whale, staining by SUDAN III. The specimen is forming the concentric light band which is stained well by SUDAN III. The keratinized fusiform cell appear above the part stained darkly.

FC: keratinized fusiform cell, CC: capillary crystal, GL: germinal layer of the epidermis of glove-finger.

Fig. 2. Longitudinal section of the proximal part of ear plug, in which the fatty degeneration in the epithelial cell of glove-finger begin to occur ($\times 400$), from the same specimen as indicated in Fig. 1, staining by SUDAN III. The fatty granules are stained in the cytoplasm of the deformed cell.

PLATE IX

Fig. 1. Longitudinal section of the proximal end of ear plug ($\times 200$), from the fin whale staining by SUDAN III. This photomicrograph indicates that the proximal part of the longitudinal light band forms the structure like the fine roots of the tree. The germinal cells are compressed laterally in the longitudinal light band, which is stained darkly.

LLB: longitudinal light band, GL: cell of germinal layer under deformation, P: the space at which the papilla is situated.

Fig. 2. Longitudinal section of the ear plug and glove-finger ($\times 40$), from the young fin whale, staining by haematoxylin eosin. Nuclei remain at the longitudinal light band in the ear plug.

LLB: longitudinal light band, G: granules stained darkly by haematoxylin, CG: corium of glove-finger.

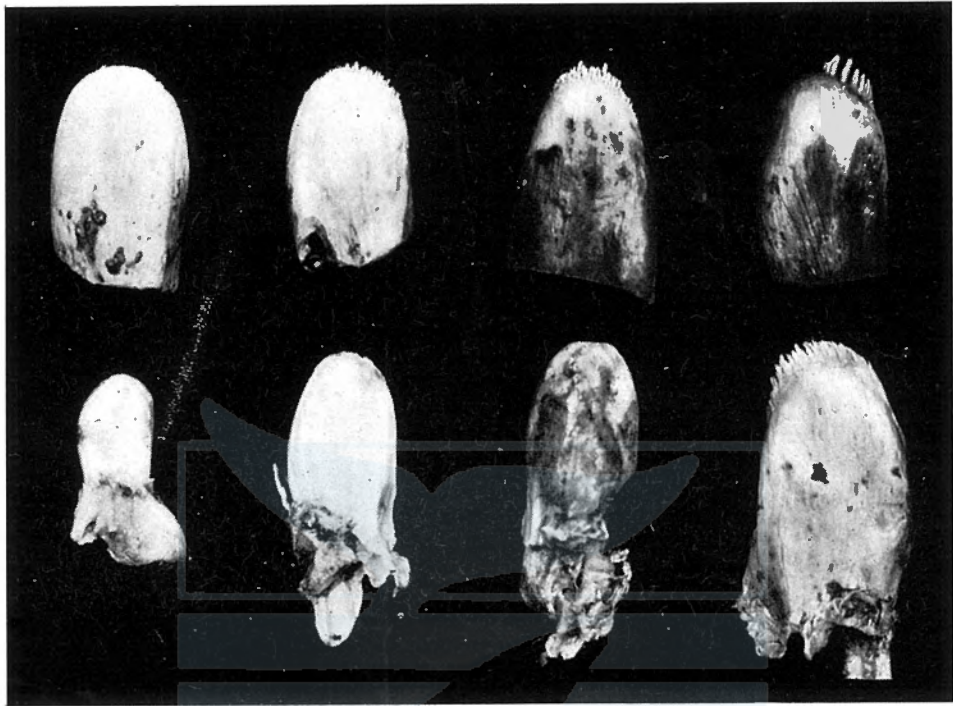


Fig. 1




Fig. 2




Fig. 1

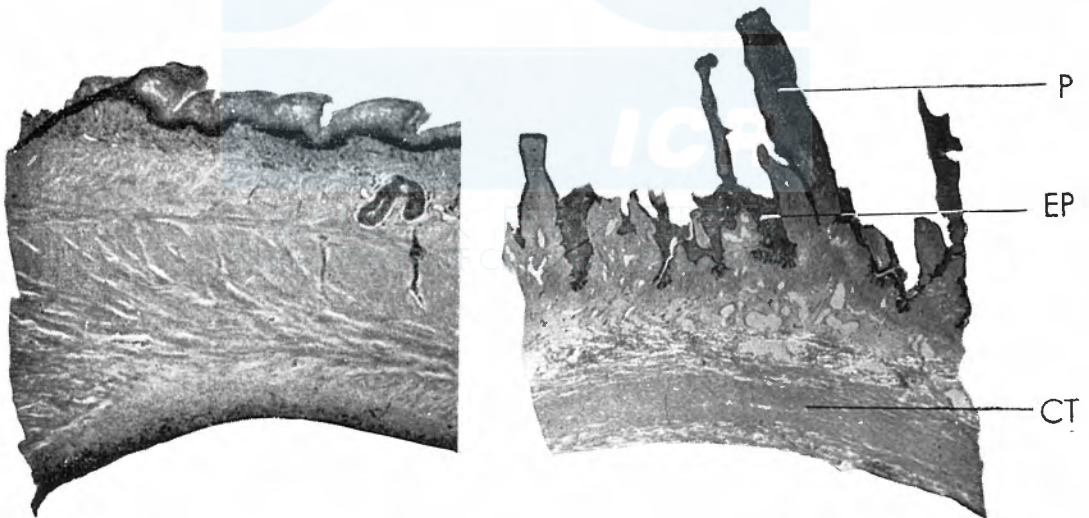


Fig. 2

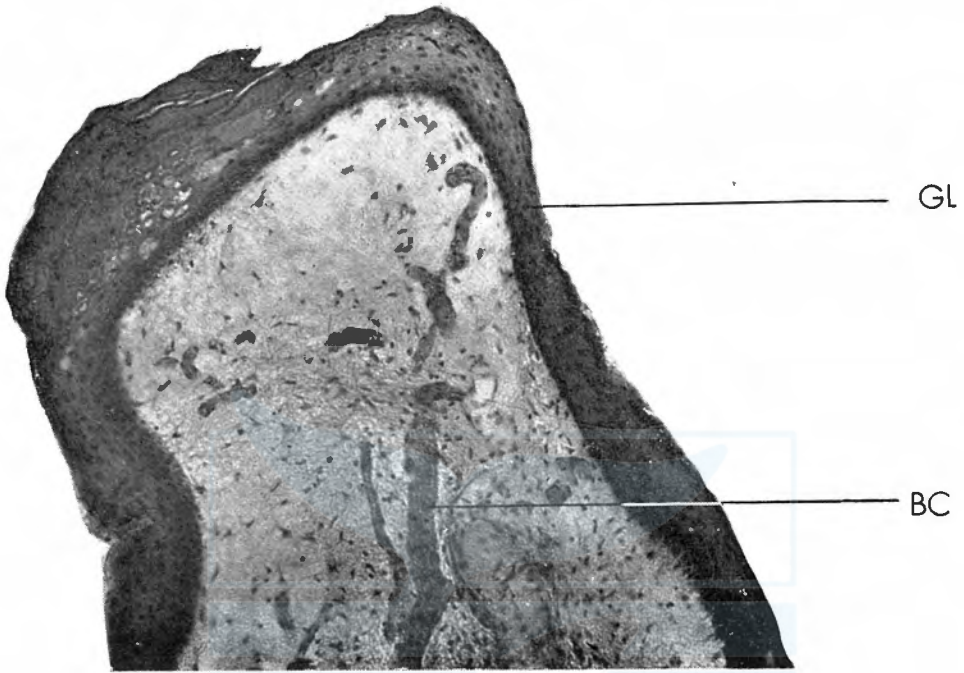


Fig. 1

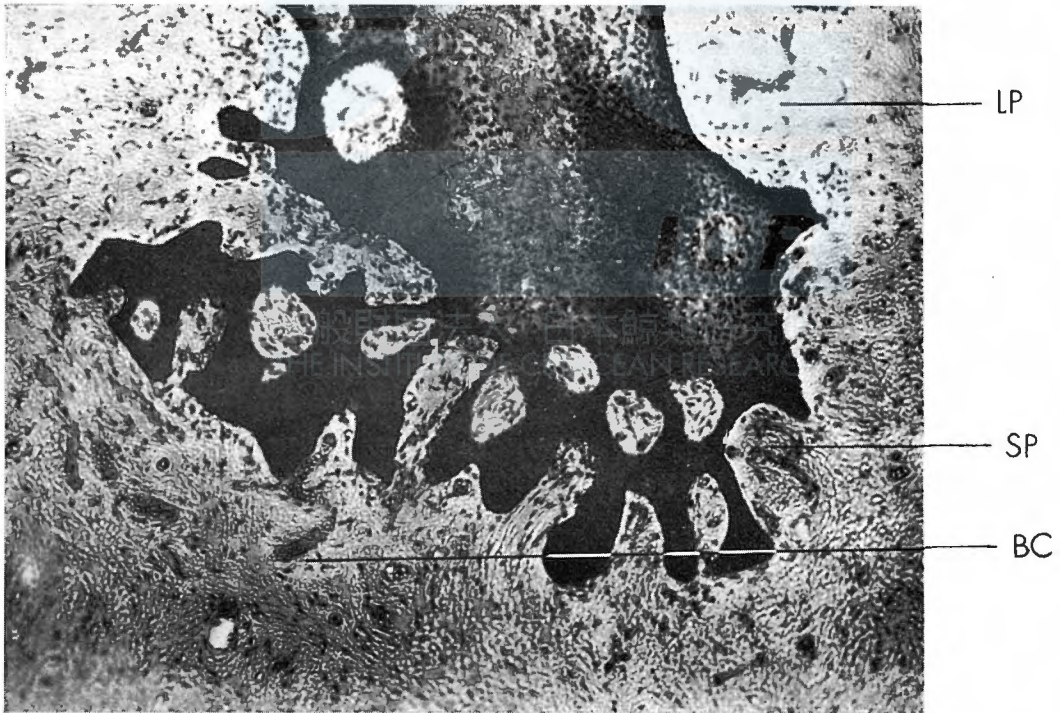


Fig. 2

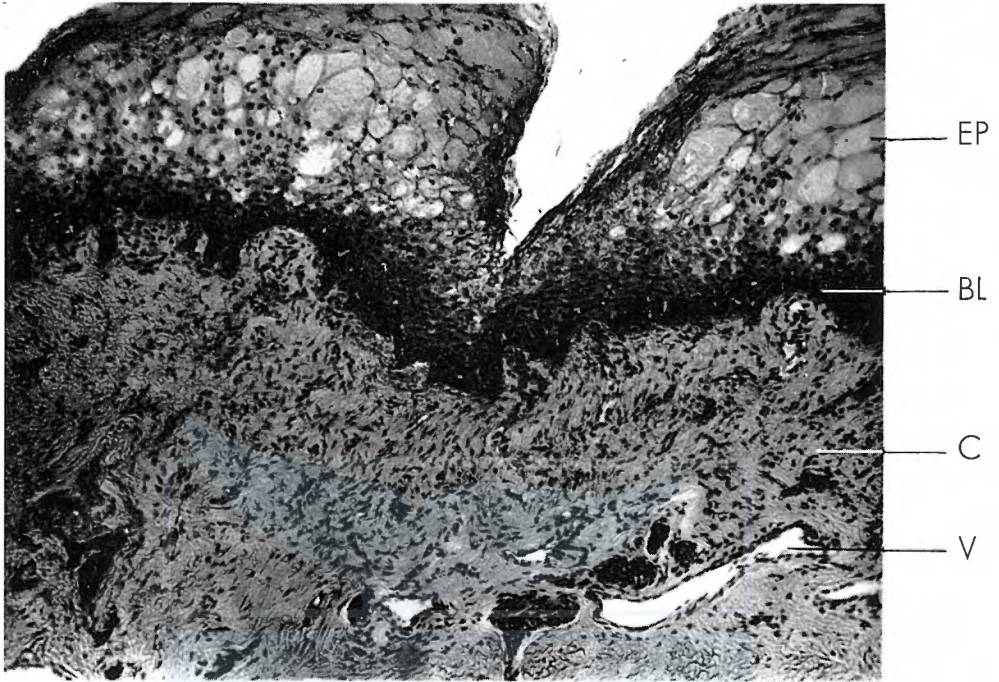

Fig. 1




Fig. 2




Fig. 1

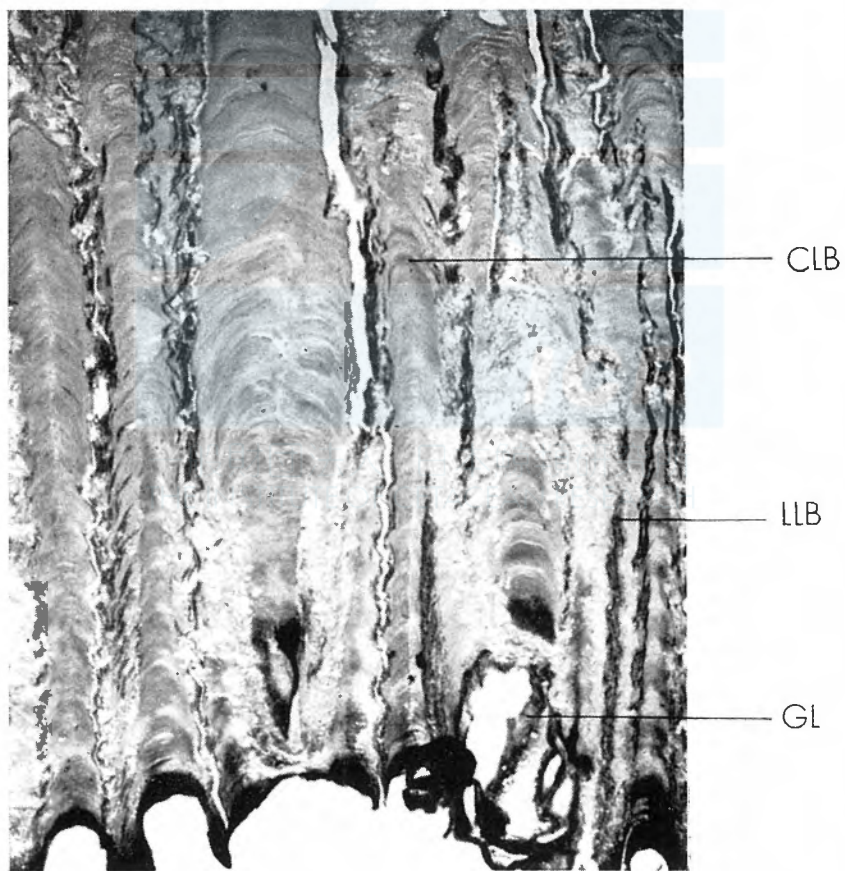


Fig. 2




Fig. 1

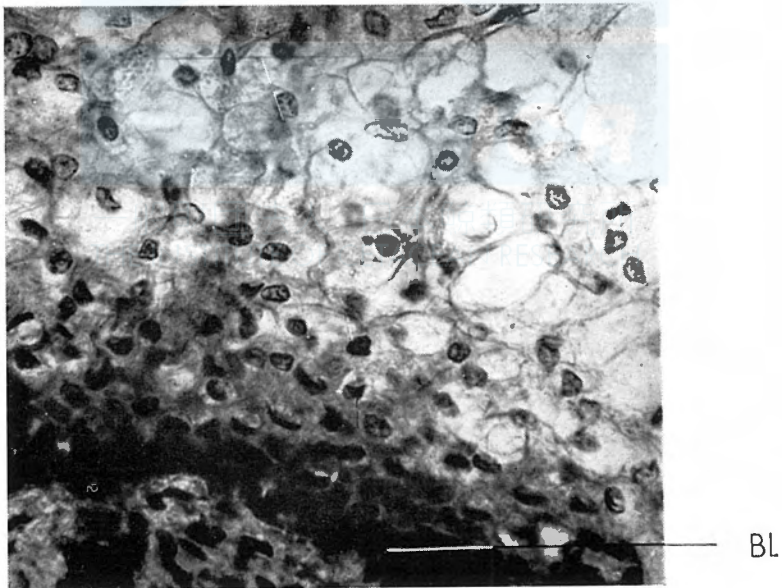


Fig. 2

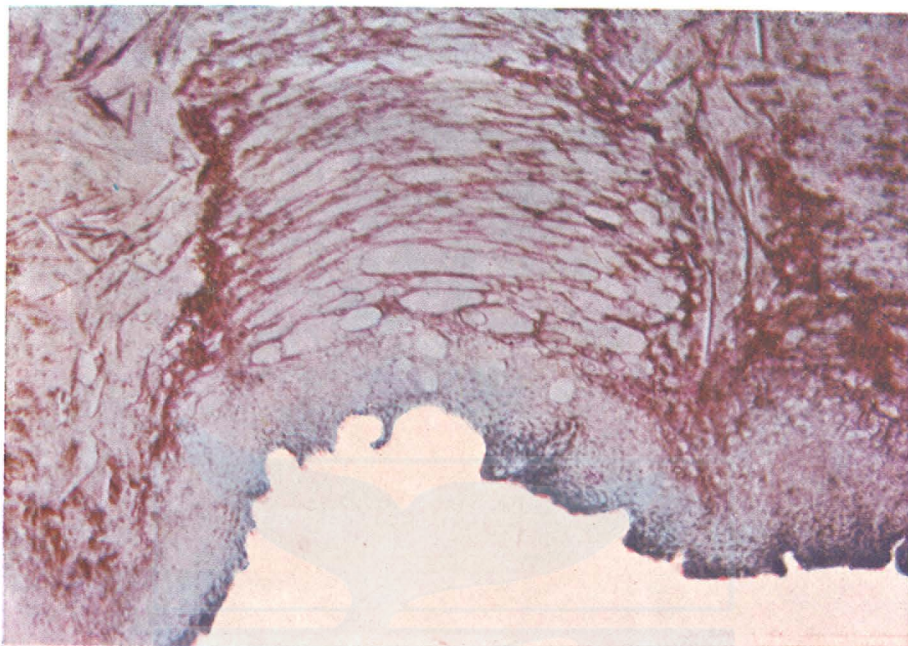


Fig. 1

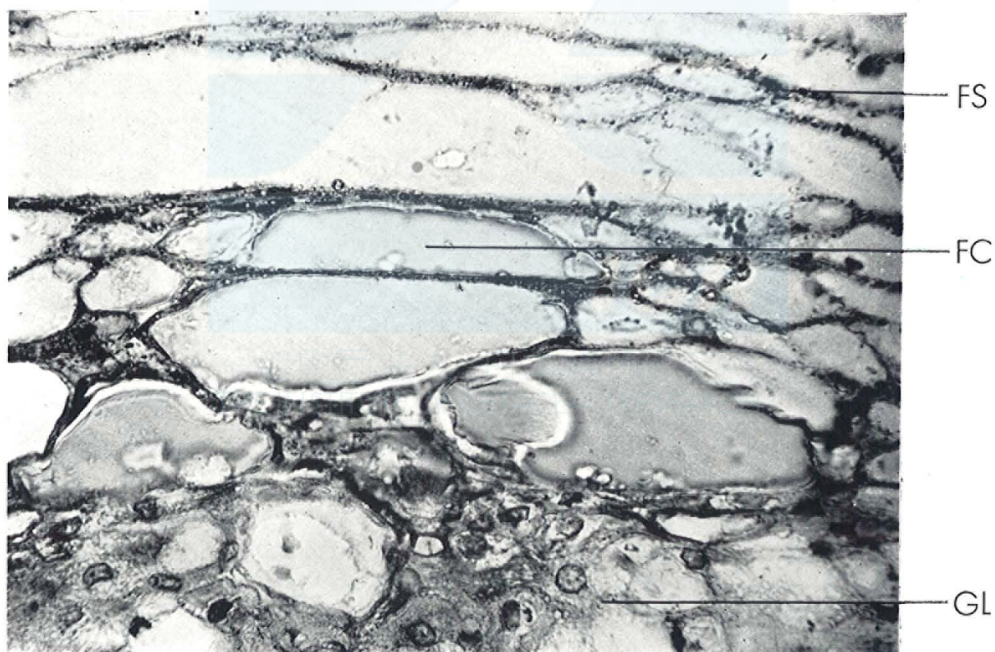


Fig. 2

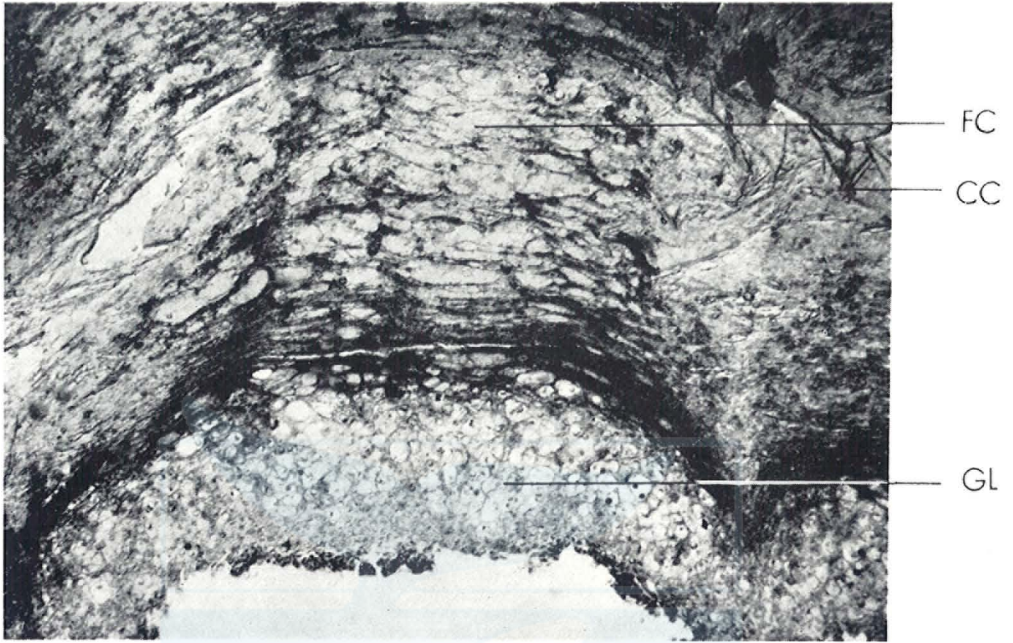


Fig. 1

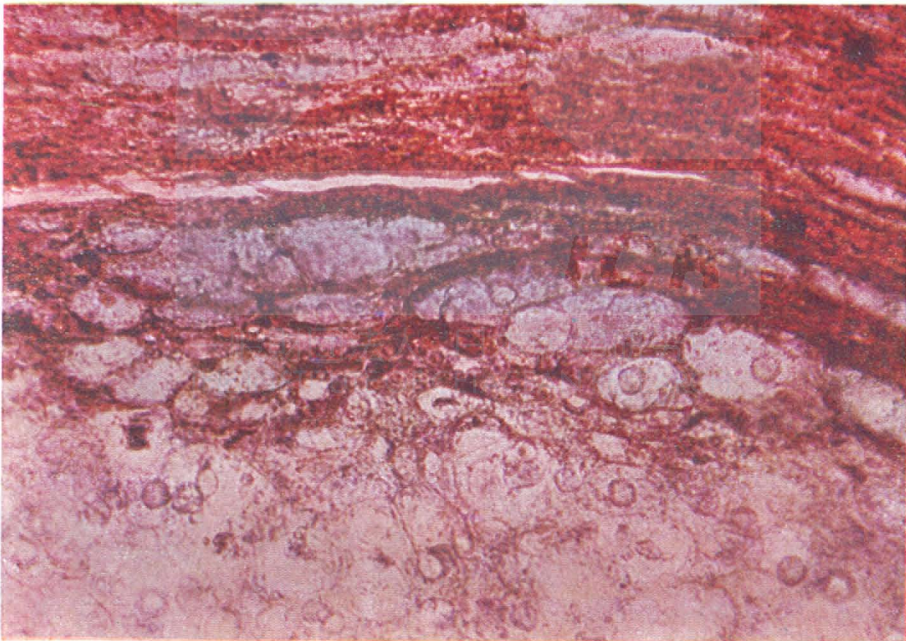


Fig. 2

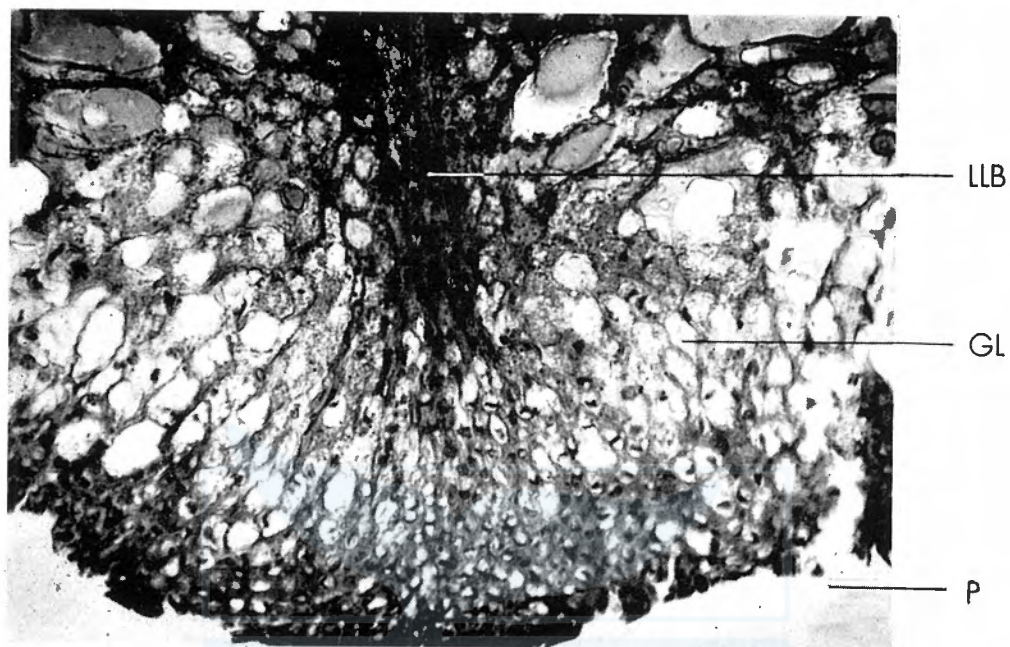


Fig. 1

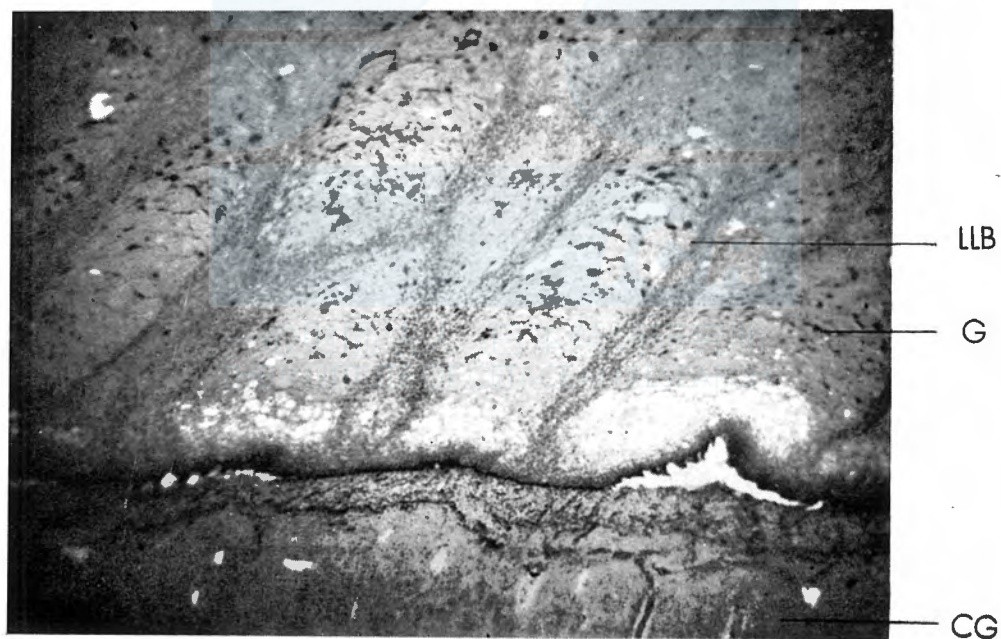


Fig. 2