

On the Pelvic Cartilages of the Balaenoptera-Foetuses, with Remarks on the Specific and Sexual Difference

BY

H. Hosokawa (Anatomical Department, Medical School,
University of Tokyo, Professor Dr. T. Ogawa)

(*Anatomical studies on the whalebone-whale foetuses, No. 1*)

Introduction

It is well known that the whales have no hind-limb protruding on the surface of the body. But probably all of them have the rudimentary pelvis as a pair of slender bones.¹⁾ Unlike in most mammals, whose pelvic girdle consists of three elements (ischium, pubis and ilium) coalescing into a single bone, the cetacean pelvis is made of only one element, a fact stated first by Eschricht and Reinhardt (1866), who found a single center of ossification in it. This bone is believed to represent the ischium, for it is connected with the crura penis or clitoridis, and also with the musculus ischiocavernosus.²⁾³⁾

While in the Odontoceti the pelvis is the sole remnant of the hind-limb, most of the Mysticeti have one or two other pairs of very small bones or cartilages placed near the middle of pelvis. One pair of them is attached to the pelvis by ligaments and accompanies the third pair at its caudal end. They were found at first by Reinhardt (1848) in a newborn Greenland Right-whale and asserted

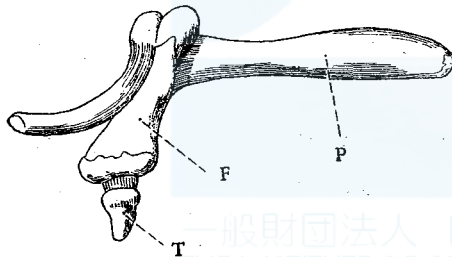


Fig. 1 Side view of bones of posterior extremity of Greenland Right-whale (from Eschricht and Reinhardt)
P.....Pelvis F.....Femur T.....Tibia

then by Eschricht and Reinhardt (1866) in a half-grown and a full-grown whale of the same species (Fig. 1). Later, Struthers (1881) observed eleven pairs of the rudimentary bones, studying minutely the articulations and neighbouring muscles. The supernumerary pelvic bones are nowadays supposed to represent femur and tibia, as suggested by the discoverers of them.

1) In *Cogia* the presence of the pelvis is not yet ascertained. (van Oort: *Zool. Medel. Rijksmuseum Nat. Hist. Leiden*. 9, 1926.)

2) Schneider (1795) took the cetacean pelvis for pubis.

3) The Eschricht and Reinhardt's interpretation of the cetacean pelvis, that its cranial and caudal portions represent respectively pubis and ischium, while the lateral process corresponds to ilium, may be also true, if we take in mind the relations to neighbouring structures.

On the other hand, in the adult Humpback Eschricht found only the second pair, and afterwards Struthers (1888) confirmed also the absence of the third pair in this species. The same result was mentioned by Burmeister (1867) and Struthers (1872, 93) also for the Fin-whale, in which the only existing femur was extremely vestigial. Further, the lesser Fin-whale (*Balaenoptera acuto-rostrata*, Lac.) and the Sei-whale show, according to Struthers etc., no trace of femur and tibia, just like in the Odontoceti (Fig. 2).

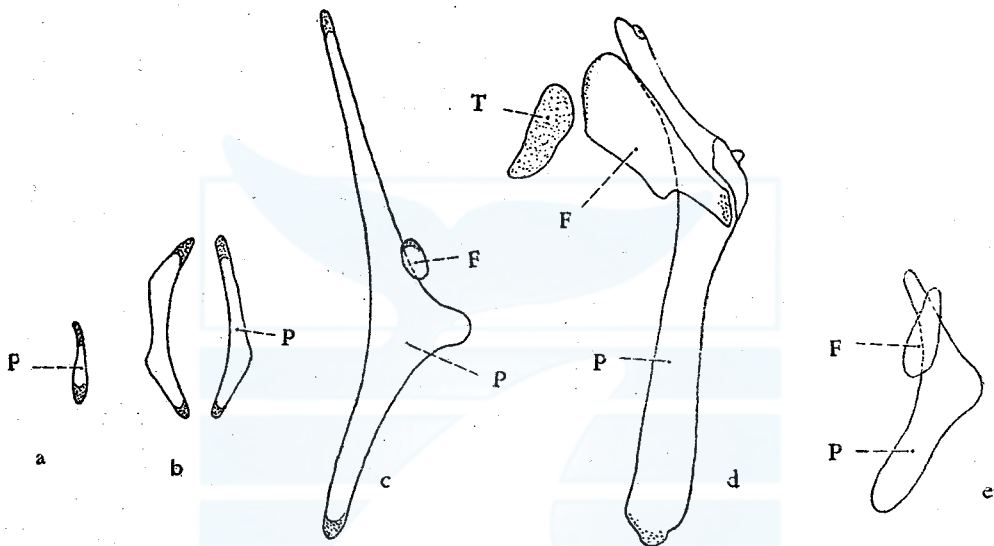


Fig. 2 Cetacean skeletons of hind-limbs (from Struthers)

- a. Lesser Fin-whale (14.5 feet, male) b. Sei-whale (36 feet, male)
 c. Fin-whale (64 feet, male) d. Greenland Right-whale (48 feet, male)
 e. Humpback-whale (40 feet, male)

During my Antarctic whaling voyage on board the Nissin-Marun No. 1 (1947-48), I examined the cartilages in question in the *Balaenoptera*-foetuses and found some noteworthy facts.

The materials examined by me are as follows:

Foetuses of the Blue whale (*Balaenoptera musculus*, L.) 9.

(male, 6; female, 3; max. length, 22 feet 2 inches; min. length, 3 feet 11 inches)

Foetuses of the Fin-whale (*B. physalus*, L.) 9.

(male, 5; female, 4; max. length, 15 feet 1 inch; min. length, 2 feet 1 inch)

Additionally for comparison, each one pair of pelvic bones of adult Blue and Fin-whales.

Pelvic cartilages of the Blue and Fin foetuses

Both species have besides a pair of pelvis another pair of very small cartilages, the third pair being completely absent. The pelvis (Fig. 3, 4) is elongated, somewhat curved, hammerlike in form, and has a very short lateral process, corresponding to "promontory" of Struthers. The upper process, processus cranialis, is pointed at the end and deserves the name "apex cranialis", while the lower one, proc. caudalis, is shorter, with its somewhat rounded extremity. The lateral process, the shortest of all processes, ends also not sharpened, but has here a more or less eminent tubercle, tuberculum laterale.

Near the tubercle, a little more ventrad and craniad, there is a small, oval piece of cartilage, the upper end of which is pointed in some cases, especially

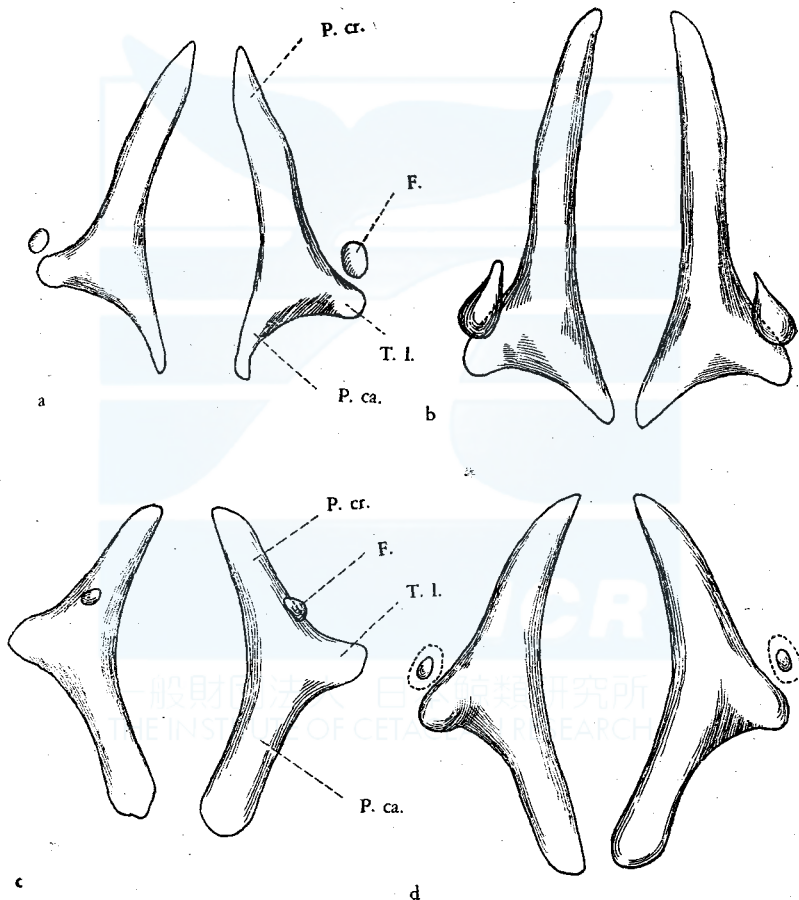


Fig. 3 Pelvic cartilages of the Fin and Blue foetuses

- a. Fin, male (13 feet 6 inches long) b. Fin, female (15 feet 1 inch long)
c. Blue, male (12 feet 3 inches long) d. Blue, female (14 feet 11 inches long)

1) In the adult whales the cranial process is rather flattened mediolaterad, in opposite to the club-like caudal process (Fig. 4).

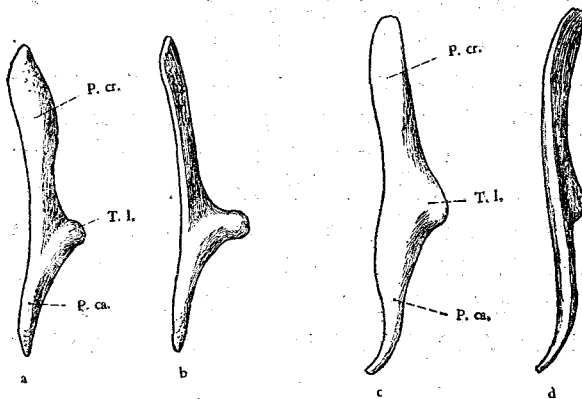


Fig. 4 Pelvic bone of adult whalebone-whales
 a, b, Fin-whale, lateral and ventral view
 c, d, Blue whale, lateral and ventral view
 P. cr., Proc. cranialis; P. ca., Proc. caudalis;
 T. l., Tuberculum laterale

in the Fin-whale. This small cartilage, being nothing but the remnant of femur, is covered with a thick capsule of connective tissue. The remnant of femur does not increase in size proportionately with the growth of the foetus: in other words, much more remarkable individual variation is seen in the size of this cartilage than in that of the pelvis. This difference might be understood by the more vestigial nature of the former. It is moreover likely,

that the femur is more rudimentary in the Blue whale than in the Fin-whale. For, according to my observation, the femur of considerably larger foetuses of Blue whale (12 feet 4 inches, male; 13 feet 4 inches, male; 15 feet 5 inches, female; 22 feet 2 inches, male) is sometimes made solely of connective tissue, containing no cartilage. The ligamentous band between femur and pelvis is very loose, and here I found no articular formation, though Eschricht, Reinhardt and Struthers mentioned an articulation respectively in an adult Greenland Right-whale and in an adult Fin-whale.

Ossification of the pelvic cartilages

Neither pelvis nor femur of all the foetuses, measuring from 2 feet 11 inches up to 22 feet 2 inches in length, showed any trace of ossification. It is therefore supposed that these skeletons are ossified only after the parturition. For, consulting the statistics published by Mackintosh, Wheeler (1927) and Matthews (1937), it seems certain that the foetus of 22 feet is only a little before the birth. Reinhardt found in a newborn Greenland Right-whale an ossified portion of the femur in its middle part, but no ossification in pelvis and tibia.

Position and locality of the pelvic cartilages

The cartilaginous pelvis exists on each side, rather laterad and caudad, to the external genital orifice, with its axis nearly parallel to that of the whale-body. We can palpate them after removal of the skin as somewhat hard objects. All of my specimens were not so small as to settle the problem upon the presence of an external protrusion representing the hind-limb reported by Guldberg (1894, 99) and Kükenthal (1895) in *Phocaena communis* (Fig. 5). I have known, however,

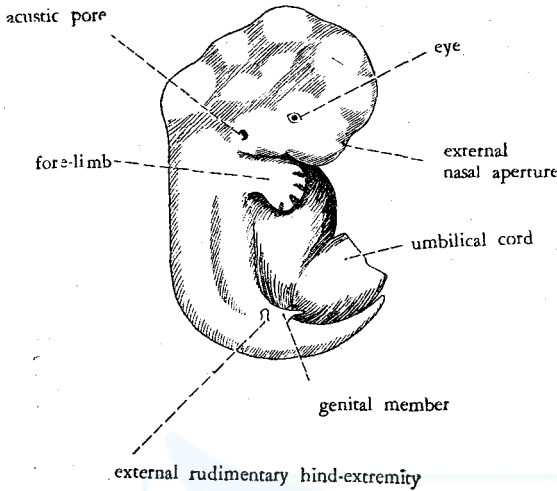


Fig. 5 The 17 mm. long *Phocaena*-embryo seen from the right side. (Guldberg)

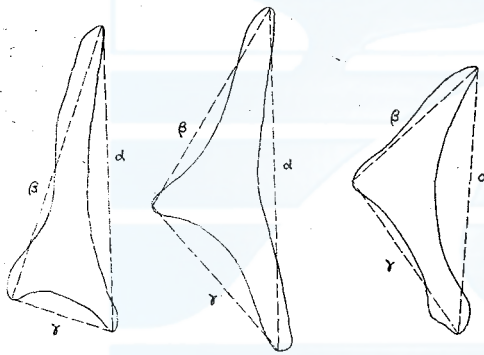


Fig. 6. Measurements of the pelvic cartilage

that the pelvis is located in small foetuses under the skin more superficially, while those in larger ones lie more deeply embedded in the muscular layer and so more hardly palpable.

Difference of the foetal pelvis in form between Fin- and Blue whale

In the Fin foetus the caudal process of the cartilaginous pelvis is relatively shorter than in the Blue, viz. the pelvis of the former has the lateral process placed more caudad than that of the latter (Fig. 3). My measurements of the distances 1) from the cranial apex to the caudal end (α), 2) from the cranial apex to the lateral tubercle (β), 3) from the caudal end to the lateral tubercle (γ), and the relative length of β and γ (β/γ) (Fig. 6) are shown in Table 1.

While the average of this index β/γ is in the foetal Fin-whale 2.01 (max., 2.67; min., 1.63), it is in the foetal Blue whale only 1.06 (max., 1.25; min., 0.71); there is accordingly a distinct difference between the both species. Fig. 7 indicates my data diagrammatically. From this figure we know that the index β/γ is in the Fin foetuses, without exception, more than 1.5, while in the Blue foetuses it lies always under 1.5. It is interesting that these intimately related two species of Balaenopterides show such a remarkable difference in the form of pelvis. I can't decide, however, whether the same difference is present also in the adult whales, but the postnatal existence of approximately the same relation is unpalisable.¹⁾

1) Struthers (1893) stated that the characteristics in the form of pelvic bones of some adult whales (Megaptera, Right-whale) are to be seen also in the immature, younger whales.

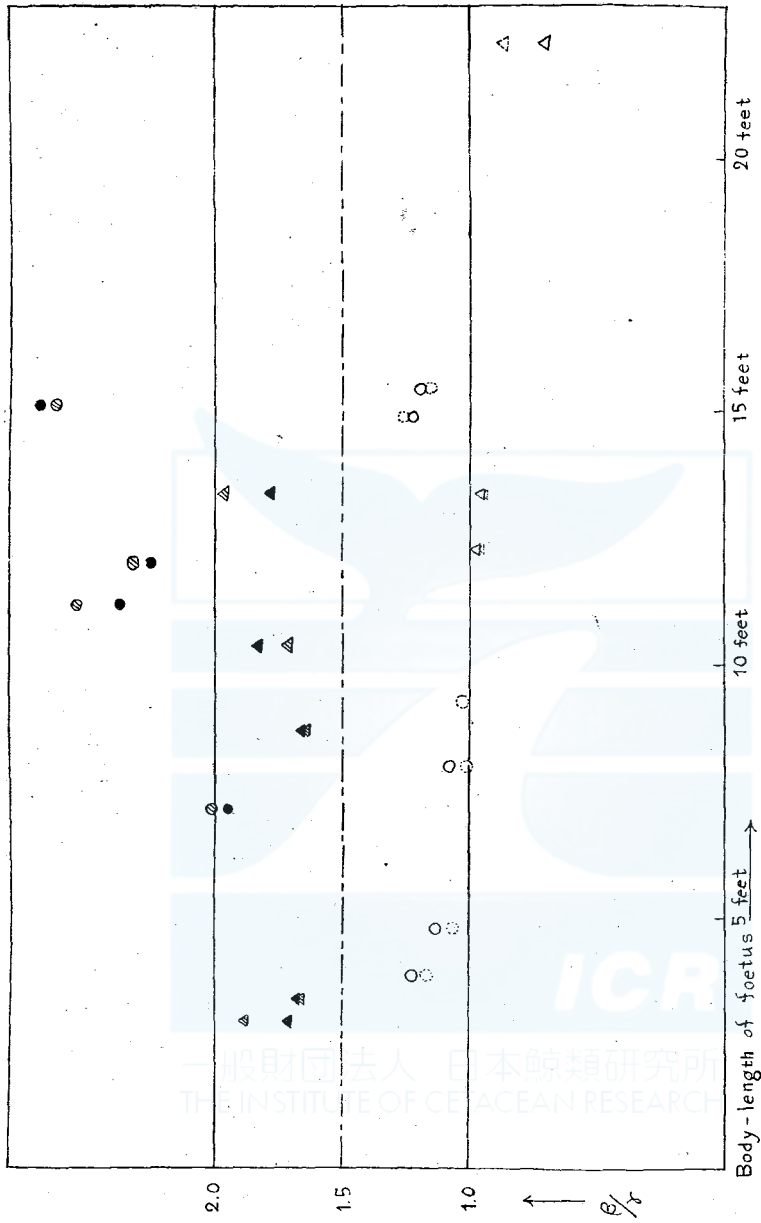


Fig. 7. β/r index of the cartilaginous pelvis of Blue and Fin-whale foetus.

Fin-whale; male (▲, right; ▲, left), female (●, right; ●, left)

Blue whale; male (△, right; △, left), female (○, right; ○, left)

According to Eschricht, Reinhardt and Struthers, the posterior part of the pelvic bone exceeds considerably in length the anterior part in the Greenland Right-whale. Hence the ratio in question seems to be in this whale by far less than 1.0. After Struthers' measurement of eleven specimens, this ratio seems to

fall between 0.3 and 0.7 (average, 0.41) for the Greenland Right-whale. And I calculated, using Struthers' data, that this ratio is for a male Megaptera of 40 feet long 0.77, i.e. an intermediate value between the Greenland Right-whale and the Blue foetus. In this way we can probably determine the kind of whale-bone-whales from the form and size of pelvis, especially by consulting the relative length of the upper and lower processes.

Sexual difference of the cartilaginous pelvis

In both the Fin and Blue foetuses the β/γ index of the pelvis is larger in the female than in the male (Fig. 7). As to the Fin-whale, this index is in the female almost always more than 2.0 (average, 2.34; max., 2.67; min., 1.95), while in the male it is, without exception, less than 2.0 (average, 1.75; max., 1.97; min., 1.63). In the Blue whale, the critical point of the ratio for the sexual difference is 1.0 (average for the male, 0.91; max., 0.98; min., 0.71; average for female, 1.14; max., 1.25; min., 1.00). Further investigation of the pelvic bones in the adult Fin- and Blue whales is from this viewpoint very desirable.¹⁾

Angle between the cranial and caudal process of the pelvis

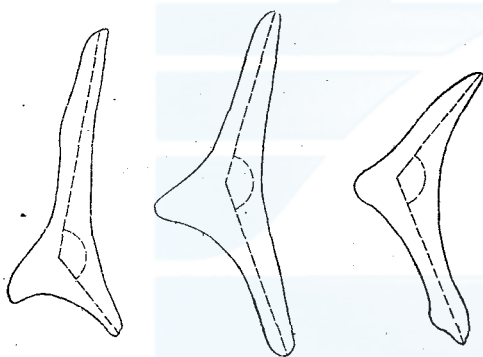


Fig. 8. Angle of the pelvic cartilage

These processes make each other at the level of the lateral process an obtuse angle opened mediad (Fig. 8). This angle, measured with goniometer, shows no remarkable specific or sexual difference (Table 1), the average being in the Fin and Blue foetuses respectively 136° (male, 136°; female, 137°) and 133° (male, 124°; female, 137°); the individual variation is in the Fin-whale 127°-148°,

and in the Blue whale 120°-149°. Neither exists any remarkable difference between the right and left pelvis (average for the Fin-male: right, 136°, left 136°; female: right, 138°, left, 136°; average for the Blue- male: right, 123°, left, 125°; female: right, 140°, left, 138°), though some instances showed the angle tolerably asymmetrical.

1) From Struthers' data no distinct sexual difference seems to exist in the relative length between anterior and posterior parts in the Greenland Right-whale, because this ratio becomes probably 0.30 (♀) and 0.45 (♂). In his opinion, however, it is easier to tell the sexual difference of the pelvic bone in Mysticetus than in human beings, for the hinder end of this bone is much thickened in the male, while it is flattened, usually with expansion, in the female.

N.B. According to Struthers, this angle appears to be in the female Greenland Right-whale somewhat larger than in the male, the average being respectively 139° and 124° .

Development of the pelvis in length

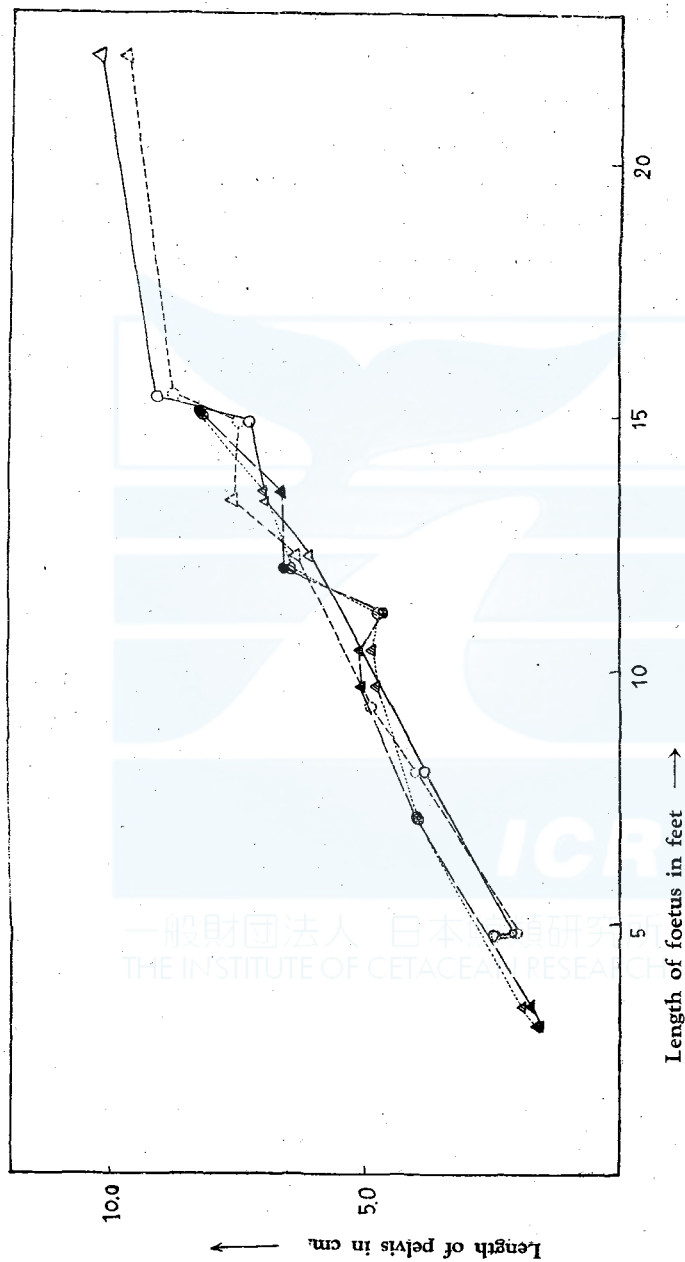


Fig. 9. Diagram showing the development in length of the pelvic cartilage of Blue and

Fin-whale foetus.

Fin-whale ; male (\blacktriangle , right; \triangle , left), female (\bullet , right; \odot , left)

Blue whale; male (\blacktriangle , right; \triangle , left), female (\circ , right; \circ , left)

The length of the cartilaginous pelvis in various intrauterine stages is shown in Fig. 9. By the length of the pelvis I mean the distance from the cranial apex to the caudal end (α in Table 1), and by the body length the distance from the rostral extremity to the median notch of the caudal flipper. We see from this figure that the relative length of pelvis to the whole body remains, regardless of size, sex and species of the foetuses, almost constant.¹⁾²⁾ The cartilaginous pelvis occupies about 1.6-1.8% of the total length of the body (average, Fin-whale-male, 1.8, female, 1.7; Blue whale-male, 1.6, female, 1.7, max., 1.9. min., 1.4)(Table 1).

Nearly the same ratio seems to hold good in the adult stage, for from Struthers' data, this ratio becomes 1.7 in an adult male Fin-whale of 50 feet, 1.6 in an adult male Sei-whale of 36 feet, 1.9 both in an adult male lesser Fin-whale of 14.5 feet and in an adult male Megaptera of 40 feet. But in the Greenland Right-whale the pelvis seems to be relatively larger, occupying 2.3% (max., 3.0, min., 2.0) of the total length of the body.

Summary

1) From the viewpoint of the rudimentary skeletons pertaining to the hind-limb, the whalebone-whales can be classified into the following three groups: Group 1, to which the Greenland Right-whale belongs, has besides the pelvis two pairs of subsidiary bones or cartilages (femur and tibia). Group 2, in which other than the pelvis only the femur is present, comprises the Humpback, the Fin-whale and perhaps also the Blue whale. Group 3, which has neither femur nor tibia but has the pelvis only, seems to comprise the Sei-whale and the lesser Fin-whale.

2) Many foetuses of Fin- and Blue whales studied in this paper have two pairs of cartilages corresponding to pelvis and femur, which show no trace of the bony nucleus within them. Very likely, therefore, the ossification of them takes place only after the parturition.

3) The pelvis of whales, though generally it is hammerlike in form, shows remarkably different shapes according to the species. Especially the ratio of length between the anterior and posterior portions of the pelvis is characteristic to each species.

4) In the Fin and Blue foetuses the sexual difference is marked in the form of the pelvis. The ratio mentioned in the preceding paragraph is always greater in the female than in the male; namely, the female pelvis has relatively longer cranial process than the male.

1) Flower (1876) stated that the pelvic bone of whales is usually more largely developed in the male than in the female.

2) I never found such an asymmetrical development of pelvis as observed by Struthers (1893) in an adult Sei-whale.

Table 1.
Measurements of hind-limb cartilages of Blue and Fin-whale foetuses

Foetus (species, length, sex)	right or left	α (length of pelvis in cm)	β (length of anterior portion)	r (length of posterior portion)	δ (length of femur in cm)	$\alpha \times 100$ body- length	β/r	weight of pelvis in gr.	weight of femur in gr.	ossi- fication	angle between cranial and cau- dal pro- cesses
No.83, Fin	r	1.63	1.45	0.85	0.2	1.8	1.71	0.05	<0.01	(-)	127
2f. 11i., ♂	l	1.65	1.5	0.8	0.2	1.9	1.88	0.05	<0.01	(-)	132
No.80, Fin	r	1.8	1.6	0.95	0.6	1.8	1.68	0.08	0.01	(-)	134
3f. 4i., ♂	l	1.9	1.5	0.9	0.6	1.9	1.67	0.07	0.01	(-)	148
No. 95, Blue	r	2.1	1.45	1.2	—	1.8	1.21	0.08	—	(-)	144
3f. 10i., ♀	l	2.0	1.3	1.1	—	1.7	1.18	0.08	—	(-)	149
No. 101, Blue	r	2.6	1.8	1.7	—	1.8	1.13	0.17	—	(-)	138
4f. 9i., ♀	l	2.6	1.8	1.9	—	1.8	1.06	0.18	—	(-)	135
No. 91, Fin	r	4.0	3.7	1.9	0.4	1.9	1.95	0.65	0.008	(-)	139
7f. li., ♀	l	4.0	3.7	1.85	0.3	1.9	2.00	0.73	0.008	(-)	134
No. 151, Blue	r	3.95	2.9	2.7	0.65	1.6	1.08	0.98	0.10	(-)	139
8f., ♀	l	4.0	2.8	2.8	0.7	1.6	1.00	0.90	0.11	(-)	139
No. 81, Fin	r	5.1	4.05	2.45	1.1	1.9	1.65	1.31	0.11	(-)	142
8f. 8i., ♂	l	4.8	3.9	2.4	1.0	1.8	1.63	1.26	0.09	(-)	137
No. 137, Blue	r	—	—	—	—	—	—	—	—	—	—
9f. 3i., ♀	l	4.95	3.05	3.0	—	1.8	1.02	1.10	—	(-)	—
No. 143, Fin	r	5.1	4.2	2.3	0.3	1.6	1.83	1.03	0.01	(-)	139
10f. 4i., ♂	l	4.9	4.2	2.45	0.35	1.6	1.71	0.97	0.006	(-)	121
No. 132, Fin	r	4.7	4.5	1.9	0.35	1.4	2.37	1.29	0.007	(-)	139
11f. 2i., ♀	l	4.8	4.8	1.9	0.35	1.4	2.53	1.47	0.007	(-)	135
No. 146, Fin	r	6.6	3.15	2.75	0.6	1.9	2.24	3.54	0.04	(-)	—
12f., ♀	l	6.5	6.15	2.65	0.6	1.8	2.32	3.17	0.04	(-)	—
No. 97, Blue	r	6.1	4.1	4.2	0	1.6	0.98	2.9	0.06	(-)	120
12f. 3i., ♂	l	6.4	4.3	4.4	0	1.7	0.98	3.3	0.04	(-)	127
No. 98, Blue	r	7.0	4.8	5.0	0.6	1.7	0.96	4.3	0.01	(-)	121
13f. 4i., ♂	l	7.6	4.8	5.0	0	1.9	0.96	4.7	—	(-)	125
No. 142, Fin	r	6.65	5.7	3.2	0.65	1.6	1.78	3.58	0.07	(-)	139
13f. 6i., ♂	l	7.0	5.9	3.0	0.85	1.7	1.97	3.89	0.15	(-)	143
No. 153, Blue	r	7.4	5.4	4.4	0.5	1.6	1.23	4.81	0.06	(-)	132
14f. 11i., ♀	l	7.5	5.5	4.4	0.5	1.6	1.25	4.81	—	(-)	130
No. 149, Fin	r	8.3	7.75	2.9	1.8	1.8	2.67	6.25	0.42	(-)	136
15f. li., ♀	l	8.3	7.7	2.95	1.7	1.8	2.61	6.8	0.37	(-)	139
No. 150, Blue	r	9.1	6.2	5.2	0	1.9	1.19	7.1	—	(-)	148
15f. 5i., ♀	l	8.8	6.1	5.2	0	1.9	1.17	6.02	—	(-)	136
No. 155, Blue	r	10.3	5.6	7.85	0	1.4	0.71	15.02	—	(-)	129
22f. 2i., ♂	l	9.75	6.2	7.1	0	1.5	0.87	14.61	—	(-)	123

5) The obtuse angle between the cranial and caudal portions of pelvis is in the average 136° and 133° respectively for the Fin and the Blue foetuses. It shows no remarkable variation as to species, sex, age and body-side of whales.

6) The length of pelvis is in the Fin and the Blue foetuses about 1.6-1.8% of the body length. This ratio seems to be nearly constant for almost all whale-bone whales, regardless of species, sex and age, probably with the exception of Greenland Right-whale, which shows a ratio of far greater than 2.0%.

Literature

- 1) Schneider, J. G.; Beiträge zur Naturgeschichte der Walfischarten. Leipzig. 1795.
- 2) Eschricht, D. F. and Reinhardt, J.; On the Greenland Right-Whale (*Balaena mysticetus*, L.). Ray Society, 1866. Recent Memoirs on the Cetacea. London 1866.
- 3) Burmeister, H.; Preliminary descriptions of a new species of Finner whale (*Balaenoptera bonaerensis*). Proc. Zool. Soc. London. 1867. pp. 707-713.
- 4) Flower, W. H.; An introduction to the osteology of the mammals. London. 1870. Second edition. 1876.
- 5) Struthers, J.; On some points in the anatomy of a great Fin-whale (*Balaenoptera musculus*). Journ. Anat. Physiol. 6. pp. 107-125. 1872 (1871).
- 6) Struthers, J.; On the bones, articulations, and muscles of the rudimentary hind-limb of the Greenland Right-whale (*Balaena mysticetus*). Ibid. 15. pp. 141-176, 301-321. 1881.
- 7) Struthers, J.; On some points in the anatomy of a Megaptera longimana. Part 2. The limbs. Ibid. 22. pp. 240-282. 1888.
- 8) Struthers, J.; On the rudimentary hind-limb of a great Fin-whale (*Balaenoptera musculus*). Ibid. 24. pp. 291-335. 1893.
- 9) Kükenthal, W.; Ueber Rudimente von Hinterflossen bei Embryonen von Walen. Anat. Anz. 10. pp. 534-537. 1895.
- 10) Guldberg, G.; Ueber temporäre äussere Hinterflossen bei Delphinembryonen. Verh. anat. Gesellsch. 8. pp. 92-95. 1894.
- 11) Guldberg, G.; Neue Untersuchungen über die Rudimente von Hinterflossen und die Milchdrüsenanlagen bei jungen Delphinembryonen. Internat. Monatschr. f. Anat. Physiol. 16. pp. 301-321. 1899.